



AÇBİD-BAOMS JOINT CONGRESS

in conjunction with



4th Conference of BAMFS
(Balkan Association of Maxillofacial Surgeons)

5-8 November 2014
Harbiye Military Museum & Cultural Center
İstanbul / Turkey

Oral and Maxillofacial Surgery Society, Turkey (AÇBİD)
British Association of Oral and Maxillofacial Surgeons (BAOMS)

www.acbid-baoms2014.org

Professional Congress Services

interium

Professional Congress Services • Destination & Event Management
Corporate Meetings & Incentives • PR & Communication Consultancy

+90 212 292 8808 • +90 212 292 8807
info@interium.com.tr • www.interium.com.tr



EACMFS Accredited



Scan this QR
Code with your
smart phone to
download the web site.

CONTENTS

Welcome Message

Scientific Program

Invited Speaker's Abstracts

Oral Presentations

Poster Presentations



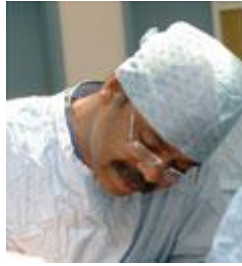with the contributions of "The Scientific and Technological Research Council of Turkey"

This is the first time a joint conference has been held by the British Association of Oral & Maxillofacial Surgeons (BAOMS) and the Oral and Maxillofacial Surgical Society of Turkey. The ACBİD is also closely associated with the Balkan countries. The world of Maxillofacial Surgery is changing year by year with the scope, training and practice. This conference will reflect the change and we are planning the progress for the next five years.

Leading Speakers from around the world will take part in this joint event. We intend to make this a memorable event with a typical Turkish hospitality. We are looking forward to seeing you all in İstanbul in November 2014 to experience the fun, to gain exposure in the latest innovations in maxillofacial surgery and to form a lifelong friendship.



Prof. Dr. Nedim Özer
*President, Oral and Maxillofacial
Surgery Society, Turkey*



Prof. Dr. Velupilla Ilankovan
*President, British Association of Oral
and Maxillofacial Surgeons*



Prof. Dr. Reha Kısıncı
*President, Balkan Association of
Maxillofacial Surgeons*

Congress General Secretary Prof. Hakan H. Tüz



4th Conference of BAMFS (Balkan Association of Maxillofacial Surgeons)

5-8 November 2014 - Harbiye Military Museum & Cultural Center - İstanbul / Turkey

SCIENTIFIC PROGRAM

5-8 November 2014 - Harbiye Military Museum & Cultural Center - İstanbul / Turkey

Wednesday, 5th November

09:00-17:00	PRE-CONFERENCE COURSE Chairpersons: Bob Woodward, Nabil Samman, Umut Tekin
09:00-17:00	Virtual Treatment Planning for Orthognathic Surgery: Tips for Successful Surgical-Orthodontic Outcomes - Planning - Bryan Bell (USA)

Thursday, 6th November

08:00-18:00	REGISTRATION	
08:00-17:00	POSTER PRESENTATIONS	
08:00-17:00	EXHIBITION	
09:00-10:00	MINI COURSE Chairpersons: Ian Ormiston, Vedran Uglesic, Sina Uçkan	
09:00-10:00	The Medical Management of Central Giant Cell Granulomas - M. Anthony Pogrel (USA)	
10:00-12:00	MAJOR SYMPOSIUM 1 Chairpersons: Daniel Hrusak, Graham Smith, Timuçin Baykul	
10:00-10:30	Adipose Stem Cells for Cranio-maxillofacial Reconstruction: Present Art and Future Direction George Sandor (Finland)	
10:30-11:00	Access in Head & Neck Surgery, the Role of Transoral Robotic Surgery and Cost Effectiveness – Bryan Bell (USA)	
11:00-11:30	Inferior Alveolar Nerve Damage from Dental Implants – M. Anthony Pogrel (USA)	
11:30-12:00	Experience with Alloplastic TMJ Prosthesis and the Future – Bernard Speculand (UK)	
12:00-13:30	LUNCH	
12:15-13:15	LUNCH AND LEARN SESSION ROOM A Chairpersons: Mark Devlin, Jan Stanek	ROOM B Chairpersons: Gühan Dergin, Metin Şençimen
12:15-13:15	Non-Surgical Facial Rejuvenation – Rajiv Anand (UK) - Sanjay Sharma (UK)	Reconstructive Options for the TMJ – Andrew Sidebottom (UK)
13:30-14:30	SYMPOSIUM 1 Chairpersons: Bryan Bell, Mark McGurk, Gülsüm Ak	SYMPOSIUM 2 Chairpersons: Anthony Pogrel, Rajiv Anand, Meltem Koray
13:30-13:50	The modern Management of Oro Pharyngeal Cancer – Graham Smith (UK)	Temporomandibular Custom Hemi-joint Concept: a Paradigm Shift for TMJ – Umut TEKİN (Turkey)
13:50-14:10	Electro Chemo Therapy in Advanced Cancers – James McCaul (UK)	Minor Salivary Gland Tumors: From Diagnosis to Treatment – Nick Papadogeorgakis (Greece)

5-8 November 2014 - Harbiye Military Museum & Cultural Center - İstanbul / Turkey

14:10-14:30	Principles of Local Flaps for Facial Reconstruction – Vedran Uglesic (Croatia)	Strategic - Bicortical Implantology – Vitomir Konstantinovic (Serbia)
14:30-15:00	COFFEE BREAK	
15:00-16:00	ORAL ABSTRACT SESSION 1 HALL A Chairpersons: Kishore Shekar, Mehtap Muğlalı PATHOLOGY & CANCER	HALL B Chairpersons: Mark Singh, Sertan Ergun PATHOLOGY& IMPLANT & TISSUE ENGINEERING
	Efficacy of Tumour Depth of Invasion as a Predictor of Pathological Detected Neck Metastases in pT1 Squamous Cell Carcinoma of the Tongue Dr. Ramanan Rajamanohara	Marsupialization of the Jaw Cysts in Children: Case Series Dr. Emrah Dilaver
	Globe Preservation in Maxillary Tumours Dr. Anna Sayan	Comparative Analysis of 3-years Results of a Pterygoid Approach: Isoelastic PEEK-PERSO-C Implants and Titanium screw Implants to Avoid More Invasive Implant Procedures in the Atrophic Maxilla Dr. Alexander Bagdasarov
	Oral Lichen Planus- Retrospective Study of 248 patients Dr. Esin Demir	Buccal Bone Remodeling after Immediate Implant Placement with and without Grafting Dr. Shereen Wagdy Arafat
	Retrospective Audit of Compliance with Local Guidelines Relating to Pre-radiotherapy Haemoglobin Levels in Post-operative Head and Neck Oncology Patients at St George's Hospital London. Are we Compliant with the Current Literature? Dr. Martin Woods	New Generation Platelet Concentration (A-PRF) Effects On Bone Formation In Standard Bone Defects: Animal Study Dr. Kübra Titirli
	Tongue Ulcer Resembling Malignant Cancer in a Thalassaemic Patient Dr. Natasha Talai	Review about Tissue Engineering in Oral Surgery Dr. Ali Hanttash Abu Hanttash
	Myxofibroma of The Jaws: Treatment Modalities and Review of the Literature Dr. Tuğçe Biçer Ayтуğar	Alveolar Ridge Preservation with Free Gingival Graft in the Anterior Maxilla: A Cone-Beam Computed Tomography Study in Humans Dr. Çiğdem Karaca
	Composite Free Flap Reconstruction Following Stage 4 Mandibular Osteoradionecrosis Dr. Michail Tsakalidis	Clinician and Patient Perceptions of the Risks Of Waterpipe Smoking Dr. Yusuf Gadiwalla
	The Outcomes of CO2 Laser Treatment on Actinic and Seborrhic Keratosis Lesions: 5 Year Retrospective Audit (2009-2014) Dr. Preeyan Shah	
16:00-16:30	COFFEE BREAK	

5-8 November 2014 - Harbiye Military Museum & Cultural Center - İstanbul / Turkey

16:30-17:30	ACBİD – BAOMS JOINT ORATION Chairpersons: Reha Kısıncı, Velupilla Ilankovan, Nedim Özer
16:30-17:30	Cosmetic Facial Surgery: The Role of the Oral and Maxillofacial Surgeon Ghali Ghali (USA)
17:30-18:00	OPENING REMARKS & AWARDS CEREMONY
18:00	JOINT PRESIDENTIAL RECEPTION

Friday, 7th November

08:00-17:00	POSTER PRESENTATIONS	
08:00-17:00	EXHIBITION	
09:00-10:30	MAJOR SYMPOSIUM 2 Chairpersons: Ghali Ghali, James McCaul, Selçuk Basa	
09:00-09:30	What Will Happen to Face Lift Surgery in the Next 10 Years? – Jan Stanek (UK)	
09:30-10:00	Lipotransfer in the Head and Neck – Nick Kalavrezos (UK)	
10:00-10:30	Multidisciplinary Approaches in Severe Skeletal Discrepancies – Sina UÇKAN (Turkey)	
10:30-11:00	COFFEE BREAK	
11:00-12:00	ORAL ABSTRACT SESSION 2 HALL A Chairpersons: Manu Patel, Ümit Karaçaylı EDUCATIONAL	HALL B Chairpersons: Chetan Katre, Ayberk Altuğ SURGERY
	Audit of Delay in Oral and Maxillofacial Surgery operations in the Emergency Theatres in a major UK District General Hospital Dr. Tun Wildan	Minimally Invasive Surgery in the Management of Parotid Stones Dr. Meera Samani
	Use of Internet by Patients to Access Healthcare Information Focusing on Apicoectomies Dr. Marzyeh Parvizi	Advanced Bone Surgery: Piezosurgery in Cranio-Orbito Facial Area & Oral Surgery Dr. Stefano Mandrioli
	The Use of a Mobile Internet Application to Improve Eye Examinations in Maxillofacial Trauma - Limitations and Potential Improvements Dr. Thomas E Howe	Effects of Graft Augmentation Combined with Erythropoietin on the Regeneration and Vascularization of Calvarial Bone Defect Dr. Nurettin Diker
	Improving Standards of Operative Record Keeping in Oral & Maxillofacial Surgery: A Closed Loop Audit Dr. Ramanan Rajamanohara	The Effect of Osteotomy Technique on the Primary Stability of Implants Simultaneously Inserted in Maxillary Sinus Grafted Sites Dr. Alshaimaa Ahmed Shabaan

5-8 November 2014 - Harbiye Military Museum & Cultural Center - İstanbul / Turkey

	<p>The Impact of Facial Surgery Provided on Surgical Missions in Ethiopia Dr. Andrew Owen Jenkinson</p> <p>Alterations in Maxillary Sinus Volume among Oral and Nasal Breathers Dr. Kamil Serkan Ağaçaayak</p> <p>Cone-Beam Computed Tomography Findings of Zoledronic Acid and Teriparatide Administration Dr. Nilüfer Ersan</p>	<p>Manual Lymph Drainage Efficiency in Reducing Pain, Swelling and Trismus in Diabetes Mellitus patients following mandibular third molar surgery Dr. Arben Murtezani</p> <p>Fractures of the Zygomatic Complex- A comprehensive Review Over Ten Years of Surgical Management Dr. Susan McBride</p> <p>Finite-element analysis investigation of the new design titanium miniplate for the treatment of mandible angle fractures Dr. İbrahim Macit</p>
12:00-13:30	LUNCH	
12:15-13:15	<p>LUNCH AND LEARN SESSION ROOM A Chairpersons: Tian-Ee Seah, Hasan Garip</p>	<p>ROOM B Chairpersons: Andrew Lyons, Ülkem Cilasun</p>
12:15-13:15	Harvesting an ALT Flap – Kishore Shekar (UK) - Mark Singh (UK)	Rhinoplasty Procedures – Tim Mellor (UK)
13:30-15:30	<p>MAJOR SYMPOSIUM 3 Chairpersons: Vitomir Konstantinovic, Kavin Andi, Ayfer Kaynar</p>	
13:30-14:00	Management of War Injuries of the 21st Century – Satyesh Parmar (UK)	
14:00-14:30	Endoscopic Salivary Gland Surgery – Mark McGurk (UK)	
14:30-15:00	Amazing Breakthroughs in Maxillo-Mandibular Reconstruction – Selçuk BASA (Turkey)	
15:00-15:30	Frontal Sinus Trauma/ Dural Tear; How do I manage? – Simon Holmes (UK)	
15:30-16:00	COFFEE BREAK	
16:00-17:30	<p>SYMPOSIUM 3 Chairpersons: Fouad Ghareeb, Satyesh Parmar, Hanife Ataoğlu</p>	<p>SYMPOSIUM 4 Chairpersons: George Sandor, Bernard Speculand, Figen Senel</p>
16:00-16:30	Variations of Facial Nerve Surgical Anatomy in Parotid Surgery – Vladimir Popovski (Macedonia)	The Use of Piezo-surgery in OMFS – Daniel Hrusak (Czech Republic)
16:30-17:00	Future of Trans Oral Laser in Head & Neck Surgery – Fazilet Bekiroglu (UK)	Repair of Residual Alveolar Clefts – Timuçin BAYKUL (Turkey)
17:00-17:30	Experimental Microvascular Studies in Maxillofacial Surgery – Mehmet Emre Benlidayı (Turkey)	Investigation and Surgical Management of Speech Problems in Cleft Palate Patients – Nabil Samman (Hong Kong)
19:30	GALA DINNER	

5-8 November 2014 - Harbiye Military Museum & Cultural Center - İstanbul / Turkey

Saturday, 8th November

09:00-17:00	POSTER PRESENTATIONS	
09:00-17:00	EXHIBITION	
09:00-10:00	ORAL ABSTRACT SESSION 3 HALL A Chairpersons: Tim Mellor, Bora Özden TMJ & TRAUMA	HALL B Chairpersons: Özgür Pektaş, Burcu Baş TRAUMA and ORTHOGNATHIC SURGERY
	Dextrose Prolotherapy Versus Autologous Blood Injection in Management of Chronic Recurrent Temporomandibular Joint Dislocation Dr. Maggie Ahmed Khairy	Evaluation of Pre-Bent Miniplates in Fixation of Le Fort 1 Advancement Osteotomy with the Finite Element Method Dr. Fatih Mehmet Coskunes
	Management of Recurrent Ankylosis Around Prosthetic Joint Replacement Dr. Roya Rashidi	The Application of Facial Aponeurotic System in Controlling Nasal Widening Sequel of Midfacial Surgery Dr. Nima Moharamnejad
	Pterygopalatine Ganglion Blockade in patients with Atypical Facial Pain and Trigeminal Neuralgia Dr. Ezher Hamza Dayisoğlu	Cervical Vertebral Column Morphology and Association with Obstructive Sleep Apnea: A Pilot Study Dr. Ulas Oz
	Retromandibular Transparotid Approach for Subcondylar Fractures Dr. Nasuh Kolsuz	Relationship Between Duration of Preoperative CPAP Use and Outcomes Following Maxillomandibular advancement surgery for Obstructive Sleep Apnoea Dr. Shofiq Islam
	The Differing Fracture Patterns Produced by Anterior and Lateral Impacts to the Frontal Bone; Are They Relevant? Dr. Jonny Stephens	Use of a Bespoke Occlusal Cutting Guide for Genioplasty in Facial Asymmetry Dr. Iain Varley
	Recent Advances in Concepts of Enophthalmos of Orbital Floor Fractures From Trauma Dr. Anna Sayan	Orthognathic Surgery for Obstructive Sleep-Apnea Syndrome (OSAS) Dr. Altan Varol
10:00-10:30	COFFEE BREAK	
10:30-12:00	MAJOR SYMPOSIUM 4 Chairpersons: Nick Kalavrezos, Sanjay Sharma, Belgin Gülsün	
10:30-11:00	Management of Neonatal Micrognathia – Manlio Galie (Italy)	
11:00-11:30	Robotic Surgery in Sleep Apnea – Ghali Ghali (USA)	
11:30-12:00	Challenges of Secondary Cleft Correction – Mark Devlin (UK)	

12:00-13:30	LUNCH	
12:15-13:15	LUNCH AND LEARN SESSION ROOM A Chairpersons: Anna Sayan, Sinan Tozoğlu	ROOM B Chairpersons: Andrej Kansky, Umut Tekin
12:15-13:15	Harvesting Fibula Flap – Ceri Hughes (UK)	Genioplasty, Sliding and Box – Tian-Ee Seah (UK)
13:30-14:30	SYMPOSIUM 5 Chairpersons: Manlio Galie, Andrew Sidebottom, Alper Aktaş	SYMPOSIUM 6 Chairpersons: Vladimir Popovski, Ceri Hughes, Altan Varol
13:30-13:50	What a Maxillofacial Surgeon Needs to Know about Obstructive Sleep Apnea – Ian Ormiston (UK)	Advanced Surgical Planning for the Orbital Apex – Kavin Andi (UK)
13:50-14:10	Osteoradionecrosis Problems and Solutions – Andrej Kansky (Slovenia)	Anatomical Guidance and Fixation Techniques in Orthognathic Surgery - Osman Etöz (Turkey)
14:10-14:30	Strategy of Nasal Reconstruction in Atypical Nasal Clefts – Fouad Ghareeb (Egypt)	
15:00	PRESENTATION AWARDS AND CLOSING CEREMONY	



4th Conference of BAMFS (Balkan Association of Maxillofacial Surgeons)

5-8 November 2014 - Harbiye Military Museum & Cultural Center - İstanbul / Turkey

INVITED SPEAKER'S ABSTRACTS

Wednesday, 5th November

09:00-17:00	PRE-CONFERENCE COURSE
09:00-17:00	Virtual Treatment Planning for Orthognathic Surgery: Tips for Successful Surgical-Orthodontic Outcomes - Planning - Bryan Bell (USA)

R. Bryan Bell, MD, DDS, FACS

Virtual treatment planning for orthognathic surgery: tips for successful surgical-orthodontic outcomes

Computer aided surgical simulation (CASS) as a means of transferring virtual surgical planning to the patient is rapidly becoming the new standard of care in treatment planning for dentofacial deformity. A decade of research and experience has shown that CASS is more accurate than analytical model surgery and provides a versatile solution for three-dimensional clinical problems. Furthermore, commercial service providers have facilitated access to this technology to any surgeon in the world at an affordable price. This presentation will review Dr. Bell's clinical experience and research in the field of virtual surgical planning for orthognathic surgery, demonstrate recent technical refinements and technical innovations, and provide important tips for optimizing functional and esthetic outcomes in the treatment of facial deformity.

Thursday, 6th November

09:00-10:00	MINI COURSE
09:00-10:00	The Medical Management of Central Giant Cell Granulomas - M. Anthony Pogrel (USA)

M. Anthony Pogrel

The Medical Management of Central Giant Cell Granulomas

The central giant cell granuloma of the jaws remains an enigma that is difficult to classify, the histogenesis and histopathology remains doubtful, and the treatment is equally debated. For the past 60 years, these have generally been treated surgically with fairly aggressive curettage and a quoted recurrence rate of around 15-20%. However, in recent years, a number of medical treatments have been proposed and evaluated. These include intralesional corticosteroids, subcutaneous or intranasal calcitonin, subcutaneous alpha interferon, and more recently denosumab. The merits of these different treatments will be discussed together with our personal results.

Thursday, 6th November

10:00-12:00	MAJOR SYMPOSIUM 1
10:00-10:30	Amazing breakthroughs in maxillo-mandibular reconstruction – Selçuk BASA (Turkey)
10:30-11:00	Access in Head & Neck Surgery, the Role of Transoral Robotic Surgery and Cost Effectiveness – Bryan Bell (USA)
11:00-11:30	Inferior alveolar nerve damage from dental implants – M. Anthony Pogrel (USA)
11:30-12:00	Experience with Alloplastic TMJ Prosthesis and the Future – Bernard Speculand (UK)

Selçuk BASA (Turkey)

Amazing breakthroughs in maxillo-mandibular reconstruction

Reconstruction of jaws owes special considerations apart from well-known reconstructive procedures. Unpredictable morphologic changes are minimized with continuing improvement of virtual computer aided surgery and planning, thus predictions have become more realistic and accurate in 3-D virtual environment. In this lecture, the role of 3-D planning in maxillofacial reconstructive surgery will be presented with a broad range of various cases. The main goal of the lecture is to specify the key points for successful bony reconstruction of end-stage cases and to designate "which" reconstructive technique "when" and "how" should be done.

Access in Head & Neck Surgery, the Role of Transoral Robotic Surgery and Cost Effectiveness – Bryan Bell (USA)

M. Anthony Pogrel

Inferior Alveolar Nerve Damage from Dental Implants

In the United States, inferior alveolar nerve damage from dental implants has become the fastest growing medicolegal problem in dentistry. If unchecked it will therefore eventually become the largest single medicolegal problem. This lecture will address the evaluation of patients requiring osseointegrated dental implants placed in the mandible, posterior to the mental foramen. The lecture will cover preoperative evaluation, correct surgical placement of the implant including the

use of surgical guides and drill stops, as well as protocols for the management of inferior alveolar nerve injuries from dental implants if they occur.

Bernard Speculand

Experience with alloplastic TMJ Prosthesis and the Future

Alloplastic TMJ total joint replacement (TJR) began in the UK in 1987/88 in 2 centres, Birmingham and Gloucester, using the Vitek-Kent VKII system. Today , 26 years later, there are 16 identified UK TMJ TJR surgeons based in England and Scotland, together operating on approximately 100 patients a year in a country of 62 million people.

The systems used are mostly TMJ Concepts, and Biomet. We have a national database and approval from NICE, the UK's equivalent of the FDA.

This presentation charts the development of this type of surgery, and looks at surgical, technical and anaesthetic issues. Complications, costs, alternatives, and longevity of devices will be discussed.

The future will be considered in relation to training, the need to discourage the occasional surgeon (low volume operator), the need for outcome data collection at a national level, and the gradual application of this type of surgery to more complex cases including younger patients.

University Hospitals Birmingham UK

Thursday, 6th November

12:15-13:15	LUNCH AND LEARN SESSION ROOM A
12:15-13:15	Non-Surgical Facial Rejuvenation – Rajiv Anand (UK) - Sanjay Sharma (UK)

Mr Rajiv Anand & Mr Sanjay Sharma

Non-Surgical Facial Rejuvenation

The session will concentrate on botulinum toxin and dermal filler use in facial rejuvenation. An interactive experience with delegates in “mini-workshops” will enhance the learning experience. We

5-8 November 2014 - Harbiye Military Museum & Cultural Center - İstanbul / Turkey

hope to finish with a question and answer session to advise on any specific problem areas during practice.

Aims:

1. To provide an overview of the safe practice of botulinum toxins in facial rejuvenation
2. To provide an overview of the safe practice of dermal fillers in facial rejuvenation

Objectives: After the session delegates should:

1. be able to select patients suitable for botulinum toxin treatment
2. be able to mark out areas and doses suitable for facial rejuvenation
3. be able to define the high risk areas for safe practice
4. be able to outline the types of dermal filler
5. be able to describe the injection techniques
6. be able to describe possible complications and how to avoid them

If time is available other non-surgical rejuvenation techniques will be discussed.

Thursday, 6th November

12:15-13:15	LUNCH AND LEARN SESSION ROOM B
12:15-13:15	Reconstructive Options for the TMJ – Andrew Sidebottom (UK)

Andrew J Sidebottom, Nottingham UK

Reconstructive Options for the TMJ

Reconstruction of the irreparably damaged temporomandibular joint (TMJ) is dependent on the the patient's age and the cause of damage. In childhood the current preference is for autogenous reconstruction which has the facility to "grow" with the child. This may be a simple gap arthroplasty possibly with soft tissue interposition (temporalis fascial interposition). Alternative bony reconstructions include local subsigmoid vertical advancement osteotomy, distraction osteogenesis, non-vascularised tissue (costochondral, sternoclavicular) or vascularised tissue (second metatarsal). Current debate centres around the possibility of alloplastic reconstruction particularly where autogenous tissue has failed. The resultant failure of growth – if this occurs, can be dealt with in late adolescence with either osteotomy, distraction osteogenesis or replacement of the condylar component with a prosthesis.

In the adult the choice in Europe and the USA currently lies in favour of alloplastic reconstruction as this causes less morbidity, facilitates early mobilisation and gives a more stable long term result. Initial cost is clearly an issue, but when weighted against the reduced length of stay and reduced morbidity, often the costs are equivalent in the short term and come to benefit alloplasts in the medium term. Their long term outcomes beyond 15 years are however not clear.

The aim of this symposium is to discuss these options based on personal experience and review of the literature of the subject.

Thursday, 6th November

13:30-14:30	SYMPOSIUM 1 – Hall A
13:30-13:50	The modern Management of Oro Pharyngeal Cancer – Graham Smith (UK)
13:50-14:10	Electro Chemo Therapy in Advanced Cancers – James McCaul (UK)
14:10-14:30	Principles of local flaps for facial reconstruction – Vedran Uglesic (Crotia)

Graham Smith, UK

The modern management of oropharyngeal cancer

Oropharyngeal cancer has the fastest growing incidence of all head and neck cancer sub-sites. Human papilloma virus is the leading cause of oropharyngeal cancers and accounts for over 25% of patients with head and neck cancer.

This presentation will review:

- the demographic data of HPV-positive and HPV-negative patients
- HPV sub-types and risk factors
- diagnosis and investigations including an algorithm for managing patients with an unknown primary
- radiotherapy/ chemoradiotherapy
- role of de-escalation in HPV positive patients
- salvage surgery and reconstruction
- role of robotic surgery
- cancer prevention and HPV vaccination

James McCaul (UK)

Electro Chemo Therapy in Advanced Cancers

Electrochemotherapy (ECT) delivers targeted chemotherapy to tumour cells. It has proven effectiveness in treatment of skin, subcutaneous and mucosal tumours with limited damage to healthy tissues (including neurovascular structures in close proximity). It is independent of tumour histopathological type. Recurrent or extensive primary neoplasms of the head and neck are challenging for surgeons and debilitating for patients. The advantages of ECT include limited damage to healthy tissues and good cosmetic and functional results, limited side effects, and an advantageous cost/benefit ratio. In head and neck squamous cell carcinoma (HNSCC) this treatment modality is currently being evaluated in the EURECA trial (EUropean REsearch on Electrochemotherapy in Head and Neck CANcer) trial.

Patients with advanced HNSCC for whom other treatment options are not possible are eligible. The IGEA cliniporator™ electroporates intravenously delivered bleomycin (15,000 units/m²) into tumour cells selectively. We have treated 23 patients to date at Bradford Teaching Hospitals and the Royal Marsden hospital.

Immediate tumour response involves reduction in bleeding and change in hue of tumour tissue, providing a guide to the treating surgeon. Clinical response assessed by RECIST criteria demonstrates a partial response (>30% reduction in maximum dimension) on CT/MRI and later PETCT imaging analysis in most cases. Pain diaries have shown improved symptom control and the often-offensive odour associated with advanced fungating lesions improves or disappears improving quality of life.

Early data suggests that ECT may offer an acceptable and effective treatment for some patients who may under traditional therapeutic pathways have few or no other options.

Vedran Uglesic (Croatia)

Principles of facial reconstruction

The presentation covers the main principles of facial reconstruction including skin grafting and local flaps. The aim of every facial reconstruction is to close the defect, to restore the function and aesthetics and to hide the scar.

In order to achieve these goals we use the simplest method of reconstruction but at the same time we go for the maximum possible result and the most favourable outcome.

When planning a facial reconstruction, we must ask ourselves the following questions:

- How to preserve aesthetic of the recipient site?
- From where to bring the same quality tissue?
- How preserve aesthetics of the donor site?
- How to hide the scar?

For each reconstruction we follow the same principles. Firstly, we must make a reconstructive plan before the surgery according to the reconstructive goals. You always need to have a backup plan. The defect always needs to be considered in all three dimensions. For the reconstruction of the affected side, we use the healthy side as a model for the reconstruction. In planning the reconstruction we must always be guided by the aesthetic units of the face.

All the above topics will be explained by presenting relevant examples.

Thursday, 6th November

SYMPOSIUM 2 - Hall B

Temporomandibular custom hemi-joint concept: a paradigm shift for TMJ – Umut TEKİN (Turkey)

Minor Salivary Gland Tumors: From Diagnosis to Treatment – Nick Papadogeorgakis (Greece)

Strategic - Bicortical Implantology – Vitomir Konstantinovic (Serbia)

Umut TEKİN (Turkey)

Temporomandibular custom hemijoint concept: a paradigm shift for TMJ

The temporomandibular surgery (TMJ) is a complex articulation and depending on the available TMJ prosthesis model. Various treatment methods have been described for TMJ replacement. A hemijoint replacement arthroplasty is used for the treatment of advanced osteoarthritis or fibrous/bone ankylosis.

Advances in computers and imaging have permitted the adoption of 3-Dimensional (3D) virtual planning protocols in TMJ surgery, which may allow a paradigm shift when the virtual planning can be transferred properly.

5-8 November 2014 - Harbiye Military Museum & Cultural Center - İstanbul / Turkey

The metal fossa implant is a custom TMJ for each patient's anatomy and is constructed from 3D models generated from the patient-specific computed tomography (CT) scan. The custom hemijoint surgery is predictable as far as prosthesis insertion fit, the total operative time is reduced. An innovative solution would be available to enable a paradigm shift in TMJ surgery.

Nick Papadogeorgakis

Minor Salivary Gland Tumors: From Diagnosis to Treatment

There are about 300 - 700 minor salivary glands dispersed mainly in the oral cavity, in areas like: hard palate, lips, tongue, buccal cavity mucosa, floor of the mouth, gingiva, nasal cavity and paranasal sinuses. They can also be found in pharynx (soft palate, base of the tongue, tonsils) and the parapharyngeal space. However, they may arise in ectopic positions, even inside the bones. Although all types of benign and malignant tumors of the major salivary glands can also appear in the minor salivary glands, there are still controversies in the international literature concerning malignancies. Diagnosis is due to patient's medical record, lesion history, clinical examination and para-clinical tests like: tooth viability test, panoramic X-ray, FNA, U/S guided FNA, True -cut, open biopsy, CT, MRI, MRA, bone scan and Pet Scan. The treatment of benign tumors depends on the type, size and location of the lesion. The treatment of malignancies depends on the histological type and grade of tumor, the stage of tumor, its size, location, the presence of cervical and distant metastases, as well as the age and general health status of the patient. A series of 58 patients with benign minor salivary gland tumors and 41 cases with malignancies are presented, and the diagnostic procedure, treatment and outcome are discussed.

Vitomir S. Konstantinović, Serbia

Strategic - Bicortical Implantology

Generally, the most common problems in implantology is lack of the alveolar bone. Nevertheless, several solutions are proposed to overcome that difficulty. Bone augmentation techniques, as well as alveolar distraction osteogenesis could develop enough bone for insertion of osseointegrated implants. However, treatment outcome becomes unpredictable, lengthy and expensive, as soon as bone augmentation procedures are involved.

The goal of this lecture is to present our philosophy of "STRATEGIC IMPLANTOLOGY" .

Strategic implantology is developed from "basal" implantology that used resorption free basal part of maxilla and mandible for implant anchorage. All available facial bones like zygoma and pterygoid process of sphenoid bones are used for implant insertion. Idea of "basal implantology" came from orthopaedic surgery, and could be categorised as "oral division of orthopaedic surgery".

Specificity of this implants is their possibility of immediate loading because of extremely high primary stability in the compact bone using bicortical or multicortical osseointegration. Bicortical screws (BCS) are nowadays almost exclusively used.

Patients with severely resorbed maxilla and mandible rehabilitated with fixed implant supported dental prosthesis in immediate loading protocol will be shown.

Thursday, 6th November

16:30-17:30	ACBİD – BAOMS JOINT ORATION
16:30-17:30	Cosmetic Facial Surgery: The Role of the Oral and Maxillofacial Surgeon Ghali Ghali (USA)

G. E. Ghali, DDS, MD, FACS

Cosmetic Facial Surgery: The Role of the Oral and Maxillofacial Surgeon

Over the past two decades, numerous advancements in techniques for facial rejuvenation have arrived globally. The ability to complement our common oral surgical procedures should be of paramount importance to the practicing surgeon. From the management of peri-oral rhytids with fillers and peels, to the management of more complex cosmetic facial deformities with lifting procedures, these procedures provide the oral and maxillofacial surgeon an opportunity to successfully manage both soft and hard tissue conditions predictably. This presentation will highlight the simple to the more advanced modalities available to the oral and maxillofacial surgeon for aesthetic rejuvenation of the face. Appropriate diagnosis and treatment planning with follow-up and complication management will be detailed.

Friday, 7th November

09:00-10:30	MAJOR SYMPOSIUM 2
09:00-09:30	What will happen to Face Lift Surgery in the next 10 years? – Jan Stanek (UK)
09:30-10:00	Lipotransfer in the Head and Neck – Nick Kalavrezos (UK)
10:00-10:30	Multidisciplinary approaches in severe skeletal discrepancies – Sina UÇKAN (Turkey)

Jan Stanek FRCS, Private Practice, London UK

What Will Happen to Facelift Surgery In The Next 10 Years?

Rhytidectomy, in various forms, has been practised since the turn of the 20th century. For the first 20 years it consisted of skin excision and from 1932 for the next 40 years skin was elevated and tightened to produce desired effect.

The first 60 years of relatively little progress was surpassed by the discovery of SMAS and Skoog's sub-SMAS lifting. Since then the attention has focused on the best way of tightening the SMAS with secure and long-lasting fixation.

In 1980s subperiosteal lifting, based on Tessier's approach came into vogue, followed shortly by the introduction of facial endoscopy. Despite initial enthusiasm subperiosteal face-lifting is largely forgotten and being practised in the forehead and mid-face only.

In the meantime other alternative techniques have been introduced in the hope of minimising, or even avoiding, invasive surgical interventions.

The author discusses possible evolution of the current techniques and discusses the ways ahead.

He concludes that within the next 10 years it is unlikely that a new revolutionary technique of face-lifting will appear and that further improvement of results and reduction of complications will depend on improved training and selection of super-specialised surgeons with a background in facial plastic surgery.

5-8 November 2014 - Harbiye Military Museum & Cultural Center - İstanbul / Turkey

Nicholas Kalavrezos, FRCS, MD

Lipotransfer in Head & Neck

Fibrosis of skin and subcutaneous tissues is a common consequence following treatment for head and neck cancer. It often occurs following surgery and extensively as a late feature of radiotherapy treatment, causing significant long-term morbidity and reducing quality of life. Common adverse effects of radiotherapy-induced fibrosis include pain, impaired mobility, neuropathy, speech, swallowing and breathing problems. Clinician-based scoring systems and patient reported outcome tools have frequently been used to stratify the features and effects of fibrosis. Issues regarding the validity and reliability of these systems heralded the utility of objective measurements to quantify the effects of fibrosis.

The pathogenesis of fibrosis is historically divided into early and late phases, however recent evidence suggests a continuum of effects over years to decades. Histological changes in the dermis and more recently the epidermis have been identified following radiation damage, adding value to this theory. Cytological changes in dermal fibroblasts and epidermal keratinocytes have also been characterised.

Among other medical treatments, fat grafting has emerged as an efficacious method of rehabilitating patients with radiotherapy-induced fibrosis, showing benefit in improving function, quality of life and tissue histology. The processes underlying these changes are yet to be fully elucidated.

This review evaluates current methods of assessing fibrosis-induced morbidity and how these may aid the identification of the mechanisms underlying the clinical benefits afforded by fat-graft treatment.

Head & Neck/Reconstructive Surgeon
University College London Hospitals
London, UK

Sina UÇKAN (Turkey)

Multidisciplinary approaches in severe skeletal discrepancies

Management of severe skeletal discrepancies is possible by only a team work. In this presentation examples of this team work with other disciplines including orthodontics, ear-nose-throat and especially with psychiatry will be analysed.

Friday, 7th November

12:15-13:15	LUNCH AND LEARN SESSION ROOM A
12:15-13:15	Harvesting an ALT Flap – Kishore Shekar (UK) - Mark Singh (UK)

Kishore Shekar (UK) - Mark Singh (UK)

Masterclass: ALT flaps in head and neck reconstruction

The masterclass aims:

To give an overview of the surgical anatomy

Modifications in flap design

Variations in vascular anatomy

Discuss indications and contraindications

Case discussions

The radial forearm free flap has been the work horse flap for reconstruction of oral mucosal defects. Due to equally good reliability of perforator flaps, the authors have chosen this flap over the RFFF for reconstruction of large head and neck soft tissue defects. The thigh flap can be raised as a perforator flap, myo-cutaneous flap and as a muscle flap alone. The pedicle length and diameter is suitable constant for the safe harvest of this flap.

We hope to discuss the aims as above on this masterclass.

Friday, 7th November

12:15-13:15	LUNCH AND LEARN SESSION ROOM B
12:15-13:15	Rhinoplasty Procedures – Tim Mellor (UK)

Tim Mellor

Rhinoplasty - A simple approach for beginners

Rhinoplasty changed from a procedure to construct a nose lost through punishment, war or accident to one in which the size or shape of the nose is changed to improve appearance, in the late 1800s. This has particularly been refined towards the end of the 20th century. This session will develop the basics of open rhinoplasty allowing the attendee to learn a straightforward approach to basic rhinoplasty.

The delegate will learn with the use of patient examples:

The open approach

Management of dorsum & nasal bones

Tip procedures

Grafting procedures

Post-operative care

Complications

Care of the “unhappy” patient

Friday, 7th November

13:30-15:30	MAJOR SYMPOSIUM 3
13:30-14:00	Management of War Injuries of the 21st Century – Satyesh Parmar (UK)
14:00-14:30	Endoscopic Salivary Gland Surgery – Mark McGurk (UK)
14:30-15:00	Adipose Stem Cells for Cranio-maxillofacial Reconstruction: Present Art and Future Direction George Sandor (Finland)
15:00-15:30	Frontal Sinus Trauma/ Dural Tear; How do I manage? – Simon Holmes (UK)

5-8 November 2014 - Harbiye Military Museum & Cultural Center - İstanbul / Turkey

Satyesh Parmar

Management of War Injuries in the 21st Century

Ballistic Injuries are relatively rare in the United Kingdom and thus few surgeons have any experience in treating these complex injuries

The Centre for Defense Medicine in the United Kingdom rationalized the pathways of care for any British Soldier injured abroad and centralized all the primary treatment at the University Hospital Birmingham.

The rapid response teams in war zones and modern resuscitation techniques have resulted in many more soldiers surviving severe injuries.

Any British soldier injured abroad was transferred to us for definitive treatment after initial stabilization locally.

The Oral and Maxillofacial Surgeons in Birmingham thus had a steep learning curve in how to optimally treat these complex facial injuries during the Iraq and Afghanistan wars.

This lecture will illustrate our practice in the treatment of patients with facial ballistic injuries and how it differs from other countries where gunshot injuries are much more common.

Mark McGurk

Endoscopic Salivary Gland Surgery

In the last decade there has been a revolution in the management of obstructive salivary gland disease. The current standard of care for chronic salivary obstruction of both the parotid and submandibular glands is sialoadenectomy. Advances in technology primarily directed at urinary stones have produced endoscopes, baskets and lithotripters capable of eradicating these urinary calculi. This equipment has now been miniaturised and made available to those interested in minimally invasive salivary gland surgery.

It is now possible to retrieve most stones by either basket or endoscope-assisted surgery preserving the salivary glands. Five European centres have pioneered this work and collectively published a paper with over 4000 patients where stone eradication rate was 80% and only 3% of glands were removed.

5-8 November 2014 - Harbiye Military Museum & Cultural Center - İstanbul / Turkey

In this presentation the technique adopted for minimally invasive management of salivary strictures and stones will be detailed together with further developments that are currently accelerating the change towards minimally invasive management of obstructive salivary gland disease.

G.K. Sándor MD, DDS, PhD

Adipose Stem Cells for Cranio-maxillofacial Reconstruction: Present Art and Future Direction

Basic understanding of the pathobiology of mesenchymal stem cells (MSCs), has led to the development of tissue engineered constructs which can be adapted to treat bony defects. A primary source of MSCs for bone tissue engineering is fat which is rich in adipose-derived stem cells (ASCs). The interdependency between mesenchymal cell lines, adipogenesis and also osteogenesis allows ASCs to be used for bone regeneration.

The objective is to present the clinical experience with reconstruction of large craniofacial osseous defects with ASCs. Autogenous fat from the anterior abdominal wall of the patients is routinely harvested and taken to a central tissue banking laboratory for *ex-vivo* expansion. The ASCs are seeded onto resorbable scaffolds and growth factors can be added. Vascularized soft tissue beds are prepared for *ectopic bone* formation and later microvascular translocation where indicated. Alternatively ASC seeded constructs are used with an *in situ* ossification protocol. Though autogenous ASC aided reconstruction of large defects is currently technique sensitive, of long duration and more costly than conventional standard immediate reconstruction, these factors will change with future familiarity and experience with the procedures. Likewise practitioners will learn which cases and levels of complexity require *ectopic bone formation* and *in situ ossification* protocols. Long-term results and clinical observations of treated cases are extremely encouraging.

In the future, with evolving technological advances, ASC aided reconstruction will be regularly used in clinical practise. Possibilities with allogeneic stem cells moving towards an off-the-shelf type of product like the allogeneic pooled mesenchymal stem cell derivative Prochymal™ may be a future trend in reconstructive tissue engineering.

**Professor of Tissue Engineering, Professor of Oral and Maxillofacial Surgery,
University of Oulu, Oulu, Finland,
Director of Research, BioMediTech, University of Tampere, Tampere, Finland**

Simon Holmes (UK)

Frontal sinus trauma / Dural Tear, How do I manage?

Injuries to the upper third of the craniofacial skeleton are amongst the most difficult cases to manage in both the primary and secondary care settings.

High energy transfer across the anterior skull base causes both aesthetic and functional challenges that can only be addressed by a joined up team approach involving dedicated multidisciplinary members.

The frontal bar is of primary strategic concern in the reconstruction of upper and middle third disruption, and a variety of techniques involving primary repair, alloplastic reconstruction, and primary bone grafting may be required. In addition the frontal sinus has to be managed in a co-ordinated manner to prevent short, medium, and long-term complications. A stepwise treatment algorithm to aid decision-making will be discussed illustrating that neurosurgical management runs seamlessly hand-in-hand with the facial skeletal reconstruction.

Strategies of management should address all challenges, with the final treatment goal of an aesthetic and neurosurgical stable anterior skull base readily achievable.

Friday, 7th November

16:00-17:30	SYMPOSIUM 3 - Hall A
16:00-16:30	Variations of Facial Nerve Surgical Anatomy in Parotid Surgery – Vladimir Popovski (Macedonia)
16:30-17:00	Future of Trans Oral Laser in Head & Neck Surgery – Fazilet Bekiroglu (UK)
17:00-17:30	Experimental Microvascular Studies in Maxillofacial Surgery – Mehmet Emre Benlidayı (Turkey)

Vladimir Popovski (Macedonia)

Variations of the Facial Nerve Surgical Anatomy In Parotid Surgery

Introduction: The relationship of the parotid gland to the facial nerve is of primary surgical importance in parotid surgery. Regional anatomical peculiarity and evident high percentage of facial nerve (FN) branching variations create the necessity of competent surgical approach.

Material and methods: We have analyzed the records and measurements about surgical anatomy variations of FN variations on 81 consecutive patients who underwent parotid surgery at our institution with attention to imaging findings, operative trunk distance, type of peripheral pattern of FN branching and interconnections. Additional comparative analyze was made with anatomists on 20 cadaver dissections with accent on extraglandular variations until the level of lateral palpebral line.

Results: Mean distance from the pointer to the FN trunk and bifurcation was 13 mm, ranging from 12.0 mm and 13.5 mm respectively. Hypoplastic or hyperplastic main trunk was present in 11.8%. Greatest parts of variations were in upper division of five level branching. On cadaveric cervicofacial dissections marginal mandibular branch was below the mandibular border in 45.8%. The frequency of peripheral pattern and connections of the facial nerve were type III (32.1%), type I (27.1%), type IV (23.5%), type II (17.3%). In every distinctive type subsequent subtype was included.

Conclusion: The extratemporal FN branching pattern is extremely variable. Distinct knowledge of the facial nerve extratemporal anatomy and its variations is critical to enable safe dissection through the plane of the face particularly during parotid surgery or rhytidectomy.

Fazilet Bekiroglu (UK)

Abstract for Future of TLM in Head and Neck Surgery presentation

*** The incidence of squamous cell carcinoma of the oropharynx is rising. This trend is due to the association of human papillomavirus and oropharyngeal cancers. For early oral squamous cell carcinoma, primary surgery using laser and leaving the defect to heal by secondary intention is accepted technique. The role of primary surgery in oropharyngeal cancer remains somewhat contentious. Traditional open surgery involves lip-split mandibulotomy to gain access to the oropharynx, followed by free-flap reconstruction of the oropharyngeal defect. Effectiveness of primary radiotherapy (RT) or con- current chemoradiotherapy (CRT) brings the question of role of primary surgery particularly when many patients will receive adjuvant RT anyway. However, over recent decades, transoral laser microsurgery (TLM) has gained popularity as a surgical option as it is believed by proponents of the technique that TLM results in superior functional outcomes, in particular better swallowing function. Our data from University Hospital Aintree, Liverpool supports the literature that TLM offers short duration of treatment with low morbidity and excellent functional outcomes compared with RT and CRT.

Mehmet Emre Benlidayı (Turkey)

Experimental Microvascular Studies in Maxillofacial Surgery

Reconstruction of the maxillofacial defects has been a challenge due to the significant complexity of function and esthetics. Vascularized bone flaps and non-vascularized bone grafts are both widely used to reconstruct the defects. The development of microsurgical free tissue transfer became popular in maxillofacial reconstruction due to the ability to transfer vascularized bone and soft tissue in one stage at the time of the resection, with predictable high success rates.

As remarkable advances have been made in microsurgical free tissue transfer, several additional basic science questions have arisen. Therefore, development of a proper experimental model for flap basic science research is of critical importance. Animal-based research has a major role in advancing our knowledge of many aspects of the biology and reconstruction techniques of bone. In maxillofacial surgery, several studies have used vascularized bone flaps in animals with which other methods of reconstruction and bony replacement materials have been compared. The pigs are proper animal model since the gross anatomy of the maxillofacial region is similar to that of humans.

In this lecture reconstruction of the mandibular defects with vascularized femur flaps in pigs and histomorphometric evaluation method of the specimens will be presented.

Friday, 7th November

16:00-17:30	SYMPOSIUM 4 - Hall B
16:00-16:30	The Use of Piezo-surgery in OMFS – Daniel Hrusak (Czech Republic)
16:30-17:00	Repair of Residual Alveolar Clefts – Timuçin BAYKUL (Turkey)
17:00-17:30	Investigation and Surgical Management of Speech Problems in Cleft Palate Patients – Nabil Samman (Hong Kong)

Daniel Hrusak (Czech Republic)

The Use of Piezo-surgery in OMFS

In 2002 the Piezosurgery technique was introduced to dental surgeons for sinus lift and dental implantology. Since that time the use in maxillofacial surgery on facial bones and jaws was proven many times mainly for its safety to soft tissues, low risk of bad splits and versatility in use. Definitely not only the fact that different producers are delivering various equipment for ultrasound bone surgery demonstrates the benefits of this 21st century technique. The author presents his own long

time experience and the development of this superior bone preparation tool. Exceeding dentaolveolar procedures, piezosurgery is used for all procedures in orthognatic surgery, maxillary Le Fort I osteotomies and BSSO and Oncological resections of jaws and facial bones are performed with piezosurgery for more than 10 years at the department for Maxillofacial surgery of the University Hospital in Pilsen. The different technical features and procedures are demonstrated by peroperative pictures and video clips.

University Hospital Pilsen, Dept. of Maxillofacial Surgery, Medical Faculty Pilsen , Charles University Prague (Czech Republic)

Timuçin BAYKUL (Turkey)

Repair of Residual Alveolar Clefts

Potential advantages of the alveolar bone grafting include preventing collapse of the alveolar segments, stabilizing the maxillary arch, providing stable alveolar bone for the canine and the lateral incisors to erupt into the arch, maintaining bony support of teeth adjacent to the cleft, restoring the maxilla at the piriform rim, providing improved stability and aesthetics by supporting the alar base, and eliminating the oronasal fistula. Also, restoring facial symmetry, providing lip support, and improving oral hygiene could be achieved by alveolar cleft repair. Cancellous bone grafting has become the criterion standard treatment of residual alveolar clefts. Secondary alveolar bone grafting performed at the end of the mixed dentition is the most accepted procedure. The ideal patient for this procedure is between 8 and 12 years of age with a maxillary canine root that is one half to two thirds complete. Late secondary bone grafting is associated with less graft take, more remodeling, and less alveolar height but provides maxillary continuity and supports the alar base, which improves the aesthetics. An important goal in the treatment of residual alveolar clefts is to normalize not only the alveolar process but also the whole nasoalveolar complex. For a successful alveolar repair, closure of the oronasal fistula, bony continuity or arch stability, presence of cortical or cancellous bone, adequate amount of alveolar bone for canine root coverage, retention of the canine tooth or lateral incisor, and clinically healthy, noninflamed attached gingiva must be achieved.

Nabil Samman, Hong Kong, China

Management of Speech Problems In Cleft Lip and Palate With Emphasis On Surgical Aspects

Speech in repaired cleft lip and palate (CLP) patients is an important outcome of treatment and a determinant of quality of life. Investigation involves perceptual and objective assessment including pharyngoscopy. Surgical treatment is restricted for demonstrable cases of velopharyngeal incompetence and the outcomes of surgery are variable.

The presentation explores the process of investigation and management of speech problems, and a detailed description of the available surgical procedures, their indications and results will be given.

Saturday, 8th November

10:30-12:00	MAJOR SYMPOSIUM 4
10:30-11:00	Management of neonatal micrognathia – Manlio Galie (Italy)
11:00-11:30	Robotic Surgery in Sleep Apnea – Ghali Ghali (USA)
11:30-12:00	Challenges of Secondary Cleft Correction – Mark Devlin (UK)

Manlio Galie

Distraction Osteogenesis in Neonatal & Pediatric Micrognathia

Distraction Osteogenesis (DO) has been one of the most innovative concepts in craniomaxillofacial syndromology and surgery through the last 25 years.

In 1987 Cesar A. Guerrero first performed a mandibular widening by distraction osteogenesis.

Joseph G. McCarthy in 1992 published an extensive paper on the treatment of hemifacial microsomia.

In 1994 Wangerin and Gropp and in 1996 Diner et al. published on the use of intraoral devices for mandibular distraction.

After a quarter of century of extensive use DO has today specific indications for congenital craniofacial and cleft deformities.

Technology has evolved from the first application of external devices to intraoral and hybrid or semiburied techniques.

In congenital craniomaxillofacial anomalies distraction is indicated during growth. Mandibular distraction osteogenesis can be safely and effectively used to avoid or remove tracheostomy in neonates with severe airway obstruction caused by micrognathia in Pierre Robin Sequence.

For selected newborns, mandibular DO will allow for avoidance of a tracheostomy and improved oral feeding. A careful evaluation of the patient's airway and feeding must be performed and evaluated by a multidisciplinary Team approach.

In syndromic micrognathia early mandibular distraction seems to be an appropriate indication. Benefits are functional, morphological, aesthetic with consistent psychological and familiar positive effects.

An increased incidence in TMJ complication during distraction osteogenesis in neonates has been recently reported, especially in syndromic patients.

TMJ ankylosis after neonatal Mandibular Distraction Osteogenesis could be considered a new pathological entity.

EACMFS Educational & Training Officer

Unit of Cranio Maxillo Facial Surgery
Center for Orbital Pathology & Surgery
Reference Center for Rare Diseases
EACMFS Teaching Center Network
(Director and Chief: Prof. Luigi C. Clauser)

St. Anna Hospital and University
Via Aldo Moro, 8 44124, FERRARA – Cona, Italy

G. E. Ghali, DDS, MD, FACS

Robotic Surgery in Sleep Apnea

Synopsis:

This presentation will present new advances in the surgical treatment of obstructive sleep apnea with the da Vinci Robot.

Learning Objectives:

- 1) Discuss multiple alternative surgical treatments for patients with obstructive sleep apnea

- 2) Understand the anatomic areas affected and the instrumentation utilized with this treatment modality
- 3) Explain initial patient outcome results

Mark F Devlin

FRCSEd(OMFS) FRCSEd FRCS(Glasg) FDSRCPS MBChB BDS

The management of secondary cleft deformity.

The aetiology of secondary deformity relating to cleft lip and/or palate will be discussed. The common theories of aetiology will be explored regarding current evidence.

A clinical pathway and team approach to managing these clinical problems has been developed in Glasgow and this will be described. The multidisciplinary team approach will be advocated.

Clinical cases will be presented that cover some common areas of secondary cleft surgical intervention.

Consultant Cleft and Maxillofacial Surgeon, Glasgow, Scotland.

Saturday, 8th November

12:15-13:15	LUNCH AND LEARN SESSION ROOM A
12:15-13:15	Harvesting Fibula Flap – Ceri Hughes (UK)

Ceri Hughes

Harvesting Fibular Flap

The reconstruction of mandibular defects following ablative surgery for oral cancer has become routine. A debate still continues as to which free tissue reconstructive flap offers best utility. The author will discuss his personal experience with both fibular and DCIA flaps with insight into the operative nuances that lead to success.

Saturday, 8th November

12:15-13:15	LUNCH AND LEARN SESSION ROOM B
12:15-13:15	Genioplasty, Sliding and Box – Tian-Ee Seah (UK)

Tian-Ee Seah

Genioplasty, Sliding and Box

The technique of genioplasty has undergone several modifications and developments since its first introduction by Hofer in 1942. The sliding genioplasty is a recognized technique due to its versatility. Another alternative option is the box genioplasty. This procedure a simple process that takes little time, and has reduced chances of sensory nerve complications. Clinically, both sliding or box genioplasty procedures can be carried out as part of orthognathic or facial aesthetic surgery.

Saturday, 8th November

13:30-14:30	SYMPOSIUM 5 - Hall A
13:30-13:50	What a Maxillofacial Surgeon Needs to Know about Obstructive Sleep Apnea – Ian Ormiston (UK)
13:50-14:10	Osteoradionecrosis Problems and Solutions – Andrej Kinsky (Slovenia)
14:10-14:30	Strategy of nasal reconstruction in atypical nasal clefts – Fouad Ghareeb (Egypt)

Ian Ormiston, FDSRCS, FHKAM, FRCS.

What Does an Oral and Maxillofacial Surgeon Need to Know about Sleep Medicine?

A large part of sleep medicine involves the recognition, diagnosis and management of sleep related breathing disorders. Obstructive sleep apnoea (OSA) and snoring forms the bulk of the work in a sleep clinic. Failure to correctly manage OSA can result in death. Maxillofacial surgeons have a number of surgical procedures and methods at their disposal to manipulate and modify the posterior airway and hence help this increasingly large number of patients. Obesity and OSA are increasing rapidly in Europe and Asia. Medical management can be successful using continuous positive airways pressure (CPAP), together with weight loss. Surgical interventions however are often sought and requested either following failure of medical management or an inability to tolerate lifelong

5-8 November 2014 - Harbiye Military Museum & Cultural Center - İstanbul / Turkey

CPAP. Sleep studies are important, accurate diagnosis is vital. When to operate, whom to operate on and what operation to consider will be discussed. The Cochran collaboration on surgery for obstructive sleep apnoea in adults (2009)¹ states that 'systematic review did not identify any randomised trials to support surgical interventions in the treatment of OSA'. We would dispute this. Procedures which modify the posterior airway will be discussed including tracheostomy, bimaxillary advancement surgery and palatoplasty.

The results of 50 consecutive cases of maxillary surgery for moderate to severe obstructive sleep apnoea indicating an 85% success often with improved facial aesthetics will be reported. Working with a local sleep medicine team can be very rewarding. A basic knowledge of sleep medicine is extremely valuable.

1. Cochran collaboration 2009 – Issue 4 Sundaram et al.

Andrej Kansky

Osteonecrosis of the Jaw

Keywords: osteonecrosis, the jaw, radiation, bisfosfonates, tooth extraction

Osteonecrosis of the jaw (ONJ) occurs when jaws lose normal blood supply and are in the same time exposed to trauma (most common tooth extraction). As the name indicates (osteo meaning bone and necrosis meaning death), certain part of the bone dies and it penetrates through mucosa in the mouth, causing chronic inflammation and pain. ONJ is associated with head and neck cancer treatment (radiation), infection, antiresorptive therapies that include bisphosphonates, in osteopetrosis, rarely by steroid use. ONJ can in rare cases also occur without any identifiable risk factors. Diagnosis is set on the basis of clinical picture, x ray, CT scan, and pathohistological examination.

Treatment is first conservative, later when necrosis progresses, surgical treatment is essential. Support with hyperbaric oxygenation (HBO) is recommended. As the results of treatment are unpredictable, it is important to prevent osteoradionecrosis. In tooth extractions special care is required, the teeth must be extracted by a special protocol, to reduce the risk of ONJ. In advanced cases, major surgical procedures are necessary, involving necrotic bone removal and free bone grafts reconstruction. However there are some cases, with implant supported prosthetic rehabilitation, that are successfully completed.

Asist. Prof. Andrej Kansky DMD, University Medical Centre Ljubljana, Slovenia, dept of Maxillofacial and Oral Surgery

Fouad Ghareeb

Strategy of Nasal Reconstruction in Atypical Nasal Clefts

Objectives: To suggest a strategy for the skin coverage of the nose in atypical facial clefts choosing from different kinds of local flaps or tissue expansion.

Background: This study will spot light on atypical facial clefts affecting the nose (Tessier number 0, 1, 2 and 3) as regard different patterns and types of skin reconstruction.

Methods: This is a retrospective and short prospective study done in the department of plastic surgery Menoufia University and main author private practice from 1996 to 2014. The study included 15 patients of atypical nasal clefts. Nasal skin reconstruction was achieved by local flaps (V_Y, Z-plasty and tissue gathering) or by expansion of the forehead skin in addition to skeletal nasal reconstruction.

Results: A satisfactory outcome is achieved by judging if the local skin is adequate for local flaps or burrowing of skin from the forehead is required by expansion. Management of these cases requires good analysis of the pattern of nasal cleft and we suggest a treatment algorithm for each pattern.

Keywords: Congenital nasal clefts, atypical facial clefts, craniofacial clefts, nose reconstruction, Tessier clefts, nasal deformities.

Fouad Ghareeb, Yaser Elsheikh, Sheref alkashty, Ahmed Tharwat and Hossam Hassan

Department of Plastic surgery and burn Menoufia University

Presenting author: Fouad Ghareeb

Saturday, 8th November

13:30-14:30	SYMPOSIUM 6 - Hall B
13:30-13:50	Advanced surgical planning for the orbital apex – Kavin Andi (UK)
13:50-14:10	Anatomical guidance and fixation techniques in orthognathic surgery - Osman Etöz (Turkey)

Kavin Andi (UK)

Advanced surgical planning for the orbital apex

Recent advances in technology have armed the surgeon with a variety of tools which are applicable in the reconstruction of the orbit following ablation for cancer or high energy trauma.

I will review the surgical anatomy of the orbit and how this relates to pre-operative planning, intra-operative manoeuvres as well as surgical outcomes with a special emphasis on the navigation tools available today and what we can expect in the not too distant future.

Osman Etöz (Turkey)

Anatomical guidance and fixation techniques in orthognathic surgery

Anatomical landmarks are crucial factors affecting both surgical access and hard and soft tissue healing. While incision and fixation can be considered as the start and finish of orthognathic procedures an intentional wound is established based on anatomical guidance. The design and armamentarium of soft tissue intervention, bone cuts and fixation can be considered as crucial steps of orthognathic surgery which subsequently maintain enough healing and prevent possible complications and decrease postoperative morbidity. In this presentation it is aimed to summarize recent knowledge about anatomical guidance and fixation in orthognathic surgery.



4th Conference of BAMFS (Balkan Association of Maxillofacial Surgeons)

5-8 November 2014 - Harbiye Military Museum & Cultural Center - İstanbul / Turkey

Oral Presentations

5-8 November 2014 - Harbiye Military Museum & Cultural Center - İstanbul / Turkey

OP-01**Efficacy of Tumour Depth of Invasion as a Predictor of Pathologically Detected Neck Metastases in pT1 Squamous Cell Carcinoma of the Tongue**

Ramanan Rajamanohara, Muammar Abu Serriah, Ketan Shah, Adekunmi Fasanmade, Jennifer Graystone, Stephen Gerry, Stephen Bond
Department of Oral & Maxillofacial Surgery, John Radcliffe Hospital, Oxford, England

OBJECTIVES

Squamous cell carcinoma (SCC) of the oral tongue are associated with the tendency to spread to cervical lymph nodes. The presence of pathologically detected neck metastasis (PDNM) reduces survival by 30% to 50%, emphasising the importance of nodal status in this cohort of patients. Tumour depth of invasion (TDI) has been increasingly identified as a predictor for pathologically detected neck metastases and thus, guiding the decision for elective neck dissection. However, different investigators have arrived at different cut-off values for TDI of the oral tongue and PDNM. Further to this, although T1 tumours are considered a different disease entity from T2, most research groups have pooled these groups together for analyses and outcome reporting. The aim of this study was to investigate the association between TDI and PDNM for patients with pT1cN0 SCC of the oral tongue.

METHODS

Data was collected for 127 patients with pT1SCC of the oral tongue between August 2000 and August 2013. There were more men (58%) than women (42%) with a mean age of 61 years (range from 23 to 87 years). TDI, neurovascular invasion, pattern of invasion and presence of PDNM were recorded. The relationship between the data was studied using logistic regression and ROC methods.

RESULTS

With all other factors held constant, the odds ratio for each millimeter increase in TDI and risk of PDNM was 1.09 (95% CI: 0.95 – 1.25, $p = 0.234$, which was statistically insignificant). TDI also had poor accuracy (66% using ROC analysis) in predicting PDNM.

CONCLUSION

Our study reveals that TDI is not a reliable or accurate predictor of PDNM and should not be used in isolation to decide upon neck dissection in patients with pT1cN0 SCC of the oral tongue. Patients must continue to be managed within a multidisciplinary team setting until more suitable predictors or new approaches have been identified and robustly tested.

Keywords: Oral tongue; squamous cell carcinoma; tumour thickness; tumour depth of invasion; neck metastasis

5-8 November 2014 - Harbiye Military Museum & Cultural Center - İstanbul / Turkey

OP-02

Globe Preservation in Maxillary Tumours

Anna Sayan, Vellupillai Ilankovan

Department of Oral and Maxillofacial Surgery, Poole Hospital NHS Foundation Trust, Poole, UK

OBJECTIVES

Malignant tumours of the maxilla tend to spread to the adjacent structures. When tumour starts to involve the orbital floor with bone invasion and breaches the periosteum, the common understanding is to recommend orbital exenteration as pathway for tumour control. Loosing the eye is a mutilating experience and very rarely patients recover from the surgical trauma. This is a retrospective based study of globe preservations in maxillary tumours with maintenance of function and tumour control.

METHOD

8 patients were identified where globe was preserved. 7 were SCC and 1 malignant melanoma. In 5 patients the periosteum was breached. In 2 patients the tumour invaded the inferior rectus muscle and in 1 the tumour invaded the extraconal fat. All 8 patients were adamant to have orbital preservation. The MDT reluctantly accepted patients' choice.

RESULTS

The follow up period is 2-8 years. Five females and three males with mean age of 53 years old. One patient where the inferior oblique and rectus muscles were compromised developed persistent diplopia. The rest had normal vision with absence of diplopia.

CONCLUSION

The hypothesis is that the orbital fat appears to act like a "globe policeman" akin to the omentum which is an "abdominal policeman" in controlling tumour spread. Loosing inferior rectus appears not to affect globe motility. Hence, a blanket advice of globe exenteration in maxillary tumours needs to be questioned.

Keywords: Maxillary tumours, globe preservation, maxillectomy, orbital exenteration

OP-03

Oral Lichen Planus - Retrospective Study of 248 Patients

Esin Demir¹, Velupillai Ilankovan², Anna Sayan²

¹Department of OMFS, Selcuk University, Konya, Turkey

²Department of OMFS, Poole hospital, Poole, UK

INTRODUCTION

Oral lichen planus (OLP) is a common, chronic mucosal disease associated with a cell-mediated immunological dysfunction. The clinical manifestation is different when various forms, white and red are considered. An important complication of OLP is the development of oral squamous cell carcinoma, which led the World Health Organization (WHO) to classify OLP as a potentially malignant disorder.

OBJECTIVES

To investigate the clinical characteristics of OLP and effectiveness of various treatment modalities in a group of patients seen between 2009 february and 2014 february at Maxillofacial Department in PooleHospital.

MATERIALS- METHODS

A group of 248 patients with a diagnosis of OLP was retrospectively reviewed. Data regarding clinical type, localization, histological type, treatment and malignant transformation were registered.

RESULTS

Of the 248 lichen planus patients, 42 were erosive oral lichen planus (EOLP). 9 out of 42 EOLP had malignant transformation and developed SCC. 3 of 9 SCC died from disease.

CONCLUSION

The initial and long-term management of OLP is mainly clinical, except for mucosal biopsy specimens, which are critical to confirm OLP diagnosis and exclude malignancy. The first-line treatment of EOLP is based on topical steroids.

Keywords: Oral lichen planus, oral squamous cell carcinoma

OP-04

Retrospective Audit of Compliance with Local Guidelines Relating to Pre-Radiotherapy Haemoglobin Levels in Post-Operative Head and Neck Oncology Patients at St George's Hospital London. Are We Compliant with The Current Literature?

Martin Woods, Beejal Patel, Leandros Vassiliou, Graham Smith
 Department of Oral and Maxillofacial Surgery, St George's Hospital, London

OBJECTIVES

1. To evaluate the compliance of post-operative head and neck oncology patients with local guidelines relating to pre-radiotherapy haemoglobin levels following primary surgery.
2. To review the current literature regarding an agreed standard of post-operative, pre-radiotherapy haemoglobin levels, and compare this against our local clinical practice, with particular reference to the avoidance of anaemia related hypoxia in patients about to start post-operative radiotherapy.

METHOD

Retrospective assessment of patients under the care of the maxillofacial team at St George's Hospital London using the regional head and neck oncology MDT database.

Patients were selected on the basis of primary surgery who underwent subsequent radiotherapy or chemoradiotherapy over a three year period between August 2010 and July 2013. Selected patients were investigated to record pre-operative and post-operative Hb levels, pre-radiotherapy Hb levels, and if blood transfusion was undertaken during their post operative period.

This data was compared against the locally agreed standard of a Hb greater than 10.0 g/dL prior to primary surgery and a Hb greater than 12.0 g/dL prior to post operative radiotherapy.

RESULTS

44 patients identified.

All patients had Hb of >10.0 g/dL prior to surgery

Mean Hb on discharge prior to radiotherapy and/or chemoradiotherapy 12.25 g/dL

21 patients not compliant with Hb of >12.0 g/dL on discharge prior to radiotherapy and/or chemoradiotherapy

37 patients had Hb of >11.0 g/dL on discharge prior to radiotherapy or chemo-radiotherapy.

18 patients were transfused.

Median transfusion of 2 units, range 1 - 6 units

CONCLUSIONS

Our data demonstrates 52% compliance with our own local guideline of Hb levels >12.0 g/dL prior to commencing radiotherapy following primary surgery. 84% of patients had a Hb >11.0 g/dL prior to commencing radiotherapy.

The clinical significance of own clinical data and a summary of the current literature will be discussed.

Keywords: haemoglobin, radiotherapy, chemoradiotherapy

5-8 November 2014 - Harbiye Military Museum & Cultural Center - İstanbul / Turkey

OP-05

Tongue Ulcer Resembling Malignant Cancer in a Thalassemic Patient

Natasha Talai, Marzyeh Parvizi

Department of Oral and Maxillofacial Surgery, University Hospitals Bristol, Bristol, Uk

OBJECTIVES

We introduce a case of a 44-year-old male suffering from β thalasaemia, with a sinister looking, symptomatic tongue ulcer, clinically mimicking squamous cell carcinoma. β thalassemia results in altered production of the beta chains in the hemoglobin molecules. Presentation of β thalassemia in the Head and Neck region includes frontal bossing, depressed nasal bridge, ocular hypertelorism, hypertrophy of the jaws and proclined teeth, often leading to an anterior open bite.

The objectives of this study are to discuss the patient's presentation, investigation and management and increase awareness of this unusual case.

METHODS

This patient was thoroughly investigated to rule out malignancy. This included two biopsies, MRIs and discussions at the Head and Neck MDT. The patient was kept under clinical review for over 3 years.

RESULTS

After microscopic examination iron deposits were identified within this non-healing ulcer. No evidence of malignancy or dysplasia was seen. Repetition in MRI scans showed similar appearance of the mass within the right side of the tongue.

CONCLUSIONS

This is the first reported case of this oral presentation of thalassemia. However, the literature illustrates, similar iron deposits seen in non-healing leg ulcers (Caggati et al 2010) found in patients' with thalassemia. It is therefore believed to be an unusual oral manifestation of thalassemia.

Keywords: Thalassemia, tongue ulcer, Iron deposits

OP-06

Myxofibroma of The Jaws: Treatment Modalities and Review of the Literature

Behçet Erol¹, Seda Yılmaz¹, Emre Aytuğ², Tuğçe Biçer Aytuğ¹, Cavide Sönmez³

¹Department of Oral and Maxillofacial Surgery, İstanbul Aydın University, İstanbul, Turkey

²Department of Oral and Maxillofacial Radiology, Bezmialem Vakıf University, İstanbul, Turkey

³Department of Pathology, Bezmialem Vakıf University, İstanbul, Turkey

Odontogenic myxofibroma or myxoma is a rare and benign but locally aggressive neoplasm of the jaws. It is characterized grossly by mucoid or gelatinous grayish-white tissue macroscopically. It is thought odontogenic myxofibroma is derived from embryonic mesenchyme or ectomesenchyme. This locally aggressive tumour have potential for extensive bone destruction. The tumour may reach large size of bone destruction because of painless and slow growth and may cause delayed diagnosis. In such cases, radical reconstructive surgery including mandible resection, hemimandibulectomy or maxillectomy may be necessary. Odontogenic myxofibroma has a high risk of recurrence in conservative approach such as curettage due to its multilocular structure.

The aim of this study is to present and discuss our six cases of myxofibroma of maxilla and mandible. One of our cases, resulted widespread bone destruction involving the mandible, combination of conventional radiographic evaluation, computed tomography (CT), magnetic resonans imaging (MRI) and scintigraphic imaging were made for surgical planning of the tumour. As a result CT and MRI was found to be superior in surgical management of aggressive lesions such as myxofibroma.

Keywords: Odontogenic myxofibroma, maxilla, mandible, maxillectomy, mandibulectomy

OP-07

Composite Free Flap Reconstruction Following Stage 4 Mandibular Osteoradionecrosis

Michail Tsakalidis, Timothy Martin, Prav Praveen, Satyesh Parmar
Queen Elizabeth Hospital, Birmingham, United Kingdom

OBJECTIVES

Osteoradionecrosis (ORN) of the mandible is a well known late complication of ionising radiation therapy for malignant tumours in the head and neck region. This debilitating disease not only affects patient's well being but also presents a great challenge to the reconstructive surgeon in terms of treatment. In cases of Stage 4 ORN the preferred treatment modality is reconstruction of the diseased bone with free flaps or reconstructive plates. Various types of flaps have been described in the literature with the most common being the osseocutaneous fibula flap. Our objective is to share our experience and show the

success rate and complications we have encountered whilst treating patients with composite free flaps for Stage 4 mandibular ORN.

METHODS

The Birmingham oncology database was reviewed retrospectively to identify patients who were diagnosed with Stage 4 ORN of the mandible and who had a reconstructive surgery with a composite free flap. All patients underwent surgery at the same institution between 2005 and 2014. The collected data included patient demographics, diagnosis, smoking status, radiation dose, time elapsed between end of radiotherapy and diagnosis of ORN, cause of ORN, recipient site, donor site, complications, ORN recurrence, flap failure, post op occlusion length of antibiotic post operatively, inpatient stay, gastrostomy tube (G-tube) feed dependence, follow up time and patient survival.

RESULTS

A total of 18 patients were included, 13 males and 5 females, with a mean age of 59.11 years. 16 patients received radiotherapy alone (50-55 Gy) whilst 2 had chemo - radiotherapy (38Gy). In 10 cases ORN developed post dental extraction. A total of 14 fibulas and 4 scapulas were used. The overall success rate is 94.11%. There was 1 total flap failure (fibula). 4 patients developed a post operative infection at the surgical site prolonging the need for antibiotics and 2 patients had persistent malocclusion post operatively. None of the patients had a ORN recurrence. The mean follow up time was 27.65 months.

CONCLUSION

Composite flaps remain a reliable tool in the surgeon's armamentarium for treating a resected Radio - osteonecrosed mandible as shown by our unit's success rate of 94.11%. Despite all potential post operative complications, this treatment option provides good results in terms of restoring normal jaw function and therefore improving patient's well being.

Keywords: osteoradionecrosis, ORN, radiation therapy, ionising radiation, mandible, composite free flaps, reconstruction

OP-08

The Outcomes of CO2 Laser Treatment on Actinic and Seborrheic Keratosis Lesions: 5 Year Retrospective Audit (2009-2014)

Vellupillai Ilankovan, [Preeyan Shah](#)

Department of Oral and Maxillofacial Surgery, Poole Hospital NHS Foundation Trust, Poole, UK

INTRODUCTION

Actinic and seborrheic keratosis describes pre-malignant skin lesions, primarily caused by over-exposure to the sun. A small percentage of these lesions have the potential to develop into squamous cell carcinomas, and as a result, the majority can be treated with a variety of modalities, including ablation with a CO2 laser. CO2 lasers have been around for a number of years, and have

been shown to be an effective treatment for the management of actinic and seborrheic keratosis.

PATIENTS and METHODS

This 5 year retrospective audit looks at the outcomes of the use of CO₂ laser ablation, looking at lesion resolution and recurrence assessed clinically. Twenty patients were identified as meeting all of the inclusion criteria.

RESULTS

The results show that 95% of lesions showed resolution at the review appointment (ranging from 1 month to 5 months post treatment).

CONCLUSION

In conclusion, this audit has shown that CO₂ laser ablation is a highly effective treatment modality for these lesions, with a low percentage of recurrence post treatment. It is our opinion that this treatment would be more acceptable to patients compared to topical agents, which have more side-effects and are reliant on patient compliance.

Keywords: The outcomes of CO₂, laser treatment on actinic, seborrheic keratosis lesions

OP-09

Marsupialization of the Jaw Cysts in Children: Case Series

Gökhan Gürler¹, Aslı Patır Münevveroğlu², Çağrı Delilbaşı¹, Emrah Dilaver¹, Serdar Yılmaz¹

¹İstanbul Medipol University School of Dentistry Department of Oral and Maxillofacial Surgery

²İstanbul Medipol University School of Dentistry Department of Pediatric Dentistry

Marsupialization has been widely used and is beneficial for the treatment of cysts in the children and adults. Important outcomes of marsupialization include the ability to preserve adjacent anatomy and the low morbidity compared with other invasive treatment options. We present case series of marsupialization of the jaw cysts in five children age range 10 to 12 years. Cystic lesions were diagnosed as dentigerous cyst in four children, whereas bilateral odontogenic keratocyst was diagnosed in one child. We observed gradual resolution of cystic lesion and eruption of adjacent impacted teeth at the end of the treatment.

Marsupialization is effective for the treatment of cystic lesions in growing patients as it preserves vital anatomical structures and it enables eruption of teeth as observed in our cases.

Keywords: jaw cyst, marsupialization, treatment

OP-10**Comparative Analysis of 3-Years Results of a Pterygoid Approach: Isoelastic PEEK-PERSON-C Implants and Titanium Screw Implants to Avoid More Invasive Implant Procedures in the Atrophic Maxilla**

Alexander Bagdasarov, Alexey Drobyshev

Department of Maxillofacial Surgery, Moscow State University of Medicine and Dentistry, Moscow, The Russian Federation

The pterygomaxillary region is used for implant placement in maxilla. The advantages as hard bone structures, almost free of spongy tissue, are used to avoid invasive surgical procedures against the maxillary obstacles such as sinus lift with 7 to 15% of side effect. (1) PEEK-OPTIMA is described to be isoelastic with cortical bone, which is especially beneficial near the cranial sutures. Furthermore, it shall be possible to work out the shapable PEEK to a monoblock –implant.

In our study we compare 18 implantations in 13 patients with Ti-screw implants and 20 implantations in 15 patients with the PEEK-PERSON-C implant. Titanium pterygoidean implants in literature present benefits over all other technics using a cascade of more invasive procedures with higher failure mean rate of 91,8% (2).

We examined the pterygoidean implants in 38 operation sites in 3 years period. The reported success rate for titanium pterygoidean implants are rather high and do not differ from implantation in sufficient alveolar bone structures (97%). Our PEEK implants had a success rate of 95% over a period of 3 years in function.

The reported success rate for titanium and PEEK pterygoidean implants are rather high like as reported for sufficient alveolar bone structures and do not differ from our findings in 38 cases implantation (97 %, 95%). However PEEK we now prefer over metal implants as it is easier to be personalized and also it's isoelastic to cortical bone around the important osteopathic "central line" touching the sphenoid area.

Keywords: PEEK implants, pterygoidean implants, sphenoid area, cranial sutures, maxilla atrophy

5-8 November 2014 - Harbiye Military Museum & Cultural Center - İstanbul / Turkey

OP-11

Buccal Bone Remodeling after Immediate Implant Placement with and without Grafting

Shereen Wagdy Arafat, Maggie Ahmed Khairy

Department of Oral Surgery, Faculty of Dentistry, Modern science & Art (MSA) University, Cairo, Egypt.

OBJECTIVE

Recent studies have shown pronounced resorption of the buccal bone plate after immediate Implant placement. The use of bone graft in the gap between implant and buccal bone plate was advocated to minimize buccal bone resorption and to favor osseointegration. The aim of this study was to evaluate remodeling of the buccal bone plate following immediate implant placement with and without grafting.

METHODOLOGY

Twenty four single rooted maxillary teeth in 18 patients were selected for this study and were scheduled for tooth extraction and immediate implant placement. 12 implants were placed without grafting (control group), and 12 implants were placed while the gaps between implant and buccal bone were grafted using Bio-Oss mixed with Platelet Rich Fibrin PRF (test group). All sites selected showed buccal gap >2mm. All implants included in this study were 1-stage implants placed at level of palatal bone. Subsequently, Cone Beam CT was taken to measure the linear distance between the implant surface and the buccal socket wall and to measure the buccal crestal bone height immediately after placement, at 6 and 12 months postoperatively. Consequently a mean of the measurements was calculated and included into further statistical analysis

RESULTS

After 6 and 12 months, Test group showed statistically significantly higher mean linear distance from implant to buccal wall of the socket than control group. The mean linear distance in test group was 3.1, 2.7, 2.5 mm at 0, 6, 12 months respectively. while in control group it was 3.1, 1.5, 1.4 mm at 0, 6, 12 months respectively. The test group showed 13.8 %, 19.7% mean reduction of the linear distance from implant to buccal socket wall from 0-6 months and from 0-12 months post-operatively. While the control group showed 50.7% and 54.5 % mean reduction of the linear distance from 0-6 months and from 0-12 months postoperatively. Regarding the crestal bone height, it showed non significant differences between both groups at the study intervals.

CONCLUSION

Data from this study showed that after tooth extraction and immediate implant placement, the buccal bone plate underwent significantly less horizontal bone resorption with grafting of the peri-implant gaps, while more buccal bone resorption occurred when the peri-implant gap left non-grafted. Moreover, the buccal crestal bone resorption showed non significant difference between

grafting and non-grafting of the peri-implant gaps. These findings suggested more favorable and statistically significant outcomes in terms of grafting the peri-implant gaps regarding the buccal bone remodeling.

Keywords: immediate implant, bone graft, bone regeneration, PRF, Bio-Oss.

OP-12

New Generation Platelet Concentration (A-PRF) Effects on Bone Formation in Standard Bone Defects: Animal Study

Kübra Titirli¹, Ismail Doruk Koçyiğit¹, Fethi Atıl¹, Umut Tekin¹, Burcu Şengüven²

¹Department of Oral and Maxillofacial Surgery, Kırıkkale, Turkey

²Gazi University, Dentistry Faculty, Oral Pathology Department

OBJECTIVE

The major aim of biomaterial research is to promote a material-induced tissue reaction which leads to regeneration and an effective wound healing process in the defected area. A biomaterial should serve as a temporary barrier to cover defects and promote tissue regeneration. The aim of this histologic study was to compare the efficacy of two different blood concentration PRF and A-PRF, on bone regeneration in surgically created standart bone defects.

METHODS

Choukroun's PRF (platelet- rich fibrin) and A-PRF (Advanced platelet rich fibrin are obtained from blood without adding anticoagulants. In this study, protocols for standard platelet-rich fibrin (S-PRF) (rpm2700, 12 minutes), and A (advanced)-PRF (rpm 1500, 14 minutes) were compared. The study included 20 New Zealand species of the Oryctolagus genus experimental rabbits (age;9-12 months). In each mandibula, 1 monocortically defect 4.5 mm in width and 2mm depth were prepared with a trephine burr under saline solution irrigation at 1500 rpm. PRF applied to one side and other side filled with A-PRF at the sime time and one non-treated defect was created as a control group.

RESULT

Histopathologic results were evaluated 2 months postoperatively. None of the groups displayed any signs of necrosis. Inflammation was observed in all groups. New bone formation and the evaluation of the defects were analyzied and compared with each other. Autogenous blood cocentrations and their effects to the bone formation were also discussed in the light of the literature.

Keywords: aprf, prf, blood, bone, defect

OP-13

Review about Tissue Engineering in Oral Surgery

Ali Hanttash Abu Hanttash, Ümit Kamal Aktaş
Department of oral surgery, Ankara university

OBJECTIVES

review the technology of tissue engineering and its current and future applications within the oral surgery, and discuss contemporary obstacles yet to be overcome and trying to inform the most updated information on tissue engineering and its potential applications in oral surgery.

METHODS

review the literature written in English and published from the beginning of tissue engineering until today. full text articles were used to identify how the tissue engineering emerges, different strategies of tissue engineering, bio materials employed for this purpose, the major attempts to engineer different oral structures, finally challenges and future of tissue engineering in dentistry.

RESULTS

The field of tissue engineering has developed over the past decade to re-create functional, healthy tissues and organs in order to replace diseased, dying, or dead tissues. As they relate to the oral surgery apparatus, hard and soft tissue defects secondary to trauma, congenital defects and acquired diseases are a significant health problem.

Tissue engineering strategies representation of three different tissue engineering approaches: conductive, inductive, and cell transplantation. In tissue engineering, combinations of the three elements scaffolds, cells, signaling molecules like growth factors with time and appropriate environment will make it possible to regenerate tissues or organs. Tissue engineering is a rapidly advancing discipline that combines the attributes of biochemical and biomaterial engineering with cell transplantation to create bio-artificial tissues and organs.

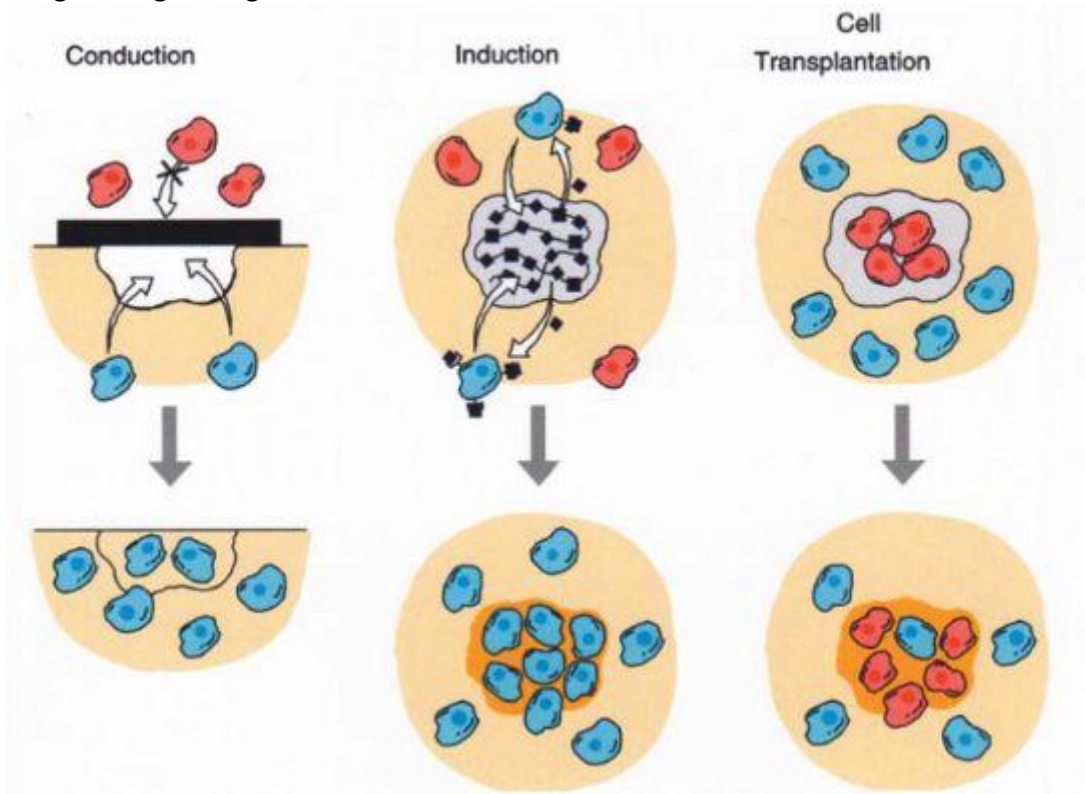
CONCLUSION

The usage of stem cells systems as a tool for tissue engineering has great potential. Stem cell research has resulted in many clinical applications. Examples of cell based therapies include repair of skin, bone, articular cartilage, cardiac tissues and neuronal tissue in Parkinson's disease.

the concepts of tissue engineering will greatly contribute not only to the oral surgery but also to other important organ reconstructions in the future. Tissue engineering, which aims to create tissue-matched, prefabricated, prevascularised bony or soft tissue composite grafts, or both, therefore has the potential to revolutionise practice in oral surgery

Keywords: Tissue engineering, Dental stem cell, Guided tissue regeneration

Tissue engineering strategies



OP-14

Alveolar Ridge Preservation with Free Gingival Graft in the Anterior Maxilla: A Cone-Beam Computed Tomography Study in Humans

Çiğdem Karaca¹, Nuray Er¹, Ayşe Gülşah², Osman Taha Köseoğlu¹

¹Department of Oral and Maxillofacial Surgery, Hacettepe University, Ankara, Turkey

²Department of Oral and Maxillofacial Radiology, Başkent University, Ankara, Turkey

OBJECTIVES

The aim of this study was to evaluate the effect of using free gingival graft to preserve alveolar ridge dimensions following tooth extraction in the aesthetic zone after 3 months of healing.

MATERIALS-METHODS

Ten subjects with at least two maxillary anterior teeth scheduled for extraction were selected for this study. Atraumatic extractions were performed. Two maxillary teeth were allocated to a test or a control group. In the test group, the extraction socket was covered with free gingival graft harvested

5-8 November 2014 - Harbiye Military Museum & Cultural Center - İstanbul / Turkey

from palate while in the controls the sockets healed spontaneously. CBCT scans were taken from the patients at the day of extraction and at 3 months following teeth extractions.

RESULTS

The soft tissue healing of the extraction sockets were visually assessed by inspecting clinically. Hard tissue measurements were obtained to measure the CBCT scans. After 3 months of healing, control sockets lost the height of the buccal and lingual crestal bones (-1,03 mm and -0,56, respectively) although the test sites covered with the free gingival graft gained the height of the buccal and lingual crestal bones (+0,06 mm and +0,25 mm, respectively). This difference between two groups found statistically significance ($p < 0.05$). On the other hand, both test and control groups lost the width of the buccal and lingual crestal bones. This difference between control and test groups did not reach statistically significant ($p > 0.05$).

CONCLUSION

The results of this study confirmed that covering the orifice of the extraction sockets with only free gingival graft can be accepted as an applicable ridge preservation technique. However, it is needed further reports to clarify the role of the free gingival graft as an alveolar ridge preservation technique.

Keywords: extraction socket healing, alveolar ridge dimension, alveolar ridge preservation, free gingival graft, cone-beam computed tomography

OP-15

Clinician and Patient Perceptions of the Risks Of Waterpipe Smoking

Yusuf Gadiwalla, Naran Thanabalan, Chris Sproat
Guy's Hospital, London

OBJECTIVES

Primarily this study investigated if dentists are aware of waterpipe smoking, its associated risks and how confident they are in providing cessation advice. The secondary aim examined the popularity of waterpipe smoking among our patient base and risk awareness. The tertiary aim was to provide clinician focused education and creation of evidence based local guidelines to aid dentists when giving waterpipe smoking cessation advice.

METHODS

A literature search was conducted in Ovid MEDLINE from 1950 to 2014 using the search parameters "shisha" "sheesha" "waterpipe" "hookah" "hubbly bubbly" "nargile" to investigate the available literature on the risks of waterpipe smoking. Evidence from the literature search helped us establish local guidelines to aid cessation advice.

Forty six clinicians completed a questionnaire based survey of the perceived risks of waterpipe smoking and their levels of confidence in providing cessation advice. In addition, 394 patients

completed anonymous surveys about the use of waterpipe smoking and associated risk awareness.

RESULTS

Ninety one percent of clinicians were aware of waterpipe smoking and 80% felt they knew the associated risks. However, 26% were unsure if it was worse than cigarette smoking and 63% of dentists reported they would not be confident in giving waterpipe smoking cessation advice. Of 394 patients 3.6% were waterpipe users but 57% of those would not consider themselves as smokers. 64% of these patients thought waterpipe smoking was less harmful than cigarette smoking and 57% felt it was their dentists' responsibility to inform them of the risks of smoking.

CONCLUSION

Waterpipe smoking is increasing in popularity however the dangers are not widely known. It was evident that both clinicians and patients require clear evidence based information regarding the risks of waterpipe smoking. In addition, further studies are needed to help prove conclusively that waterpipe use is harmful to the users' health.

Keywords: Educational

OP-16

Audit of Delay in Oral and Maxillofacial Surgery operations in the Emergency Theatres in a Major UK District General Hospital

Tun Wildan, Sajni Shah, Maryam Azizi, Mo Shorafa

Regional Maxillofacial Centre, North West London Hospitals Trust, Watford Road, Harrow, UK HA1 3UJ

OBJECTIVE

An audit was performed to determine the delay in getting Oral and Maxillofacial Surgery (OMFS) patients to the shared Emergency theatres in a major UK District General Hospital. OMFS is one of the many surgical specialities that is involved with non-elective work in the National Health Service (NHS). Any delay in emergency oral and maxillofacial operations will inevitably increase the burden on acute hospital services and compromise the quality of care given to patients.

METHODS

Data of all OMFS patients operated in the Emergency Theatres at a major UK District General Hospital from April 2014 to June 2014 were collected from the Emergency Theatres operation records. The collected data included the total number of OMFS emergency patients, along with the type of cases, and any delays to theatres. Patients who are operated beyond the following day of decision to operate, would be considered as a delay.

RESULTS

133 OMFS patients were operated during this 3 month period in the Emergency Theatres. Of these,

5-8 November 2014 - Harbiye Military Museum & Cultural Center - İstanbul / Turkey

49 were for mandible fractures, 48 for cervicofacial abscesses, 21 for closure of facial lacerations and the rest for retrobulbar haematoma evacuation, free flap salvage, and for relocation of dislocated condyle. There were 14% cases of delays in April, 10% in May and 2% in June 2014. The longest delay was being operated on the 4th day after being admitted. The most common cause for the delay was the lack of availability of an emergency theatre slot due to sharing theatres with other surgical specialties and lack of operating out of hours (after 8pm) facility for non life or limb threatening procedures.

CONCLUSION

Delays on getting patients to theatres can result in increased patient discomfort and deterioration of the patient's clinical condition. There seems to be a reduction in the delay to theatres from April 2014 to June 2014. This may be due to improved communication between the theatre staff and the OMFS team with the introduction of the morning theatre briefing to prioritise cases, and the availability of a second OMFS registrar to perform the cases in the second emergency theatres that are opened up between the hours of 5pm until 8pm. OMFS emergency cases were also performed in the OMFS elective and Orthopaedic Trauma lists, apart from emergency theatres.

Our target is now to comply with the National Confidential Enquiry into Patient Outcome and Death guideline to treat patients within the preferred time frame.

Keywords: delays in emergency theatres, oral and maxillofacial surgery

OP-17

Use Of Internet by Patients to Access Healthcare Information Focusing on Apicoectomies

Marzyeh Parvizi, Natasha Talai, Zeinab Parvizi

Department of Oral and Maxillofacial Surgery, University Hospitals Bristol, Bristol, UK

OBJECTIVE

Today, the challenges of pseudo-medicine and infectious disease have given their place to other threats to the power of the medical profession. In particular, information technology (IT) has provided the medical profession with serious challenges in the arenas of professional dominance, autonomy and self regulation.

The Oxford Internet study conducted by Dutton and Blank in 2013, shows 78% of the UK population over the age of 14 using the internet, of which 69% use it to access health related information. The objectives of this study are to review the information readily available to patients on the internet for apicoectomy and to assess their quality using the DISCERN tool.

METHODS

The Google search engine was accessed on 20th March 2014 using the terms "apicoectomy", "endodontic microsurgery" and "root end surgery". Two dentally qualified reviewers with good

scientific understanding of apicoectomies and similar clinical experience independently hand-searched the first seven pages of the results yielded by Google. Any sponsored links, news articles, video feeds, discussion groups and duplicate sites were excluded from the study. The DISCERN tool was then used to assess the quality of the online information on apicoectomy by both reviewers independently.

RESULTS

The Google search engine generated 47300 links for “endodontic microsurgery”, 312000 for “apicoectomy” and 7560000 for “root-end surgery”. However, only 15 websites met the study criteria from the first 7 pages of the links generated by the search engine. Out of the maximum 75 points, the mean DISCERN score was 39.8 (\pm SD 7.25), indicating ‘fair’ content quality. The highest DISCERN score was 52.5 achieved by the Colgate website and the lowest score was 28.5 achieved by the Wikipedia website. Of all the websites rated, only 6.67 percent were found to be ‘good’, 46.67 percent were ‘fair’ and 46.67 percent were of ‘poor’ quality.

CONCLUSION

The results of this study indicate that the number of high-quality websites are limited and almost half of the websites were found to be of ‘poor quality’. The DISCERN questionnaire was found to be a useful tool as it provided us with an objective and validated measure for assessing quality of the online information on apicoectomy.

Given the increasing proportion of patients using the Internet, it is important to have a thorough consent process to ensure all misconceptions are dispelled. In addition, a greater awareness of the quality of information available to patients is needed to direct patients to validated resources.

Keywords: Apicoectomy, DISCERN, endodontic microsurgery, root end surgery

OP-18

The Use of a Mobile Internet Application to Improve Eye Examinations in Maxillofacial Trauma - Limitations and Potential Improvements

Thomas E Howe¹, Iain Varley²

¹Sheffield Teaching Hospitals NHS Trust, Sheffield, UK

²University of Sheffield, UK

Clinical notes for patients with surgically-treated zygoma fractures over a three-month period were reviewed. The documentation of examination of the eye was evaluated. Several areas were noted to be deficient, and a mobile-web application was designed to assist in the examination and documentation process with specific regards to these areas. The application was demonstrated to maxillofacial staff involved in the acute assessment of injured patients with zygomatic fractures, and they were encouraged to access and use it via their personal smart phones. A further review of records was carried out 3 months following introduction of the application. Recording of eye examination in traumatised patients improved, but focus-group discussions of participants revealed that the mobile application may have had little impact, and any improvement seen likely reflected

5-8 November 2014 - Harbiye Military Museum & Cultural Center - İstanbul / Turkey

the initial training when the mobile-web application was first demonstrated. Reasons for this, aspects of mobile application design and potential improvements are discussed.

Keywords: Trauma, zygoma, eye, mobile application

OP-19

Improving Standards of Operative Record Keeping in Oral & Maxillofacial Surgery: A Closed Loop Audit

Ramanan Rajamanohara, Nadeem Saeed

Department of Oral & Maxillofacial Surgery, John Radcliffe Hospital, Oxford

OBJECTIVE

Record keeping is a vital means of communication between professionals to ensure the highest standards of patient safety. This audit compared current practice in operative note keeping with the Royal College of Surgeons of England, Good Surgical Practice Guidelines (2008).

METHOD

50 operative notes were audited against the 16 criteria set by the guidelines, for both elective and emergency procedures, in Oral & Maxillofacial Surgery theatres. The intervention of a poster highlighting criteria of the guidelines was then placed over the operative note-recording desk in theatres with a supplementary educational presentation. A subsequent re-audit was undertaken of a further 50 operative notes.

RESULTS

The results of the initial audit cycle showed that much of the data was not recorded when compared to Royal College of Surgeons criteria. With the intervention introduced a significant improvement was made in 11 out of the 16 criteria tested and an improvement in total data recorded increased from 57.8% to 71.6% ($p < 0.05$).

CONCLUSION

This study shows statistical evidence that the introduction of checklist poster with complementary education will objectively improve the recording of operative notes and promote good surgical practice. Despite the improvement in record keeping outcome there is still scope for improvement in future through electronic record keeping.

Keywords: Note keeping; quality improvement; audit; patient safety

OP-20

The Impact of Facial Surgery Provided on Surgical Missions in Ethiopia

Andrew Owen Jenkinson¹, Mark McGurk², Mathew Fell³, Vinod Patel²

¹Cardiff University

²Guys Hospital, London

³Bristol university

The long term consequences of facial surgery performed on medical missions in developing countries is largely unknown. The review of patients is often deemed too difficult to attempt. This research team overcame the perceived practicalities to review postoperative patients in rural Ethiopia.

OBJECTIVES

This project aimed to investigate the surgical and social outcomes of patients treated by a team of visiting European surgeons 12 to 24 months after a surgical intervention has been performed. The principal aim was to answer the question 'do short term surgical missions providing facial surgery have a positive impact upon patient's lives?'

METHOD

Semi structured interviews were recorded to assess the patient's attitudes towards their preoperative and postoperative appearance. This method was also employed to assess the functional and social changes experienced by the patients. The interviews were conducted in English and translated into the patient's language by a local translator. A physical examination was performed to determine if complications or recurrence of tumours were present. A review of the medical notes was conducted to ascertain a diagnosis and identify any surgical complications. A structured assessment of the patient photographs by the visiting surgical team was performed, recording their subjective assessment of appearance pre and postoperatively. An Ethiopian lay person assessment of the preoperative and postoperative photographs was also performed to record a subjective aesthetic score, recorded as a visual analogue scale.

RESULTS

36 of the 64 eligible patients invited for interview were reviewed. 97% of patients reported an improvement in appearance, with 94% stating an improvement in function and 94% stating an improvement in their quality of life. Social isolation was identified in 63% prior to surgery and 8% following surgery. The surgeon's assessment of change in appearance triangulated well with the patients' perspective however the Ethiopian lay public assessment did not.

CONCLUSIONS

This review provides evidence that short term missions providing facial surgery in the developing world have a positive impact on the lives of those treated.

5-8 November 2014 - Harbiye Military Museum & Cultural Center - İstanbul / Turkey

Keywords: developing world, noma, outcomes, medical missions

OP-21

Alterations in Maxillary Sinus Volume among Oral and Nasal Breathers

Kamil Serkan Ağaçayak¹, Belgin Gülsün¹, Mahmut Koparal², Yusuf Atalay³, Orhan Aksoy⁴, Özkan Adıgüzel⁵

¹Department of Oral and Maxillofacial Surgery, School of Dentistry, University of Dicle, Diyarbakır, Turkey

²Department of Oral and Maxillofacial Surgery, School of Dentistry, University of Adıyaman, Adıyaman, Turkey

³Department of Oral and Maxillofacial Surgery, School of Dentistry, University of Afyon Kocatepe, Afyon, Turkey

⁴Department of Orthodontics, School of Dentistry, University of Dicle, Diyarbakır, Turkey

⁵Department of Endodontics, School of Dentistry, University of Dicle, Diyarbakır, Turkey

BACKGROUND

Mouth breathing causes a lot of changes on the facial anatomical structures in adult patients. In this study we aimed to determine the effects of mouth breathing for a long time (>5 years) on the maxillary sinus volumes among adult male patients.

MATERIAL-METHOD

Totally 586 patients were present in records who had underwent CBCT for some reasons in between September 2013 and April 2014. Patients who had underwent Cone-beam dental volumetric tomography scans for various reasons and who had answered a questionnaire about breathing were screened, retrospectively. Cone-beam dental volumetric tomography (I-Cat, Imaging Sciences International, Hatfield, PA, USA) was used to take the images of maxillo-facial area at a setting of 120 kVp and 3.7 mA. This study was carried on male patients older than 21 years of age.

RESULTS

Totally 239 male patients were included in the study. Among those, 68 were oral breathers and 171 were nasal breathers. The mean age of the oral breather men were 48.4 years and that of the nasal breather men were 46.7 years and the difference was not statistically significant ($p>0.05$). The mean maxillary sinus volumes of the oral and nasal breathers were 9043.49 ± 1987.90 and 10851.77 ± 2769.37 , respectively and the difference in maxillary sinus volume between 2 groups was statistically significant ($p<0.001$).

CONCLUSION

The volume of maxillary sinus in mouth breathers (>5 years) was significantly lower than nasal breathers. Nevertheless it remains unclear whether it is because of unsuitable functioning of nasal cavity or due to the underlying pathological condition.

Keywords: Mouth breathing, maxillary sinus, Cone-Beam Computed Tomography, Imaging Three-Dimensional

OP-22

Cone-Beam Computed Tomography Findings of Zoledronic Acid and Teriparatide Administration

Nilüfer Ersan¹, Alper Sinanoğlu², Dilhan İlgü¹

¹Yeditepe University Faculty of Dentistry - Department of Dentomaxillofacial Radiology and Oral Medicine Clinic

²Kocaeli University Faculty of Dentistry - Department of Oral and Maxillofacial Radiology, Oral Diagnosis Clinic

OBJECTIVE

It has been reported that zoledronic acid administration is associated with bisphosphonate-related osteonecrosis of the jaws. The objective of this study was to evaluate the effects of zoledronic acid (ZA) and teriparatide (TP) on extraction socket with cone beam computed tomography (CBCT).

MATERIAL-METHODS

The study was conducted on images acquired from 24 Sprague-Dawley rats. Animals were divided into three groups: I— administered with ZA (n=8); II—administered with ZA and TP (n=8); III—control (n=8). A week after a 8-week ZA injection period, rats underwent extraction of the left first mandibular molar. Following a four-week period, TP was administered to the ZA+TP group for 28 days. Upon killing, extraction sockets were examined clinically and radiologically with CBCT.

RESULTS

Clinical examination revealed mucosal ulceration, abscesses, fistula formation or necrotic bone exposure in none of the animals. The weight of the animals prior to sacrificing was higher for the control group. Radiological examination performed with CBCT showed that alveolar bone width as a result of periosteal reaction was higher in the ZA and ZA+TP groups. In most of the animals in group ZA and group ZA+TP, osteolytic changes were found in the extraction socket area. **CONCLUSIONS:** Our data indicate that ZA and TP administration increases the periosteal reaction and periosteal reaction is a common radiological finding for bisphosphonate-related osteonecrosis of the jaws.

Keywords: bisphosphonate-related osteonecrosis of the jaw, zoledronic acid, teriparatide, cone beam computed tomography, periosteal reaction

OP-23**Minimally Invasive Surgery in the Management of Parotid Stones**

Meera Samani¹, Alexander Hills², Adam Holden², Chang Bon Man², Mark Mc Gurk²

¹Oral Surgery Department, Guy's Hospital, London, UK

²Oral and Maxillofacial Surgery Department, Guy's Hospital, London, UK

OBJECTIVE

To present results of minimally invasive endoscope assisted surgery for large parotid stones.

METHOD

Between 2003 and 2013 92 (56 males, 36 females) patients seen at Guy's Hospital salivary gland unit were identified for minimally invasive surgical removal of parotid stones. Criteria for surgery included stones greater than 8mm in size, failed lithotripsy, infected glands unsuitable for lithotripsy or stones where delivery was blocked by proximal stricture. Patients were assessed preoperatively both clinically and with a combination of ultrasonography, sialography and plain radiography. Endoscope assisted stone retrieval was carried out intra-orally or extra-orally via a pre-auricular incision. Operative details were recorded. Outcome was assessed clinically based on obstructive symptoms.

RESULT

In the study population, 81% had 1 stone, 19% had two stones. Average stone size was 8mm (range 3-18mm). 15% of stones were identified in the distal third of the duct, 22% in the middle third, 15% in the proximal third, 39% in the hilum, 5% in the gland parenchyma, 2% in an accessory duct and 2% in the surrounding subcutaneous tissue. In 97% of cases the stone/s were retrieved. In 3 cases a mucous plug was identified. Intra-operative complications were uncommon with one buccal branch of the facial nerve transacted with no apparent effect. In the intermediate postoperative period, 3% had infection and 10% had sialoceles. There were no cases of facial nerve injury.

CONCLUSION

Minimally invasive surgery is an effective approach to large parotid stones or those not amenable to lithotripsy or basket retrieval. This study demonstrates that the occurrence immediate and long term post operative complications are low.

Keywords: Minimally Invasive Surgery, Calculi, Parotid

OP-24

Advanced Bone Surgery: Piezosurgery in Cranio-Orbito Facial Area & Oral Surgery

Stefano Mandrioli¹, Giovanni Elia², Luigi Clauser³

¹Stefano Mandrioli: Department of Maxillo-Facial Surger, Sant. Anna Hospital and University, Ferrara, Italy

²Giovanni Elia: Department of Maxillo-Facial Surgery, Sant. Anna Hospital and University, Ferrara, Italy

³Luigi Clauser: Department of Maxillo-Facial Surgery, Sant. Anna Hospital and University, Ferrara, Italy

OBJECTIVE

Piezosurgery represents an innovative technique as it offers the maxillofacial surgeon the opportunity to make precise bone cuts without damaging the soft tissue, minimizing the invasiveness of the surgical procedure, and the opportunity of working in a field which is almost totally blood free.

METHODS

Piezosurgery is part of the new Technologies and an useful tool used for osteotomy and osteoplastic repair in all the fields of cranio maxillo facial surgery. In our experience with 424 cases in 7 years, Piezosurgery has enabled us to perform precise osteotomy lines, micrometric and curvilinear with absolute confidence, particular in close proximity to vessels, nerves and other structures such as the dura mater, periorbits, orbital adnexae, mucosae. The degree of injury is lower than when using conventional tools.

RESULTS

Preservation of the original bony structure, especially of the cancellous bone, will benefit the bone healing process due to its high osteogenic potential. This circumstance might have clinical consequences in particular concerning the velocity of Distraction Therapy in Cranio & Maxillofacial Surgery.

CONCLUSIONS

The use of a piezoelectric device to perform this kind of surgery provides clinical and surgical results which would be difficult with traditional instruments, not only for the patient's benefit but also the surgeon's practice.

Keywords: Piezosurgery, Osteotomy, Micrometric, Maxillofacial

OP-25

Effects of Graft Augmentation Combined with Erythropoietin on the Regeneration and Vascularization of Calvarial Bone Defect

Nurettin Diker¹, Hande Sarıcan², Azize İpek Yetişt², Alev Cumbul³, Ertugrul Kılıç²

¹Department of Oral and Maxillofacial Surgery, Baskent University, Ankara, Turkey

²Department of Neuroscience, Istanbul Medipol University, Istanbul, Turkey

³Department of Histology and Embryology, Yeditepe University, Istanbul, Turkey

INTRODUCTION:

Apart from its hematopoietic function, previous studies stated that EPO exhibits cyto-protective activity in brain, spinal cord, heart and bone tissue. Tissue protective effects of EPO is mainly due to its antiapoptotic and anti-inflammatory effects. Recent experimental studies revealed that EPO is capable to enhance tissue healing via mechanisms, including cell proliferation and angiogenesis stimulant effects. Here, we examined the effects of EPO administrated alone or in combination with xenogenic bone grafts on the bone regeneration and vascularization.

MATERIAL-METHODS

Eleven adult, male, Sprague-Dawley rats were randomly assigned for one of four groups. The combination of rompun-zoletil anesthetics was used to induce general anesthesia. For surgical procedures animals were fixed by stereotactic frame. Then rats were subjected to bilateral 5 mm critical size bone defects on the calvarium. The animals were treated with an intraperitoneal injection of (i) vehicle; (ii) EPO (500IU/kg/day) alone or in combination with xenogenic bone grafts(iii; iv). The animals were treated with graft or EPO just after bone injury. EPO treatment was continued for 4 weeks (28 days). After formaldehyde perfusion and 4 weeks decalcification procedures, new bone formation and neovascularization were evaluated by hematoxylin-eosin and Masson trichrome staining. Differences between groups were analyzed by one-way ANOVA.

RESULTS

Our data indicated that graft augmentation improved bone formation and vascularization significantly in both vehicle or EPO treated groups ($p < 0.05$). However, EPO treatment potentiated the effects of graft replacement treatment on the bone formation and vascularization more significantly ($p < 0.01$). Notably that the potent effect of EPO was observed especially in the vascularization, which is most important part of tissue regeneration.

CONCLUSION

We provide evidence that as a growth factor EPO potentiates the regenerative processes after bone injury, which indicates that EPO may be used as an adjuvant treatment after graft transplantation.

Keywords: erythropoietin, angiogenesis, bone healing, calvarial defect, xenograft

5-8 November 2014 - Harbiye Military Museum & Cultural Center - İstanbul / Turkey

OP-26

The Effect of Osteotomy Technique on the Primary Stability of Implants Simultaneously Inserted in Maxillary Sinus Grafted Sites

Maggie Ahmed Khairy¹, Mohammed Elsholkamy², Alshaimaa Ahmed Shabaan¹

¹Oral & Maxillofacial surgery Departement, Faculty of dentistry, MSA University, Cairo, Egypt

²Oral & Maxillofacial Surgery, Faculty of Dentistry, Suez Canal University, Egypt

BACKGROUND

The Primary stability has been regarded as perquisites for osseointegration of dental implants. The primary determinants of the primary stability are the surgical technique used, the design of the implant, and the mechanical properties of the bone tissues. A high degree of primary stability is important in areas of soft bone where implant failures are more likely. OBJECTIVE: The aim of this study was to compare the primary stability of implants placed by conventional drilling technique and bone expanders technique in maxillary sinus grafted sites and to evaluate the level of correlation between resonance frequency analysis (RFA), and bone density.

PATIENTS & METHOD

Twenty nine patients had received a sinus floor elevation with simultaneously inserted implants. The sinus floor elevation was performed through a lateral window osteotomy. The implant sites were prepared randomly using either bone expander technique (test group) or the conventional drilling technique (control group). For each implant resonance frequency analysis values were measured using resonance frequency analysis (RFA) at the time of implant placement. The bone density around the implants was measured from immediately postoperative radiographs.

RESULTS

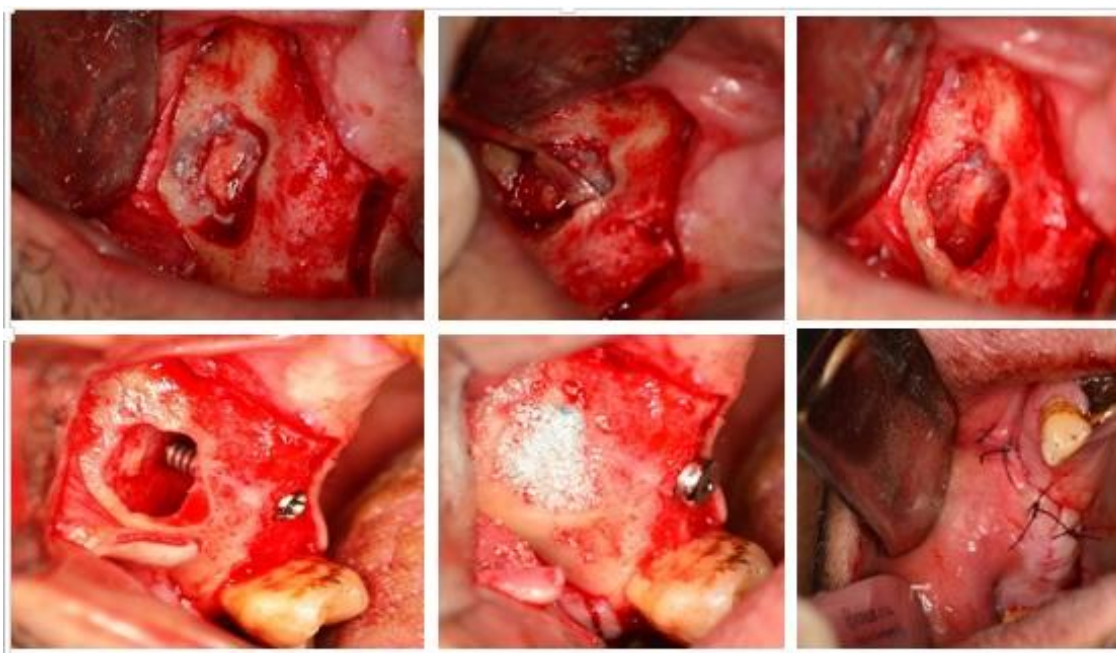
RFA demonstrated a statistically significant higher primary stability for implants in the bone expander group (test group) than that of the conventional group ($p < 0.001$) at the time of implant insertion. Also the bone density showed a statistically significant difference between the two groups ($p=0.008$). However there was no correlation between the RFA and the bone density.

CONCLUSION

The bone expander technique yielded higher primary stability than conventional drilling technique. However there was no correlation between the RFA and the bone density.

Keywords: primary stability, sinus floor elevation, bone expander technique, conventional drilling techniques, RFA, bone density.

sinus lift procedure



Results of Pearson's correlation coefficient for the correlation between bone density and implant stability (ISQ)

	Group I	P-value	Group II	P-value
Bone density (Pre-operative) and ISQ	0.393	0.087	0.071	0.767
Bone density (Post-operative) and ISQ	0.261	0.267	0.298	0.202

OP-27

Manual Lymph Drainage Efficiency in Reducing Pain, Swelling and Trismus in Diabetes Mellitus Patients Following Mandibular Third Molar Surgery

Arben Murtezani¹, Shefqet Mrasori², Visar Bunjaku³, Zana Agani⁴, Vančo Spirov⁵, Oliver Dimitrovski⁵

¹"Zahnärztliche Tagesklinik" Private Dental Clinic; Prishtina – Republic of Kosovo

²University Dental Clinical Center of Kosovo; Conservative Dentistry and Endodontics Clinic, Prishtina, Republic of Kosovo

³University Dental Clinical Center of Kosovo; Periodontology and Oral Disease Clinic, Prishtina, Republic of Kosovo

⁴University Dental Clinical Center of Kosovo; Oral Surgery Clinic, Prishtina, Republic of Kosovo

⁵University Dental Clinical Center "St Panteleimon"; Oral Surgery Clinic, Skopje, Republic of Macedonia

OBJECTIVES

To assess the impact of Manual Lymph Drainage (MLD) combined with cryotherapy and medication on Diabetes Mellitus patients' following Mandibular Third Molar Surgery in an investigative comparative-efficiency study.

MATERIAL-METHODS

The extraction of wisdom teeth in diabetic patients is frequently associated with severe postoperative edema, pain and trismus. Thirty seven diabetic patients aged 17 to 49 years were included in this study, divided into two groups. Rotatory osteotomy technique was used in all third molar surgeries. Group A (19 patients) received MLD using Vodder's technique combined with cryotherapy and NSAID (Ibuprophen 400 mg). Group B (18 patients) received only cryotherapy and NSAID. Immediately after surgery, patients underwent cryotherapy for 15 minutes every half hour for 48 hours when he or she was awake; however, MLD was applied postoperatively on the affected side and the untreated contralateral side is used as control. Standard pain VAS is used to evaluate pain values, meanwhile, trismus, mouth opening abilities and swelling are measured before surgery, immediately after surgery and 24 and 48 hours after surgery. Trismus is evaluated in terms of Maximum Interincisal Distance (MID) first and five days after surgery. Four standard swelling measurement landmarks are incorporated: tragus-lip junction, tragus pogonion, mandibular angle-external corner of the eye and mandibular angle – median point of chin. Difficulty of surgery is evaluated using the modified version of Parant Scale (I – IV). Data were analyzed using SPSS (v17).

RESULTS

The obtained results from group A subjects demonstrated statistical significant difference ($p < 0,01$) in relation to swelling and pain; although, between the groups there was no significant difference in relation to trismus and Parant Scale ($p > 0,05$). The use of analgesics significantly dropped between days 1 – 3 in Group A patients.

5-8 November 2014 - Harbiye Military Museum & Cultural Center - İstanbul / Turkey

DISCUSSION AND CONCLUSION

An inflammatory complication after third molar surgery in diabetic patients still remains as surgical challenge. The use of MLD combined with cryotherapy and NSAID is more efficient in the treatment of pain, swelling and trismus. We strongly recommend additional controlled trials with larger sample sizes.

Keywords: third molar surgery, diabetes, manual lymph drainage

OP-28

Fractures of the Zygomatic Complex- A Comprehensive Review Over Ten Years of Surgical Management

Thomas Barry, Susan McBride

Department of Oral and Maxillofacial Surgery, Ulster Hospital, Dundonald, Northern Ireland

INTRODUCTION

The zygomatic complex is the second most commonly fractured facial bone. The aetiology of such injuries includes interpersonal trauma, road traffic collisions and contact sports. The intact zygomatic complex is crucial in maintaining facial contours and also significantly contributes to orbital integrity. When fractured, aesthetic and functional problems arise which commonly require surgical management. Over the years with more knowledge obtained in fracture management the surgical treatment of the zygomatic complex has also developed.

AIMS

The aim of this study was to provide a comprehensive assessment of the surgical management of the fractured zygomatic complex.

METHODS

This was a retrospective study examining clinical and radiographic records of all surgically managed zygomatic complex fractures over a 10 year period from 2001-2011. Data was collected on patient age, gender, side of fracture, type of surgery (closed vs open reduction, plates vs wires), associated injuries and treatment outcome.

RESULTS

1343 patients were assessed. Open reduction was performed in 51.4% (690 cases) and closed reduction in 48.6% (653 cases). Of the patients undergoing open reduction, 5.7% (39 cases) required treatment of the orbit and 10% (69 cases) required treatment for other injuries i.e fractured nasal bones and maxillary wall fractures. Postoperative complications occurred in 19% (256), the most common being prolonged paresthesia (11.1%) followed by infection (5.5%), ocular problems including retrobulbar haemorrhage (0.74%) residual aesthetic problems (0.67%) and unsatisfactory reduction requiring redo surgery (0.53%).

CONCLUSIONS

This study demonstrates the changing surgical management of the fractured zygomatic complex over a decade and because of the large cohort assessed comprehensively outlines the coexisting injuries found and the post operative complications encountered.

Keywords: Zygoma, Complications, Surgical management, fracture

OP-29

Finite-element Analysis Investigation of the New Design Titanium Miniplate For The Treatment of Mandible Angle Fractures

İbrahim Macit¹, Süleyman Kaman¹, Fatih Mehmet Çoşkunes², Berkay Tolga Süer³, Fethi Atıl¹, İsmail Doruk Koçyiğit¹, Umut Tekin¹

¹Kırıkkale University Dentistry Faculty Department of Oral and Maxillofacial Surgery Kırıkkale – TÜRKİYE

²Kocaeli University Dentistry Faculty Department of Oral and Maxillofacial Surgery Kocaeli - TÜRKİYE

³GATA Haydarpaşa Department of Oral and Maxillofacial Surgery İstanbul – TÜRKİYE

OBJECTIVE

The mandible is the largest facial bone and also it is the most common bone fractured in maxillofacial region. In last decades many studies aimed to uncover the optimal treatment modality and plates configuration in internal fixation however controversy is still ongoing.

METHODS

Finite element analysis (FEA) 3D reconstruction of human mandible was carried out and angle fracture was performed on model. Adaptation of plates in four scenarios including new design K plate, six-hole single plate, single reconstruction plate and single diamond plate were performed. Segmental displacement and von Mises Stress evaluations were done.

RESULTS

Von Mises stresses were not significantly different in all groups. Cumulative displacement of anterior segment in vertical load was high in reconstruction plate group (0.00297mm) while other three plates presented similar lower results. In horizontal loading four groups of plates presented similar results as follows; 0,002295, 0,002648, 0,003752 and 0,002913 in mms.

CONCLUSIONS

The FEAI is a valid, and non-invasive method to predict complex biomechanical behaviour of human bones. According to segmental displacement results of present study, surgical fixation of angle fractures of mandible with single plates upholds the controversies and further studies is needed.

5-8 November 2014 - Harbiye Military Museum & Cultural Center - İstanbul / Turkey

Keywords: Finite-element analysis miniplate mandible angle fractures

OP-30

Dextrose Prolotherapy Versus Autologous Blood Injection in Management of Chronic Recurrent Temporomandibular Joint Dislocation

Maggie Ahmed Khairy¹, Tamer Abd El Bary Hamed²

¹October university Of Modern Science and Art (MSA)

²6 th of october University

PURPOSE

The aim of the study was to assess the efficacy of dextrose Prolotherapy versus autologous blood injection for the treatment of temporomandibular joint (TMJ) recurrent dislocation.

PATIENTS AND METHODS

Twenty four patients with chronic recurrent dislocation were randomly divided into two groups (12 patients each). Group I received three injections of dextrose solution (3ml of 10% dextrose and 1ml of 2% mepevicaine) each two weeks apart. Whereas the other group was treated by autologous blood injection into the superior joint space and pericapsular tissue. Follow up of the patients included maximal interincisal opening (MIO), number of subluxation episodes and digital radiographic imaging. Data were collected at 2, 4, weeks, 3 months and 6 months interval. The data collected were statistically analyzed.

RESULTS

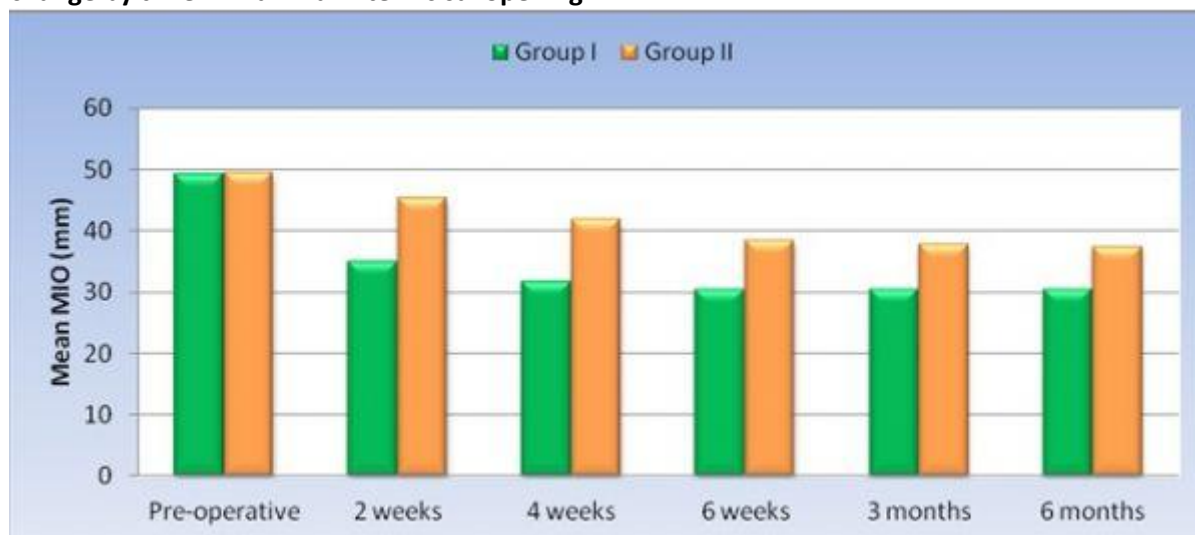By the end of the study, each group showed significant improvement on all parameters. Concerning the maximal interincisal opening both groups showed statistically significant decrease throughout the whole study, however Group I showed lower mean MIO in all intervals. At six months Group I and Group II gave mean MIO of 30.4 ± 4.8 and 37.2 ± 2.2 respectively in comparison to preoperative mean of 49.2 ± 1.7 and 49.5 ± 1.5 . Number of luxation episodes was also markedly decreased throughout the study and by the end of the six months interval only one patient of Group I complained of sporadic luxation while three patients of Group II still had luxation episodes. Digital radiographs of the joint showed the condyle is kept behind the eminence during mouth opening in all patients except for those who still suffered from luxation episodes.

CONCLUSION

From this study we can conclude that dextrose Prolotherapy and autogenous blood injection are both successful, simple and cost-effective techniques for treatment of recurrent TMJ dislocation.

Keywords: Temporomandibular Joint, Dextrose prolotherapy, blood, recurrent dislocation,

change by time in maximal interincisal opening



it shows the effect of time on maximal interincisal opening on the two groups at 2,4,6 weeks and 3,6 months postoperative

OP-31

Management of Recurrent Ankylosis around Prosthetic Joint Replacement

Roya Rashidi, Uthaya Selbong, Andrew J Sidebottom

Oral & Maxillofacial Surgery Department, Queens Medical Centre Campus, Nottingham, United Kingdom

OBJECTIVES

The aim of this study is to assess the efficacy of current management of patients with ankylosis around a temporomandibular joint prosthesis following satisfactory gap arthroplasty and total custom made TMJ replacement. We aim to prevent complete remake of the prosthesis and reduce the need for a second procedure to replace this.

METHODS

Three patients had a single stage procedure in which the prosthesis was atraumatically removed. The recurrent ankylotic mass was resected to leave a 2cm gap and the prosthesis was then replaced into its original position. An autologous abdominal fat graft was placed around the area of articulation and into the gap. Patients were discharged home with temporomandibular joint mobilisation exercise using TherabiteTM.

RESULTS

Patients were reviewed from 6 months to 4 years. There has been no evidence of recurrence of the ankylosis to date with significant improvements in mouth opening and pain scores. On average mouth opening improved by 15 mm and pain scores were reduced from an average of 6/10 to 0/10.

CONCLUSION

The management of recurrent ankylosis with atraumatic removal of total TMJ prosthesis, resection of ankylotic mass and replacement into the initial position of the prosthesis is a safe alternative to a 2 stage full revision procedure. It minimises morbidity, reduces costs and reduces risk of further ankylosis. Outcomes are equivalent to after the first procedure. No evidence of fibrosis or heterotopic bone formation was found either radiographically or clinically.

Keywords: Tempromandibular Joint (TMJ) replacement, Ankylosis, TMJ Surgery, Revision TMJ Surgery

OP-32

Pterygopalatine Ganglion Blockade in Patients with Atypical Facial Pain and Trigeminal Neuralgia

Ezher Hamza Dayisoğlu¹, Ilker Çöven², Burcu Oktay Çöven³

¹Başkent University, Faculty of Dentistry, Department of Oral and Maxillofacial Surgery

²Başkent University, Faculty of Medicine, Department of Neurosurgery

³Başkent University, Faculty of Dentistry, Department of Orthodontics

AIM

Postsynaptic fibers of the pterygopalatine ganglion play an important role on headache, trigeminal neuralgia (TN) and atypical facial pain (AFP). In this study it was aimed to investigate the effectiveness of pterygopalatine ganglion blockade (PGB) in patients with atypical facial pain and trigeminal neuralgia.

MATERIAL-METHODS

Patients who had no abnormalities such as tumoral mass on MR evaluation and who did not respond to medical treatment with carbamazepin longer than 1 year were included in this study. 17 patients with idiopathic TN and 13 patients with AFP instructed PGB with a cocktail of fentanyl, celestone, lidocaine and marcaine via intra-oral approach under the visualization of interventional radiological device.

RESULTS

Patients pain perception was evaluated with VAS and Euroqual 5D scales. VAS values decreased and patients are under follow up for 6 months with minimal need for extra medication.

CONCLUSIONS

PGB was found an effective technique on management of idiopathic TN and AFP with minimal side effects. Further studies with long term follow up are highly recommended.

Keywords: Pterygopalatine Ganglion Blockade, Atypical Facial Pain, Trigeminal Neuralgia

5-8 November 2014 - Harbiye Military Museum & Cultural Center - İstanbul / Turkey

OP-33

Retromandibular Transparotid Approach for Subcondylar Fractures

Nasuh Kolsuz, Altan Varol, Gökhan Göçmen, Selçuk Basa

Department of Oral and Maxillofacial Surgery, Faculty of Dentistry, Marmara University Istanbul, Turkey

The aim of this study was to evaluate the efficacy and complications of retromandibular transpartoid approach performed for reduction of dislocated condylar fractures. The evaluated parameters are: anatomical reduction, facial nerve paralysis, the occurrence of salivary fistula, infection and assessment of the surgical scar,

12 patients participated in the study. (7 male, 4 female, age range 21-56 years, mean 31 years), 4 of whom had other mandibular and/or other maxillofacial fractures - 50% of these had medially dislocated subcondylar fractures. After surgery, no intermaxillary fixation was performed. Complications included 1 salivary fistula, which closed spontaneously after 4 or 5 weeks with a dressing and 1 case of transient facial palsy lasting 4-8 weeks. During follow-up, functional parameters considered were: restoration of original pre-injury occlusion; vertical, lateral and protrusion mandibular movements. All patients were free of pain and had no deflection or clicking upon opening or chewing. None suffered from hematoma, miniplate fractures, bone resorption or condylar necrosis.

Keywords: Retromandibular Transparotid Approach, Subcondylar Fractures,

OP-34

The Differing Fracture Patterns Produced by Anterior and Lateral Impacts to the Frontal Bone; Are They Relevant?

Jonny Stephens¹, Simon Holmes², Amar Kanzaria², Barrie T Evans¹

¹Department of Oral and Maxillofacial Surgery, University Hospital Southampton

²Department of Oral and Maxillofacial Surgery, The Royal London Hospital

OBJECTIVES

To assess the relationship between the direction of force and the pattern of fractures sustained to the anterior cranial fossa (ACF), and possible clinical implications.

METHODS

Patients were identified prospectively and retrospectively from two major trauma centres in the UK. The fractures of the ACF were represented as an individual layer in Photoshop allowing for superimposition of the fractures, and analysis of fracture patterns.

RESULTS

Eighty-one patients were included in the study. With anterior impacts, fractures propagate along the areas of least resistance converging through the ethmoid and sphenoid sinuses with relative sparing of the cribriform plate. Likewise there appears to be sparing of the optic canals. Furthermore, only 12% of this cohort had fractures that propagated beyond the ACF.

In lateral impacts by contrast, fracture patterns appear more sporadic or random with greater likelihood of propagation into the middle and posterior fossa but again, with sparing of the cribriform plate and optics canals.

CONCLUSIONS

The particular anatomy of the central skull base directs fractures through the labyrinth of the skull base sinuses thereby absorbing force. It is felt this collapsible interface reduces the incidence of attendant co-morbidity. The potential clinical implications will be discussed.

Keywords: Skull base, Fracture Patterns, Trauma, Anterior Cranial Fossa

OP-35

Recent Advances in Concepts of Enophthalmos of Orbital Floor Fractures From Trauma

Sarah Segelman¹, Anna Sayan², Velupilla Ilankovan³

¹Senior Maxillofacial House Officer, Poole Hospital

²Staff Grade Surgeon. Poole Hospital

³Consultant Maxillofacial Head and Neck Surgeon Poole Hospital

A fracture of the orbital floor is a complex challenge that requires correction of the inferior displacement of the ocular globe and replacement of retro-orbital fat volume. The minute discrepancy in size increases orbital volume of which access to the posterior aspect of the fracture is limited. Endoscopic approaches enable operators illuminated visualisation of the fracture site and adjacent structures. Advancements in 3D computer tomography now encompass presurgical planning of a repair alongside the use of navigation guided surgery with custom 3D printed implants. Previous research focuses on the access and materials used to reduce the fracture but little has been documented on the replacement of fat tissue which contributes to the displacement of the globe in residual enophthalmos. The loss in volume of orbital fat can be overcome with periorbital soft tissue augmentation, with retrobulbar lipofilling, porous high-density polyethylene wedges or calcium hydroxylapatite. Research has indicated buccal fat has a similar consistency to the fat surrounding the globe. One technique uses a pedicle flap of buccal fat pad transposed through the inferior orbital

fissure. This presentation will summarise the recent advances in enophthalmos of orbital floor fractures and highlight the need for further research into soft tissue augmentation.

Keywords: Enophthalmos, Orbital Floor Fractures, Trauma

OP-36

Evaluation of Pre-Bent Miniplates in Fixation of Le Fort 1 Advancement Osteotomy with the Finite Element Method

Fatih Mehmet Coskunes¹, Bahadır Kan¹, İbrahim Mutlu², Talip Çelik²

¹Department of Oral and Maxillofacial Surgery, Kocaeli University, Kocaeli, Turkey

²Department of Mechanical Education, Kocaeli University, Kocaeli, Turkey

OBJECTIVE

Stability of segment after Le Fort 1 osteotomy attracted researcher's interest by the time that the surgical concept was convinced. The pre-bent plates are ultimate modification of plate systems in craniofacial surgery which have two right angles with different lengths for using in maxillary advancement surgery. Finite element Analysis (FEA) enabled researchers to evaluate the treatment of facial fractures and useage of technique in evaluating plating techniques has been confirmed by different studies with different models.

METHODS

3D maxilla bone was scanned via CT images obtained from a male patient by means of cone beam computed tomography-CBCT. Conventional Le fort 1 osteotomy with 5 and 10 mm advancement were performed on both cortical and trabecular bone using Surgical Simulation Module of Mimics software. 1.7 mm Leibinger standart orthognatic 5 holes L Plates and 1.7 mm Leibinger orthognatic advancement 11 holes Pre-bent plates were adapted to fragments with the advancement of 5 and 10 mm.

RESULTS

Displacement of the segment, Von Mises (VM) stresses (titanium miniplates and screws) and Maximum principal (MP) stresses (bone) for each configuration of plates and screws according to ordinary two miniplates technique and one pre-bent Leibinger miniplate for Le Fort 1 osteotomy are evaluated.

CONCLUSIONS

Pre-bent plates would be a good alternative to conventional two plates except in maxillary advancement surgeries exceeding 5mm forward movement. Surgical aims that need advancements exceeding 5mm or vertical position changes in still controversial and further studies are needed.

Keywords: Le Fort 1 osteotomy, pre-bent plates, Finite element Analysis

OP-37

The Application of Facial Aponeurotic System in Controlling Nasal Widening Sequel of Midfacial Surgery

Nima Moharamnejad¹, Behnam Bohluli²

¹CranioMaxilloFacial Research Center, Tehran University of Medical Sciences, Tehran, Iran.

²Department of Oral and Maxillofacial Surgery, Azad University, Buali Hospital, Tehran, Iran.

The dynamic of facial changes according to the surgery of hard and soft tissue is one of the most debating issues in facial surgery treatment plan specially orthognathic surgery and rhinoplasty. The nose is uniquely more prominent structure of midface and any alternation could be affected the whole result of any facial surgery. Many studies have been showed that alar widening is an inevitable sequel of Le fort I surgery and many techniques are introduce to adjust this sequel. Regarding the new cadaver model findings on facial aponeurotic system and effect of ligaments on nasal structural support; in this article authors present a modification of pyriform ligaments manipulation for controlling the nasal sequel of midfacial surgery.

Keywords: facial aponeurotic system, orthognathic surgery, rhinoplasty

OP-38

Cervical Vertebral Column Morphology and Association with Obstructive Sleep Apnea: A pilot study

Ulas Oz¹, Kaan Orhan², Finn Rasmussen³

¹Department of Orthodontics, Near East University, Nicosia, North Cyprus and Cyprus Sleep Center, Near East University Hospital, North Cyprus

²Department of Dentomaxillofacial Radiology, Near East University, Nicosia, North Cyprus and Department of Dentomaxillofacial Radiology, Ankara University, Ankara, Turkey

³Department of Allergy, Sleep and Respiratory Medicine, Near East University Hospital, North Cyprus and Cyprus Sleep Center, Near East University Hospital, North Cyprus

OBJECTIVE

Obstructive Sleep Apnea (OSA) is a condition caused by recurrent upper airway obstruction during sleep causing pauses in breathing and sleep fragmentation. Upper airway morphology is of importance in OSA but only few studies have described morphological deviations of cervical vertebral column in OSA.1, 2. The objective of the current study is to describe the morphology of the cervical vertebral column and its effect on pharyngeal airway and maxilla-facial area in patients with OSA.

METHODS

We randomly selected twelve OSA patients' routinely taken sleep test and cone-beam CT (CBCT) images to reveal possible association between cervical (C1-C4) vertebral morphology and OSA level.

5-8 November 2014 - Harbiye Military Museum & Cultural Center - İstanbul / Turkey

Cervical vertebrae area, volume and distance to anterior face; also tongue area were evaluated on CBCT images and compared to Apnea Hypopnea Index (AHI), (Figure 1).

RESULTS

The length of the most prominent edge of the C1 to anterior wall of the airway was significant associated with the AHI index ($p=0.024$). The length of C2 inferior edge to mandible anterior region showed negative agreement; however this association did not reach formal significance ($p=0.056$). All other morphological measurements seemed to not associate with AHI.

CONCLUSION

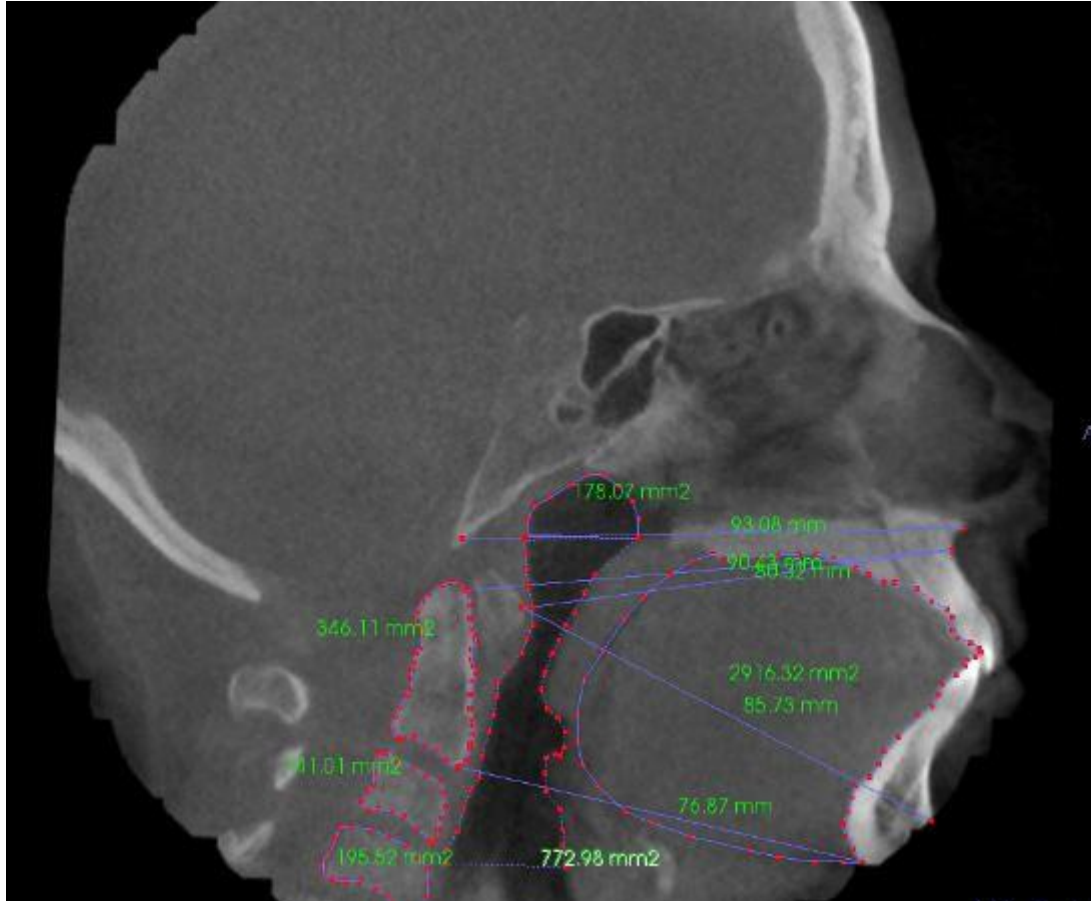
In the current study, morphology of cervical vertebrae (C1-C4) has been assessed on CBCT scans of patients with OSA. Sleep apnea index and C1 position related with upper airway area showed significant negative association on axial projections. In addition, C2 position and distance to the mandible indicated that a negative relationship between cervical vertebrae- mandible distance and AHI. On the other hand, the volumetric and antero-posterior area measurements of C1-C4 were not correlated with AHI scores. We suggest that cervical vertebrae morphology and airway patency need for new detailed characterization. New 3D methods such as volumetric data segmentation and registration may provide valuable data to comprehend airway morbidity.

Literature

1. Pakkala R, Puustinen R, Tuomilehto H, Ahlberg J, Seppä J. Risk factors for sleep-disordered breathing: the role of craniofacial structure. *Acta Odontol Scand.* 2011 May;69(3):137-43.
2. Sonnesen L, Jensen KE, Petersson AR, Petri N, Berg S, Svanholt P. Cervical vertebral column morphology in patients with obstructive sleep apnoea assessed using lateral cephalograms and cone beam CT. A comparative study. *Dentomaxillofac Radiol.* 2013;42(6):20130060.

Keywords: Cervical vertebrae morphology, OSA, CBCT

Measurements for cervical vertebral morphology



OP-39

Relationship Between Duration of Preoperative CPAP Use and Outcomes Following Maxillomandibular Advancement Surgery for Obstructive Sleep Apnoea

Shofiq Islam¹, Christopher Taylor², Ian W Ormiston¹

¹Department of Maxillofacial Surgery, University Hospitals of Leicester NHS Trust, Leicester, UK

²Department of Chest Medicine, Salisbury District Hospital, Wiltshire, SP2 8BJ United Kingdom

AIM

Continuous positive airway pressure (CPAP) remains first line therapy for OSA. Various physiological changes are known to result from CPAP therapy. The objective of this study was to evaluate the relationship between the preoperative duration of CPAP therapy and outcomes following maxillomandibular advancement (MMA) for OSA.

METHOD

We undertook a retrospective analysis of consecutive patients who underwent MMA surgery for OSA at our institution. Subjects were divided into two groups based on duration of CPAP therapy: 'short-term' <12months versus 'long-term' >12months. We controlled for baseline demographic and clinical characteristics. We compared postoperative apnoea / hypopnea indices (AHI), Epworth sleepiness scores (ESS) and lowest recorded oxygen saturation (SpO2 min) in both CPAP duration groups.

RESULTS

We identified 43 patients who had preoperative CPAP duration data available. Of these, 37 had pre and postoperative polysomnographic data available for inclusion in our analysis. The majority underwent Bi-maxillary advancement with Genioplasty. There was no statistically significant difference in the mean postoperative AHI reduction and SpO2 min, between the groups, with equivalent operative success rates noted. We observed a significantly greater reduction in the mean ESS after surgery in the 'long-term' group compared with the 'short-term' group ($p<0.001$).

CONCLUSION

This present study has shown equivalent benefit in terms of AHI reduction following MMA in both 'short-term' and 'long-term' CPAP patients. The results suggest that the length of CPAP treatment prior to surgery does not significantly influence objective outcome measures. On subjective outcome measures the long-term group appeared to fare better than the short-term group.

Keywords: CPAP Adherence; Duration; Outcomes; Maxillomandibular Advancement Surgery; Obstructive Sleep Apnoea; Orthognathic Surgery

OP-40

Use of a Bespoke Occlusal Cutting Guide for Genioplasty in Facial Asymmetry

Iain Varley¹, Nicholas Lee²

¹Department of Oral & Maxillofacial Surgery, University of Sheffield, Sheffield, UK

²Department of Oral & Maxillofacial Surgery, Sheffield Teaching Hospitals NHS Foundation Trust, Sheffield, UK

Facial asymmetry surgery can be challenging, and genioplasty to correct asymmetry particularly so. 3D planning can assist in gaining a full appreciation of the anatomy, and bespoke surgical solutions are increasingly popular, with patient-specific cutting guides and implants becoming commonplace in oncology and trauma surgery. Fitting of guides can require wide bony exposure, and can be challenging in areas where access is restricted.

We demonstrate use of a bespoke cutting guide (Synthes) with an occlusal fitting stent that allows accurate translation of planned movements to the surgical field, with easy fitting and predictable movement of the genioplasty segment, that does not require wide bony exposure.

Keywords: orthognathic, facial asymmetry, genioplasty

OP-41

Orthognathic Surgery for Obstructive Sleep-Apnea Syndrome (OSAS)

Altan Varol

Department of Oral and Maxillofacial Surgery, Marmara University, Istanbul, Turkey

Obstructive sleep apnea syndrome (OSAS) is a common primary sleep disorder. It is characterized by repetitive partial or complete upper airway collapse during sleep. The general treatment consists of nasal continuous positive airway pressure ventilation (CPAP) during sleep and mandibular advancement oral appliances which are often effective and the most widely used therapy. They are not definitive for more severe OSA and patients show poor long-term compliance. Maxillary and mandibular advancement osteotomies have proven over the past decade to reverse even severe OSA at greater than the 90% efficacy levels. The presentation will focus on orthognathic surgery in adult OSAS, as this is the most common and clinically effective application of MMA to treat OSA.

Keywords: maxillomandibular osteotomy, counter-clockwise rotation, obstructive, sleep, apnea



4th Conference of BAMFS (Balkan Association of Maxillofacial Surgeons)

5-8 November 2014 - Harbiye Military Museum & Cultural Center - İstanbul / Turkey

Poster Presentations

5-8 November 2014 - Harbiye Military Museum & Cultural Center - İstanbul / Turkey

PP-001

Approaches to the Anterior Cervical Spine and Skull Base; a Special Emphasis on the Forgotten Trotter's Approach

Ibraz Siddique, Muzzammil Ahmed Nusrath, Iain Hamilton Mcvicar

Department of Oral and Maxillofacial Surgery, Queen's Medical Centre, Nottingham, United Kingdom

Surgery to the upper anterior cervical spine and skull base is a complex proposal due to the presence of vital structures. Despite these challenges, surgery in this area must achieve fundamental goals including complete tumour control, adequate exposure, preservation of function, minimisation of cosmetic deformity and simplicity of technique. Surgeons have devised several approaches to the anterior cervical spine and skull base. Broadly, these are divided into approaches through the oral cavity or through the neck. All approaches involve operating through the oropharynx and hence a sound appreciation of oropharyngeal anatomy and landmarks is required for those conducting anterior cervical spine and skull base surgery. A Head and Neck surgeon who has sound knowledge and experience of the local anatomy and experience in operating in this area may offer alternative approaches that meet the objectives of good surgical exposure with minimal morbidity to the patient.

In the era of robotic surgery, some previous techniques may be forgotten but some still remain invaluable to us and should remain in the armamentarium of the Head and Neck, Spinal and Neurosurgeon.

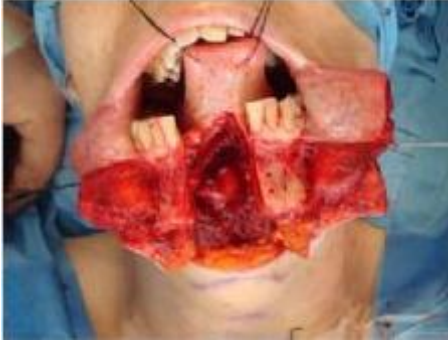The labiomandibuloglossotomy or Trotter's approach was first described in the 1920s and offers excellent surgical exposure. Head and Neck surgeons have employed this approach for tongue base tumours. Although this approach involves a midline mandibulotomy, low postoperative morbidity has been reported. It fell into disrepute in the 1960s because of the high rate of hardware failure but with the advent of newer technology, locking plates and screws this approach has an almost a 0% complication rate as long as attention is given to finer detail.

We recommend the median labiomandibuloglossotomy surgical approach for the upper anterior cervical spine and skull base as an additional option for cases requiring enhanced access. It permits preservation of all vital structures and fulfils the objectives of surgical access. We believe it should gain its due status in anterior cervical spine and skull base surgery and surgeons should consider exploiting this route once again. Furthermore, this approach will help enhance collaborative efforts between Head and Neck, Spinal and Neurosurgeons in this ever expanding field of anterior cervical spine and skull base surgery.

We outline the relevant applied anatomy and illustrate a patient case with the steps involved in the Trotter's approach to the anterior cervical spine and skull base. We highlight the pitfalls with top tips to conduct this approach safely with minimal morbidity.

Keywords: Labiomandibuloglossotomy; trotter's; cervical spine; skull base

The median labiomandibuloglossotomy



Midline mandibulotomy and incision through floor of the mouth. Note predrilled holes before the mandibulotomy

PP-002

Case Report: Various Manifestations of Multiple Myeloma in the Maxillofacial Region

Ali Hanttash Abu Hanttash¹, Ümit Kamal Aktaş¹, Mehmet Hakan Kurt²

¹Department of oral surgery, Ankara university, Ankara, Turkey

²Department of oral radiology, Ankara university, Ankara, Turkey

INTRODUCTION

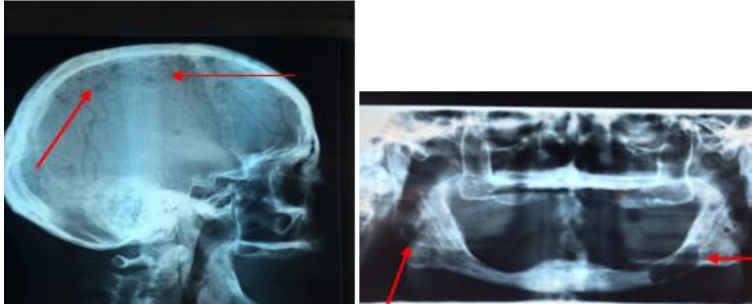Multiple myeloma is a malignant hematological disease that is characterized by monoclonal malignant proliferation of plasma cells. Characteristic features of multiple myeloma include osteolytic bone lesions, severe bone pain, pathological fractures, hypercalcemia, renal impairment and anemia. Its occurrence in the maxillofacial region is common with more than 30% of the patients developing osteolytic bone lesions in the jaw. Not only the disease itself but the treatment approaches may have severe consequences affecting the jaws. In this report we present case of multiple myeloma presenting itself as osteolytic lesion in the jaw.

CASE

a 54-year-old male patient with an osteolytic lesion in the left mandibular body accompanied by pathological fracture.. The case presented here highlight the fact that it is very important for the clinician to have knowledge about the maxillofacial manifestations of multiple myeloma for the early diagnosis of the disease and be aware of the side effects of its treatment.

Keywords: Myeloma, Mandible, Fracture

Multiple Myeloma



PP-003

Tibiofibular Synostosis Discovered Intra-Operatively on Harvesting the Free Fibula Graft in Maxillofacial Surgery

Victoria Mellish, Martin Woods, Graham Smith, Nicholas Hyde
Department of Oral & Maxillofacial Surgery, St George's Hospital, London

A rare example of mid-shaft tibiofibular synostosis was discovered intra-operatively whilst harvesting the fibula for an osteoradionecrosis resection of the mandible.

Following diagnosis of a TON2aM0 unknown primary metastatic squamous cell carcinoma lesion in the right neck, our 65 year old patient underwent a right radical neck dissection levels I-IV with post-operative radiotherapy in 2012. He subsequently developed osteoradionecrosis of his mandible which later necessitated right segmental mandibulotomy with right composite fibula free flap in April 2014. It was on this occasion that the tibiofibular synostosis was discovered. The fibula was viable and the synostosis immediately osteotomised. With no history of lower limb developmental problems and a history of leg injuries, aetiology was presumed secondary to previous injury.

Post-traumatic tibiofibular synostosis is rarely asymptomatic. The majority of patients suffer pain and limitation of lower leg movements. Pathogenesis can develop when a fracture causes a severe haematoma around the intraosseous membrane. The calcification of the haematoma can then result in bony fusion. Distal tibiofibular synostosis is a known but poorly described complication of ankle fractures.

This gentleman had suffered a number of injuries to his right leg from the 1970's onwards. These were managed conservatively in plaster and he suffered no long term symptoms. Within the past 10 years he developed arthritis and underwent surgical management of his right knee. The literature shows that synostosis can be easily identified on radiographs. Since his first injury, there has been no evidence of synostosis reported.

Six months following his mandibulotomy, the graft donor and recipient sites have demonstrated good healing with no complications following the use of a fibula with previous synostosis.

Keywords: Tibiofibular, Synostosis, Fibula, Graft, Maxillofacial

PP-004

Image Quality Comparison of Computed Tomography Rendered Orthopantomograms with Traditional Orthopantomograms in Pre-Radiotherapy Dental Assessment

Victoria Mellish, Kavin Andi

Department of Oral & Maxillofacial Surgery, St George's Hospital, London

OBJECTIVES

A new approach in attaining dental radiographic images is being evaluated in the Oral and Maxillofacial Surgery (OMFS) Department at St George's Hospital, London. All Head and Neck oncology patients require staging imaging to establish their diagnosis. Those that require radiotherapy undergo a dental assessment. Although the computed tomography (CT) staging images are extensive, they do not transfer well for dental interpretation. Our current policy is to perform an orthopantomogram (OPG) in order to radiographically examine the patient's dental health in detail.

In this study we aim to investigate the diagnostic quality of traditional OPGs compared with those constructed from CT scans using the OSIRIX high definition volume rendering software. We also aim to identify other OMFS clinical scenarios that this technique could be applied to.

METHOD

Retrospective evaluation of pre-radiotherapy images of ten random patients discussed at St George's Hospital Head and Neck oncology multi-disciplinary meeting in June and July 2014. Patients within the inclusion criteria were adult, dentate and had pre-radiotherapy OPG and CT of their mandible and maxilla. CT images were reconstructed into OPGs using a standardised method on the OSIRIX software in the 3D curved multi-planar reconstruction (MPR) mode. Traditional and rendered images were evaluated by an OMFS Consultant, Radiographer and a Dental Restorative Consultant. Relevant hard tissue landmarks were compared on each patient's images according to the National Radiation Protection Board's diagnostic quality rating 3 point scoring scale.

RESULTS

CT OPG images demonstrated areas of acceptable diagnostic quality, however only the floor of the maxillary sinus produced diagnostic quality superior to the traditional OPG. Vastly improved quality with fine cut CT scans. Difficult to produce uniform images, as the software cannot compensate for angulation changes of the teeth or positional asymmetry.

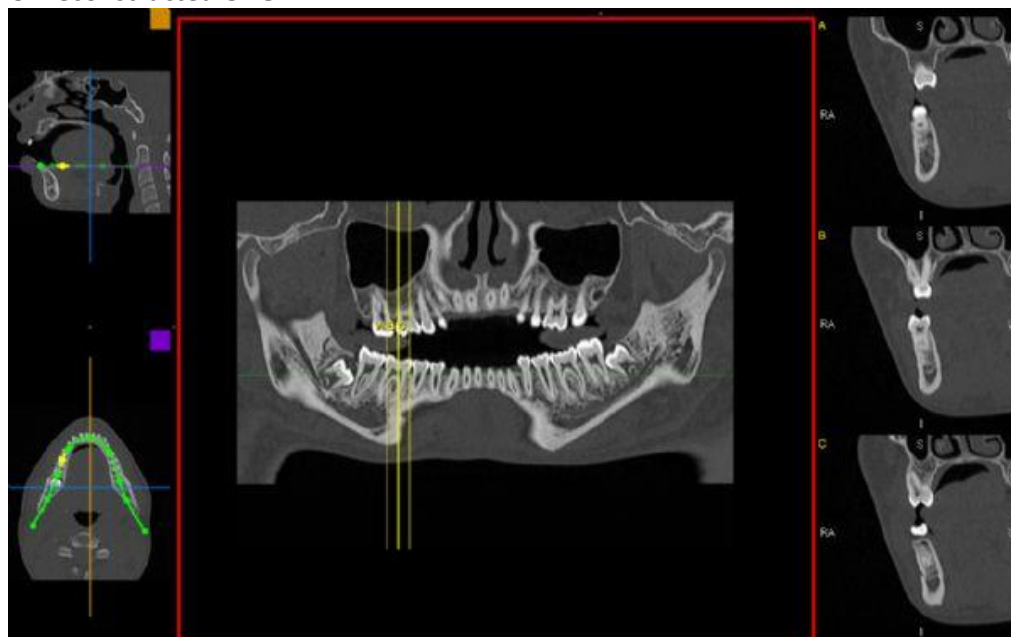
CONCLUSION

With the rapid advancement of computer technology, this new approach in attaining dental images may be adopted in the future, once the images are of excellent diagnostic quality. It effectively utilises imaging available and could be invaluable in assessing OMFS trauma when conventional imaging is contraindicated. The improved quality with fine cut CT enables high quality dentally

diagnostic 2D images from CT scans to be manipulated, with the addition of 3D cross-sectional assessment.

Keywords: OSIRIX, Orthopantomogram, Maxillofacial, 3D Curved MPR

CT reconstructed OPG



2D image reconstructed from a CT scan

PP-005

A Study of Blood Haemoglobin Levels in Head and Neck Oncology Patients Prior to Radiotherapy

Dr Ahmed Abdelrahman, Mrs Elizabeth Gruber, Mr Andrew Rennie, Mr Graham James
Department of oral and maxillofacial surgery, Worcester Royal Hospital, Worcester, West Midland,
UK

OBJECTIVE

Low haemoglobin (Hb) and a poor response to radiotherapy has been established, especially in patients with squamous cell carcinomas (SCC) such as cervical and laryngeal. Studies have shown a correlation between low pre-radiotherapy Hb level and poor local regional control as well as survival. Nordsmark and Overgaard (2004) showed that the Hb was prognostic of locoregional tumour control at 5 years. This work was supported by Krsteva et al, 2012 showing pre-treatment haemoglobin level was an independent prognostic factor for loco-regional relapse-free survival and disease-free survival, as well as overall survival in oropharyngeal cancer. Hypoxic environment may increase the radio-resistance of the tumour cells by two or three folds. The efficacy of the radiotherapy is limited

in such situations. One of the strategies to remedy the hypoxia is early recognition and treatment of anaemia.

The waiting time target for treating cancer patients is precious. In England, The current target is approximately 31 days after establishing the diagnosis to start the treatment.

The aims of the study were:

To determine the number of patients with anaemia prior to starting radiotherapy.
To establish the time scale between the diagnosis of the cancer and commencing the radiotherapy

METHOD

We made a retrospective analysis of serum Hb levels in 60 patients who were diagnosed with oropharyngeal SCC and received radiotherapy as part of their treatment. The target Hb was in reference to that used by our institution.

RESULTS

60 patient case notes were reviewed. 75% were males. The mean age was 57 years old (range 25 to 89 years old)

28/60 46.7% had combined surgery and radiotherapy compared to 53.3% who underwent primary radiotherapy. Our hospital reference range is 115 to 145 (g/L). 21.7% (13/60) patients were anaemic prior to their radiotherapy. 11 patients of the 13 had combined treatment surgery and radiotherapy. The time period between diagnosis and start of radiotherapy was from 14 to 120 days.

CONCLUSIONS

A considerable number of patients in this study were anaemic prior to their radiotherapy. On reviewing the duration from diagnosis to radiotherapy commencement, there is a window of opportunity for the correction of the anaemia to optimise the serum haemoglobin levels.

Keywords: Oncology, Radiotherapy, anaemia

PP-006

Patient Reported Outcome Measures Survey on Non Melanoma Skin Cancer (NMSC)

Graham Merrick, Julian Page, Ben Collard
Musgrove Park Hospital, Taunton, England

OBJECTIVE

We sought to review patient satisfaction after NMSC surgery in our department through the use of a Patient Reported Outcome Measures questionnaire. Skin cancer surgery can be a stressful and emotional experience for patients. This can be of particular importance if it involves highly visible

areas such as the head and neck. We are keen to ensure patients are satisfied with all aspects of their care when undergoing skin surgery in our department. Ensuring patient satisfaction is central to good patient care and may aid commissioning for our department in the future. Patient satisfaction surveys help clinicians to identify ways to improve their practice.

METHODS

We asked 70 patients who had undergone NMSC surgery in our department, to complete a patient satisfaction questionnaire. There are no standardised questions and ours was based on an orthognathic Patient Reported outcome measures survey. No patients were excluded. The questionnaire was completed and returned to reception prior to the patient's departure. The data from the questionnaires was then analysed on an excel spreadsheet.

RESULTS

Patients were generally satisfied with their facial appearance and scar upon completion of their treatment. Patients were also extremely happy with the logistical aspect of their surgical planning, their post operative care and the information they were given.

Patients' commented on the high interpersonal manners of the staff, and remarked on the good communication regarding their care. A few patients appeared dissatisfied with being asked to attend the hospital at the start of the morning or afternoon and having to wait for the end of this session to have their surgery. Comments also included complaints of extortionate car parking fees.

CONCLUSIONS

Patient satisfaction surveys can help identify ways of improving your clinical practice, which ultimately translates into better care and happier patients. Our patient satisfaction survey has shown that skin cancer patients in our department, are happy with the care they have received. This has included satisfaction with the information received, communication from clinical staff and surgical outcomes. We have made arrangements to improve patient awareness, regarding the wait on the day of surgery, as staggering patients is less efficient for the surgeon and last minute investigations are sometimes required. We will continue to review our patient satisfaction ensuring changes are made when needed to provide excellent patient centred care.

Keywords: Patient Reported Outcome Measures, Skin cancer

PP-007

Composite Free Flap Reconstruction Following Stage 4 Mandibular ORN

Michail Tsakalidis, Timothy Martin, Prav Praveen, Satyesh Parmar

Oral and Maxillofacial Department, Queen Elizabeth Hospital, Birmingham, United Kingdom

OBJECTIVES

Osteoradionecrosis (ORN) of the mandible is a well known late complication of ionising radiation therapy for malignant tumours in the head and neck region. This debilitating

5-8 November 2014 - Harbiye Military Museum & Cultural Center - İstanbul / Turkey

disease not only affects patient's well being but also presents a great challenge to the reconstructive surgeon in terms of treatment. In cases of Stage 4 ORN the preferred treatment modality is reconstruction of the diseased bone with free flaps or reconstructive plates. Various types of flaps have been described in the literature with the most common being the osseocutaneous fibula flap. Our objective is to share our experience and show the success rate and complications we have encountered whilst treating patients with composite free flaps for Stage 4 mandibular ORN.

METHODS

The Birmingham oncology database was reviewed retrospectively to identify patients who were diagnosed with Stage 4 ORN of the mandible and who had a reconstructive surgery with a composite free flap. All patients underwent surgery at the same institution between 2005 and 2014. The collected data included patient demographics, diagnosis, smoking status, radiation dose, time elapsed between end of radiotherapy and diagnosis of ORN, cause of ORN, recipient site, donor site, complications, ORN recurrence, flap failure, post op occlusion length of antibiotic post operatively, inpatient stay, gastrostomy tube (G-tube) feed dependence, follow up time and patient survival.

RESULTS

A total of 18 patients were included, 13 males and 5 females, with a mean age of 59.11 years. 16 patients received radiotherapy alone (50-55 Gy) whilst 2 had chemo - radiotherapy (38Gy). In 10 cases ORN developed post dental extraction. A total of 14 fibulas and 4 scapulas were used. The overall success rate is 94.11%. There was 1 total flap failure (fibula). 4 patients developed a post operative infection at the surgical site prolonging the need for antibiotics and 2 patients had persistent malocclusion post operatively. None of the patients had a ORN recurrence. The mean follow up time was 27.65 months.

CONCLUSION

Composite flaps remain a reliable tool in the surgeon's armamentarium for treating a resected Radio - osteonecrosed mandible as shown by our unit's success rate of 94.11%. Despite all potential post operative complications, this treatment option provides good results in terms of restoring normal jaw function and therefore improving patient's well being.

Keywords: ORN, Osteoradionecrosis, mandible, composite flap

5-8 November 2014 - Harbiye Military Museum & Cultural Center - İstanbul / Turkey

PP-008

Videolaryngoscopy as a Assessment Tool after Major Head & Neck surgery

Muzzammil Nusrath¹, Anjum Ahmed Nusrath²

¹Department of oral and Maxillofacial Surgery, University Hospitals of Nottingham, Nottingham, United Kingdom.

²Department of Anaesthesia and Intensive Care, Derby Hospitals NHS Foundation Trust, Derby, United Kingdom

Tracheostomy may be required after major surgical resection for head and neck cancer and in severe oropharyngeal infection and trauma. It has several advantages—the airway is secure, oral hygiene is improved with more effective bronchial toilet and ventilation is easier. However, tracheostomy carries an appreciable morbidity and is not a blanket policy in all major resections. In head & neck cancer and after major excisions the rate of emergency re-intubation varies from 0.7 to 11.1%. We describe the role of Glidescope-- a videolaryngoscope in assessment of upper airway & for planning postoperative airway management.

Videolaryngoscopes resemble traditional laryngoscope, but have a videochip embedded in the blade. The video chip transmits magnified images to a display screen where they can be seen and recorded. The fundamental difference is that the laryngeal view is generated by a videocamera focused at the laryngeal inlet and alignment of the oral, pharyngeal and laryngeal axes is not essential to view the glottis. This allows the operator to “look around corners”. The view is generated by a wide-angled lens focussed at the vocal cords and therefore gives a superior view of the vocal cords and the supraglottic anatomy when compared with conventional laryngoscopes or the small monocular image generated with fibroscope. The remote display screen of the Glidescope is useful in teaching, training and instruction.

The images on the remote display system are seen by the entire theatre team. This is useful in evaluating the degree of oropharyngeal swelling and distortion after major resection and reconstruction for cancer. Repeat laryngoscopy by both the surgeon and the anaesthetist, is not required when videolaryngoscopes are used.

Videolaryngoscopy is particularly useful following free flap transfer at the base of tongue or oropharynx. The oropharyngeal tissues and mandible do not need to be retracted to achieve a line-of-sight to view the upper airway and vocal cords. This results in significantly lower forces exerted on the flap and oropharyngeal tissues compared with conventional direct laryngoscopes thereby minimising damage to the flap and its blood vessels.

Movement of the cervical spine during videolaryngoscopy is less with a consistently better view of the larynx in patients with fixed cervical spine. Because alignment of oral, pharyngeal and laryngeal axes is not needed to view the upper airway. We describe our experience and technique of using videolaryngoscopy in trauma following cancer resection and in deep neck infections.

Keywords: Videlaryngoscopy, oropharyngeal cancer, trauma, deep neck infections

PP-009

Eosinophilic Granuloma of Temporal Bone Mimicking TMD: A Case Report

Burcu Oktay Çöven¹, Ezher Hamza Dayısoylu², Ilker Çöven³

¹Başkent University, Faculty of Dentistry, Department of Orthodontics

²Başkent University, Faculty of Dentistry, Department of Oral and Maxillofacial Surgery

³Başkent University, Faculty of Medicine, Department of Neurosurgery

INTRODUCTION

Eosinophilic granuloma (EG) is a rare and relatively benign form of histiocytosis of the Langerhans cells. Radiologically EG characterized by unifocal or multifocal osteolytic lesions that affect the skull. Although the lesion is initially silent, it may erode the bone and destroy the cranial skeleton. Its occurrence on temporal bone indirectly affects the temporalis muscle. In this study it was aimed to report a patient with EG of temporal bone that mimicking temporomandibular joint disorder (TMD).

CASE

A-17- year old male patient were referred to the Baskent University Faculty of Dentistry Department of Oral and Maxillofacial Surgery for his ongoing temporomandibular joint pain. Clinical examination revealed tenderness and limitation of jaw movement on left side of the mandible. In addition palpable lymph nodes were noted in the post-auricular area. MRI evaluation showed a 40x30mm destructive lesion on the temporal bone.

RESULTS

Patient operated with a cranioplasty procedure under general anesthesia. Histopathological result revealed eosinophilic granuloma. Patient is under follow up procedure for 6 months with no recurrence.

CONCLUSIONS

Although the effects of EG are well described on hard tissue, peripheral muscle groups may also been affected via indirect mechanisms. Temporalis muscle involvement may limit the jaw functions in addition to pain on palpation as described in this report. Therefore a careful clinical and radiological examination plays an important role in the differential diagnosis between a tumoral mass and TMD.

Keywords: Eosinophilic Granuloma, Temporal Bone, TMD

PP-010

Dental Management in Epidermolysis Bullosa Dystrophica: A Case Report

Secil Cubuk¹, Esra Beyler¹, Burak Bulmus¹, Ebru Aktepe Tirali²

¹Baskent University Department of Oral and Maxillofacial Surgery

²Baskent University Department of Pedodontics

OBJECTIVE

Epidermolysis Bullosa (EB) Dystrophica is a rare genetic bullous disease. Blister formation occur even by minimal trauma and the lesions heal slowly and are accompanied by scar formation in these diseases. A profound susceptibility to dental caries can be frequently observed because of the presence of defect in enamel tissue and inability to maintain the oral hygiene by patients. Oral examination and dental treatment is challenging due to the continuous blister and scar formation, restriction of mouth opening and contracture of the perioral soft tissues. In this report it was presented that the dental treatment and postoperative management of the child with EB dystrophica.

CASE

A nine year old girl was referred to our clinic with complaint of dental pain at left mandibular molar region. According to medical history the patient had dystrophic EB and had used silver sulfadiazin (Silverdin %1, 400 gr, DEVA) for skin wounds routinely. Other comorbidities associated with EB were loss of visualization and synechia at left eyes, severe scarring at perioral region and extremities. In extraoral examination microstomia and restriction of mouth opening because of severe scarring were observed. Additionally residual roots of molars and deep dentin caries at permanent molar teeth have been noted in intraoral and radiographic examination. Multiple teeth extraction and restoration procedures were performed under general anesthesia. Severe blister formation and desquamation occurred while manipulation of oral mucosa and skin. Oral rinse and novacain combination were prepared and used for postoperative management of the mucosal and skin wound. No infection or other major healing complication was observed at the early postoperative period.

CONCLUSION

Management of oral rehabilitation of patients with EB may be challenging during operation and postoperative mucosal healing period. Some special considerations such as using novacain and oral rinse combination pomades and frequent follow-up to prevent from adhesion of intraoral organs is required for minimizing the postoperative complications.

Keywords: Dental Management, Epidermolysis Bullosa, Dystrophica

5-8 November 2014 - Harbiye Military Museum & Cultural Center - İstanbul / Turkey

PP-011

Quality of Online Information Regarding Dental Implants

Shabnum Ali¹, Kirsty Woodmason², Neil Patel²

¹University Hospital Bristol

²Manchester Dental Hospital

OBJECTIVES

Dental implants are increasingly becoming a desirable option for tooth replacement. The Internet is a major source of material relating to healthcare, however, the quality of the information available has varying levels of supporting evidence. Inaccurate or very basic information may lead to inappropriate patient perceptions, unrealistic expectations and poor decision-making. The aim of this study was to analyse the quality of online information available to patients regarding dental implants.

METHODS

A cross sectional survey was carried out using the terms 'dental implant(s)' into Google and Yahoo. The first 30 websites were scrutinized according to the DISCERN tool categories: accessibility, target audience, provision of reference materials, owner of site, produced by a professional association/group, professional status of author and accreditation of site. Website reliability and website content scores were given from 0 to 2 based on whether the tool criteria was in accordance with current accepted evidence or not.

RESULTS

Overall, website content quality was low, with 63 % of sites averaging below 7/14 for their mean summed website content scores, and 67 % of sites averaging below 8/16 for their mean reliability scores. 86.7 % were accredited by a recognised national/international dental/surgical body but only 26.7 % were affiliated to a professional group/medical institution. The authors were mainly dentists (73.3 %). The mean total website reliability score was 5.4 (range 0-16) the mean total website content score i.e. the quality of information on various aspects of treatment was 4.9 (range 0-14). Within the website content scores 'benefits of treatment' and 'procedure' details had the highest mean scores of 1, and 'other options' and 'long term outcomes' had the lowest website scores (0.4 and 0.5). The mean score for the 'complications' category for websites authored by dentists (n=22, mean = 0.5) was significantly lower than the mean content score for 'complications' category for websites written by unspecified authors (n=6, mean =1.2) (p = 0.031). These dentists may have been advertising their services through their websites, and may not want to draw attention to the complications of implant treatment.

CONCLUSION

These findings suggest that online information available to the public regarding implant treatment is generally of low quality and many aspects such as long term outcomes and complications are overlooked. Moreover, as per the GDC 2012 guidelines on ethical advertising, registrants run the risk

of fitness to practise proceedings and medico-legal challenges if the website content has potential to mislead patients.

Keywords: implants, online information

Table showing mean website content scores based on quality of information on various aspects of treatment.

Content variable	Mean score	Range
Indications	0.9	0-2
Procedure	1	0-2
Benefits of treatment	1.03	0-2
Complications	0.6	0-2
Healing times	0.5	0-2
Long term outcomes	0.47	0-2
Other options explained	0.43	0-2
Mean score for 30 websites reviewed	4.93	0-15

PP-012

Use of Computer Tablet Database Collection for Skin Cancer Databases

Graham Merrick, Julian Page, Ben Collard, James Ingham
Musgrove Park Hospital, Taunton, England

OBJECTIVE

Minimum Dataset collection in all aspects of Maxillofacial surgery, is challenging for both surgeons and clinicians alike. Computerised databases can hold large amounts of information and permit searches for a specific criteria. They can be easily amended and updated, and can be password protected when needed. The applied use of computer tablet technology in the development of a skin cancer database allows real time input of data. We review the use of a Computer Tablet Database Collection for skin cancer data collection in our practice.

METHODS

We use the Taunton based Clinical Scoring Solutions data base. This has been adapted for recording outcomes and demographics for non melanoma skin cancer. We retrospectively input all cases of non melanoma skin cancer into our computerised database. No patients were excluded from our study.

RESULTS

Computer Tablets provide a user friendly interface and an easily adaptable system to allow for rapid input of data and its analysis. We present the outcome data and format for the first 380 cases of non melanoma skin cancer entered into the database, and demonstrates the type and quality of outcome data that can be accessed and reproduced as part of ongoing audit and quality assurance.

CONCLUSIONS

Collection of accurate data and analysis of resection margins and complication rates, as well as basic demographics and treatment numbers, is a vital aspect of providing an ongoing quality assured service within the National Health Service. The availability of accurate and up to date real time information on quality trends in any surgical service rely heavily on the quality and ease of data input. We have found in our practice that the use of a Computer Tablet Database Collection both aids the ease of data input, and allows real time information on quality of resection margins and complication rates.

Keywords: Skin cancer, Computerised database

PP-014

Effect of Low Level Laser Therapy on Viability, Apoptosis and Senescence of Clinical Grade Adipose Derived Mesenchymal Stem Cells

Zeynep Burçin Gönen^{1,2}, Dilek Bahar³, Hasan Salkın¹, Abdullah Ekizer⁵, Servet Özcan⁴, Alper Alkan²

1Erciyes University, Genome and Stem Cell Center, Kayseri, Turkey

2Erciyes University, Faculty of Dentistry, Department of Oral and Maxillofacial Surgery, Kayseri, Turkey

3Erciyes University, Institute of Science, Department of Biology, Kayseri, Turkey

4Erciyes University, Faculty of Science, Department of Biology, Kayseri, Turkey

5Erciyes University, Faculty of Dentistry, Department of Orthodontics, Kayseri, Turkey

OBJECTIVE

Low-level laser therapy (LLLT) irradiation refers to the use of red-beam or near infrared lasers with a wavelength of 600–1,100 nm and an output power of 1-500 mW. LLLT has been widely used in oral and maxillofacial region for wound healing, biostimulation and pain relief. Among various types of stem cell, mesenchymal stem cells (MSCs) are one of the most common stem cells that are used in cellular therapy. Human adipose tissue provides an easy accessible source of mesenchymal stem cells with considerable advantages. The aim of this study is to investigate the effect of LLLT on viability, apoptosis and senescence of adipose derived MSCs.

METHODS

Adipose derived MSCs were characterized for mesenchymal surface markers using a flow cytometry system. Third-passage cell cultures were irradiated with OsseoPulse® LED device, 618-nm wavelength and 20-mW/cm² output power irradiation. Each well treated directly over the culture plate for 10, 20, 45 and 90 seconds, respectively, at zero and 48 hours, and the cells were analyzed for cell

viability, apoptosis and senescence at zero, 24, 48, and 72 hours after the first laser irradiation. Cell viability was evaluated by Muse Cell Proliferation Assay Kit. Cells were collected and counted at 0., 24., 48., and 72. hours of post plating. Apoptotic cells were detected using annexin V assay. The percentage of senescent cells was calculated by the number of blue β galactosidase-positive cells in different microscope fields by using a software analysis programme. Differences between groups at each time point were statistically analyzed using the t-test. A level of significance of 5% was adopted ($p < 0.05$).

RESULTS

No significant difference in cell viability was observed in 45 and 90 seconds groups. However 10 and 20 seconds irradiation have positive effect on cell viability in 72. hours. A tendency towards lower early apoptosis was observed in 45 and 90 seconds irradiated groups after 24, 48 and 72 hours when compared with the control. However no significant difference in late apoptosis between groups.

CONCLUSION

LLLT has positive effects on cell viability and prevent the early apoptosis. Duration of irradiation may affect the senescence of cells. However, further studies are needed to standardize the laser parameters and to test other cell types to improve the yield of cells in culture.

Keywords: low level laser therapy, stem cell, senescence

PP-015

'OMFS SHO' App: A Smarter Way to Learn!

Junade Mirza, Ahmad Abou-Foul, Vivek Ramamoorthy, Daljit Dhariwal, Pradeep Anand
Department of Oral & Maxillo-facial surgery, Oxford University Hospitals, Oxford, UK

OBJECTIVES

In August 2013, the specialist surgery (SS) rota at the our regional tertiary referral centre had been revised, encompassing a new on call cross-cover for the junior doctors, which lead to a shift pattern fragmentation and increased work load on junior doctors. Our main objective was to assess the need for, and potential benefits, of a virtual learning and clinical guidance tool, covering common oral & maxillofacial surgery (OMFS) presentations. The aim was to enhance induction process, increase the confidence and competence of the junior doctors covering out of hours (OOH) OMFS on call.

METHODS

An initial survey completed by all SS junior doctors. The survey contained 15 questions, and was based mainly on dichotomous questions and 5-point Likert scales. The questionnaire assessed criteria & standards expected. Junior doctors self-reported their views on their knowledge and confidence taking OMFS OOH referrals. We designed a free mobile App for Android and iOS operating systems, called 'OMFS SHO' App, and released it after the questionnaire, which was repeated one month afterwards. Results were analysed using paired t test statistics and are reported as pre- and post-App release mean scores (\pm standard Deviation), with $p < 0.05$ considered statistically significant.

RESULTS

The majority of junior doctors involved reported dissatisfaction with the induction, OMFS junior doctors' handbook's accessibility and poor confidence covering OMFS OOH. Participants rated their confidence in recognising clinical signs and symptoms of common OMFS emergencies with an average score of 2.73 (\pm 1.16) pre-App release, and 4.14 (\pm 0.66) post-App release ($p=0.0001$). Their confidence in the management of these emergencies pre-App release was poor with average score was 2.8 (\pm 1.37), improved to 4.0 (\pm 0.88) post-App release, $p=0.0098$. 85% of participants also reported to have saved time during their busy on-calls, by using the App to access antimicrobial guidelines and making decisions regarding management plans.

CONCLUSIONS

Recent technological advancements have played a pivotal role in medical education with a view to improving patient care. As the demands of clinical practice increase, the influx of technology in modern hospital care has paved the way for learning aids to become widely available. We have devised a smartphone application, entitled 'OMFS SHO', assisting with junior doctors' induction process, supporting them with their on call shifts and ultimately increasing patient safety.

Keywords: Learning tool, Induction, on call, cross-cover, education, Juniors

PP-016

Apical Papilla Stem Cells from Supernumerary Tooth and Comparative Characterization with Wisdom Tooth

Zeynep Burçin Gönen^{1,2}, Abdullah Ekizer³, Selami Demirci⁴, Ayşegül Doğan⁴, Aydan Sardoğan⁴, Fikrettin Şahin⁴, Alper Alkan²

¹Erciyes University, Genome and Stem Cell Center, Kayseri, Turkey

²Erciyes University, Faculty of Dentistry, Department of Oral and Maxillofacial Surgery, Kayseri, Turkey

³Erciyes University, Faculty of Dentistry, Department of Orthodontics, Kayseri, Turkey

⁴Yeditepe University, Faculty of Engineering and Architecture, Department of Genetics and Bioengineering, Istanbul, Turkey.

OBJECTIVES

A variety of mesenchymal stem cell (MSC) populations such as dental pulp stem cells (DPSCs), stem cells from human exfoliated deciduous teeth, periodontal ligament stem cells, stem cells from root apical papilla, dental follicle stem cells and gingival stem cells have been successfully isolated from human oral tissues. The purposes of this study are to present the isolation of supernumerary tooth apical papilla stem cells (ST-APSCs) from a non-syndromic male patient with multiple supernumerary teeth, for the first time in the literature and to compare in vitro characterization with DPSCs derived from tooth germs of young adults.

METHODS

The supernumerary tooth in the right maxillary premolar region was extracted under local anesthesia and delivered to the laboratory for ST-APSCs isolation. ST-APSCs were characterized for mesenchymal surface markers (CD45, CD90, CD105, CD166, CD14, CD44, CD29 and CD73) using a flow cytometry system. Cells were differentiated into osteo-, chondro- and adipogenic cell types. RT-PCR reaction using SYBR Green staining method was used to determine mRNA levels of Collagen type-I (Col I), Fatty acid binding protein-4 (FABP4) and Collagen type-II (Col II) genes. Von Kossa staining was performed to show mineralization and calcium deposition of differentiated cells as a marker of osteogenic transformation. Alcian blue staining was performed to examine chondrogenic differentiation levels of differentiated cells. Oil red staining was conducted to show lipid vesicles as a marker of adipogenic differentiation.

RESULTS

DPSCs isolated from wisdom tooth showed higher expression of mesenchymal surface markers than those isolated from ST-APSCs. When DPSCs and ST-APSCs were cultured in differentiation medium promoting transformation to osteo-, chondro- and adipo-genic lineages, both showed calcium mineralization, chondrogenic mass formation and lipid accumulation. However, DPSCs derived from wisdom tooth exerted more differentiation potential to osteo- and chondro-genic cell types. At the molecular level, DPSCs showed higher expression of differentiation related marker genes.

CONCLUSIONS

This report described the isolation of apical papilla stem cells from supernumerary tooth for the first time in the literature and their stem cell potential was compared with DPSCs derived from wisdom tooth germs. Although ST-APSCs are able to differentiate into three cell lineages: osteo-, chondro- and adipogenic; they are less potent compared to DPSCs derived from tooth germs. As waste materials of dental applications, supernumerary teeth could be used to isolate MSCs which is not related with any ethical concerns.

Keywords: Supernumerary tooth, stem cell, dental pulp, differentiation, apical papilla

PP-017

General Approach of Odontogenic Abscess in the Treatment and Cost Evaluation

Aylin Çalış¹, Banu Özveri Koyuncu¹, Kerem Öztürk², Ali Mert³, Cem Bilgen²

¹Department of Oral Surgery, School of Dentistry, Ege University, İzmir, Turkey

²Department of Otolaryngology, School of Medicine, Ege University, İzmir, Turkey

³Department of Statistics, School of Science, Ege University, İzmir, Turkey

PURPOSE

The purpose of this study was to evaluate the correlation between age, sex, symptoms, treatment, length of hospital stay and hospital costs with severe odontogenic infections patients in six-year period.

5-8 November 2014 - Harbiye Military Museum & Cultural Center - İstanbul / Turkey

MATERIAL-METHOD

This study was carried on thirty patients referred to Ege University, Faculty of Medicine, Otolaryngology Department with complaints of odontogenic abscess. Parameters such as age, sex, symptoms, systemic disease, imaging techniques, treatment methods, hospital length of stay, and hospital cost were analysed statistically.

RESULTS

The patients consisted of 12 female and 18 male. The mean age was 39. Antibiotics were used in all, abscess drainage was performed mostly. The hospital length of stay were 8.1 days. Systemic disease and hospital length of stay relationship was statistically significant.

CONCLUSION

The treatment of severe odontogenic infection for inpatients units constitute a high cost in hospitals. For these reasons, preventive and routine dental care should be given importance.

Keywords: severe odontogenic abscess, hospital length of stay, hospital cost, life- threatening complication

PP-018

Inverted and Impacted Second Premolar: A Report of a Rare Case

Berkay Tolga Süer¹, Ersin Yıldırım², Fethi Atıl³

¹GATA Haydarpaşa Eğitim Hastanesi, Diş Hekimliği, Ağız, Diş ve Çene Cerrahisi, İstanbul, Türkiye

²GATA Haydarpaşa Eğitim Hastanesi, Diş Hekimliği, Ortodonti, İstanbul, Türkiye

³Kırıkkale Üniversitesi, Diş Hekimliği Fakültesi, Ağız, Diş ve Çene Cerrahisi AD., Kırıkkale, Türkiye

AIM

A few rare cases of inverted impaction of mandibular premolars are reported. Even though prevalence of impacted premolars in the Anatolian population has been reported, inverted ones have not been quantified. The aim of this study is to report a rare unilateral impacted and inverted second premolar tooth.

CASE

A 22-year-old male patient was referred to department of oral and maxillofacial surgery at the GATA Haydarpaşa Teaching hospital with a complaint of pain at the right third molar region. In the intraoral examination, there was a big cavity at the right mandibular third molar. Panoramic radiograph (OPG) was taken to evaluate the roots of the third molar tooth. OPG incidentally revealed an inverted and impacted left second premolar at the inferior border of the body of the mandible. The patient has been informed about the possible consequences of the planned surgery, but he refused for the removal of the impacted tooth.

5-8 November 2014 - Harbiye Military Museum & Cultural Center - İstanbul / Turkey

CONCLUSION

The removal of the inverted tooth is more complex than that of only impacted tooth. The surgeon be aware of the risks and benefits of removal of the premolars and must weigh between them to decide whether or not proceed with the surgery.

Keywords: Impacted; inverted; premolar

PP-019

Flapless Implant Surgery with Immediate Loading of Maxillary Central Incisor

Mustafa Dag, Umit Karacayli

Department of Oral and Maxillofacial Surgery, Gulhane Military Medicine Academy, Ankara, Turkey

OBJECTIVES

Flapless surgery and immediate loading are the most popular topics in implantology because of that it makes possible to give the patient an esthetic appearance just after the surgery. The aim of this report was to describe the case of a 25-year-old man with missing the maxillary left central incisor and his treatment by immediately restored dental implant, placed using flapless surgery.

CASE

A 25-year-old man with missing the maxillary left central incisor was referred to us for implant treatment. After three-dimensional radiological examination, flapless surgery and immediate loading was deemed appropriate. The implant placement performed under local anesthesia with excellent primary stability. It was restored with a ceramic crown without centric occlusion in a few hours.

RESULTS

Nearly two years after the implant placement, symptoms such as mobility and bone loss were not observed and patient was satisfied as the first day.

CONCLUSION

Immediate loading has become a widely reported practice in implant dentistry and lots of studies confirmed positive clinical and radiographic outcomes of an immediate-loading treatment protocol that included flapless surgery. This case report bears out the use of single implants for replacing a missing anterior tooth where esthetic is a priority.

Keywords: Flapless Implant Surgery, Immediate Loading, Dental Implant

5-8 November 2014 - Harbiye Military Museum & Cultural Center - İstanbul / Turkey

PP-020

Onlay Autogenous Bone Grafting from Symphysis Area and Implant Placement of Anterior Maxilla with Alveolar Defect and Insisive Canal Cyst: A Case Report

Sinan Yasin Ertem

Department of Oral Maxillofacial Surgery, Kırıkkale University, Kırıkkale, Turkey

PURPOSE

The purpose of this study is to evaluate autogenous onlay block bone grafting harvested from symphysis area on patient who has insisive canal cyst in anterior maxilla and insufficient alveolar width for rehabilitate with implant supported prosthesis.

Case Presentation: 20 years old male patient was referred to our clinic for early lost of his tooth and has defect on the alveolar process of maxilla anterior. The patient was informed about surgery protocol before enucleation of insisive canal cyst and onlay bone grafting derived from symphysis area. Two pieces of block graft harvested from symphysis area and fixed to the edentulous alveolar process with two mini screw for upgrading the horizontal width of the alveolar ridge. After waiting 6 months for recovering the surgical site and conjunction with block graft and alveolar ridge, the patient was operated for implant surgery. Both of the mini screws are removed from grafting site. 6 months later, healing cap for osseointegrated implant adapted and prosthetic procedure completed.

RESULTS

Symphysis block grafting for the patient is successfully merged and combined with alveolar ridge without any complications and widening the alveolar ridge has been done efficiently.

CONCLUSION

Autogenous block grafting method for patients who have defect on the alveolar ridge or lacking on the alveolar structure for any reason yield very good results, especially before implant insertion.

Keywords: Bone graft, symphysis, implant

PP-021

Alveolar Ridge Expansion with Cortical-Splitted Autogenous Bone Blocks

Berkay Tolga Süer¹, Metin Kızılkaya², İsmail Doruk Koçyiğit³

¹Department of Oral and Maxillofacial Surgery, Gulhane Military Medical Academy Haydarpaşa Teaching Hospital, Istanbul, Turkey

²Department of Oral and Maxillofacial Surgery, Hospitadent Mecidiyeköy, Istanbul, Turkey

³Department of Oral and Maxillofacial Surgery, School of Dentistry, Kırıkkale University, Kırıkkale, TURKEY

Intramembranous bone grafts are considered to undergo less resorption than the endochondral bone grafts; therefore they are thought the gold standard in alveolar crest augmentation. The mandibular ramus grafts provide mainly dense cortical graft and yield to some advantages over mandibular symphysis graft such as, short healing period, the lesser neural damage risk and morbidity and more bone available for harvesting. A 52-year-old female patient was referred to the Oral-Maxillofacial Surgery Clinic at the GATA Haydarpaşa Teaching Hospital, Istanbul. The chief complaint of the patient was partial edentulouism and not being able to use partial removable denture. Upon clinical and radiographic examination, it was noted that left maxillary edentulous area was not suitable for implant insertion due to severe crest width deficiency. Under local anesthesia adequate cortical ramus graft was harvested from the left external oblique ridge using ultrasound surgery. The ramus graft was splitted horizontally using Frios® MicroSaw system to obtain thin cortical pieces. Having obtained 3-4 mm gap between the cortical-split bone graft and the residual alveolar crest, the cortical bone pieces were then secured to the maxilla horizontally with 6 miniscrews (10 X 1.1 mm) using Meisenger Bone Fixation system. The gap between 1 mm thick cortical ramus pieces and recipient alveolar crest was filled with autogenous cortico-cancellous bone graft that harvested from the same donor site using bone scraper. An allograft and resorbable collagen membrane were placed over the autogenous graft. The healing period was uneventful. Six months after the augmentation surgery, clinical and radiological examination was revealed that the attempt for alveolar crest widening was successful. The mucoperiosteal flap was raised and 5 ITI bone level implant were inserted without any intraoperative complication. Using ramus bone graft as split-container in conjunction with autogenous particulate graft was noted working efficiently in pre-implant augmentation surgery and yield predictable outcome for augmenting alveolar width deficiencies for implant placement.

Keywords: Ramus graft; autogenous bone; dental implant; bone fixation

PP-022**Rehabilitation of Severe Atrophic Edentulous Jaws with ALL-on-Four Implant System: 2 Cases**

Emine Tuna Akdoğan¹, Faysal Uğurlu¹, Pelin Karasu², Atilla Sertgöz²

¹Department of Oral and Maxillofacial Surgery, Faculty of Dentistry, Marmara University Istanbul, Turkey

²Department of Prosthodontic, Faculty of Dentistry, Marmara University Istanbul, Turkey

The All-on-Four concept uses the simplicity of posterior tilted implants to create a full-arch restoration that can be less clinically invasive for patients. The design consisted of a fixed prosthesis supported by four endosseous implants: two axial implants in the anterior segment and one distal implant on each posterior segment tilted posteriorly. All implant apices are to engage cortical bone anterior to the mental foramina. The increased anterior/posterior spread from the tilted implants generally provides first molar occlusion for patients with short cantilevered segments. The All-on-Four concept provides a predictable method to restore edentulous jaws. The high implant survival rates relative to edentulous jaws, patient gender, and implant orientation when following the All-on-Four protocol suggests that the procedure is a viable alternative to restore dentitions for edentulous patients.

The introduction of tilted implants has provided a significant alternative for restoration of maxillary and mandibular posterior segments without bone grafting. Posterior tilting of distal implants will reduce cantilever lengths, broaden the prosthetic base, and improve implant-to-bone surface areas because longer implants can be used.. patients are able to receive fixed, full arch restorations the same day as implant placement, providing esthetics, comfort, and limited function during the 3-to 6 month healing phase, all while achieving high implant survival rates, Traditional treatment plans typically called for a large number of implants placed in fairly vertical on-positions throughout the entire arch but with the all on four concept uses only four implant to create full arch restoration. Lower cost, lower risk and short treatment time are the other benefits of the system. It can be applied safely either opposite arch is removable prosthesis or fixed dentures (implant supported fixed restoration or tooth supported fixed restorations) as well. In this presentation, the surgical and prosthetic procedures of the 2 cases with different type indications of All-on-four system are going to be showed. Also the advantages, disadvantages and complications of this system will be discussed.

Keywords: implants, edentulous jaws, ALL-on-Four

PP-023

Foreign Body Reaction after Dental Implant Treatment: A Rare Clinical Complication

Kübra Titirini¹, Ismail Doruk Koçyiğit¹, Fethi Atıl¹, Umut Tekin¹, Tolga Berkay Suer²

¹department of oral and maxillofacial surgery, kırıkale, turkey

²GATA haydarpaşa eğitim hastanesi diş servisi, department of oral maxillofacial surgery, istanbul, turkey

OBJECTIVE

Foreign bodies reported to be found in the maxillary bone include burs, dental impression material, root-filling materials, needle. Although some objects remain asymptomatic, others result in foreign body reactions. Inflammatory reaction to implanted or non-implanted materials is known as the foreign body reaction (FBR) and is characterized by 3 distinct phases: onset, progression, and resolution. The accidental displacement of foreign bodies to maxillary bone an unusual complication in dental clinical practice. This report present a case that dental impression materials, introduced into maxillary extraction socket after implant treatment.

METHODS

This case report describes prosthodontic complications resulting from the materials used for maxillary impression was pushed into the bone through extraction sockets after implant surgery. Also this report explain the treatment following these complications.

RESULT

The foreign body which was in the apical side of the postextraction socket wall trapped by inflamed granulation tissue was retrieved.

CONCLUSION

Dental impression materials can be introduced to the bone through insufficient healed extraction wound. After evaluating medical history of the patient, the surgeon must treat this condition to prevent potential serious complications.

Keywords: implant, socket, impression, foreign

5-8 November 2014 - Harbiye Military Museum & Cultural Center - İstanbul / Turkey

PP-024

Factors Associated with Dental Implant Survival: A 38-Month Retrospective Analysis

Sinan Yasin Ertem¹, Seda Ünal²

¹Department of Oral and Maxillofacial Surgery, Kırıkkale University, Kırıkkale, Turkey

²Department of Periodontology, Private Uzmandent Dental Hospital, Kayseri, Turkey

The aim of this study is to determine whether implant survival rates are affected by known risk factors that may contribute to implant failure and potential risk indicators associated with implant failure.

In the present retrospective cohort study, data were collected from 206 patients (91 men, and 115 women) who received a total of 561 single or multiple dental implants. Patients ranged in age from 20 to 84 at the time of implant placement. The follow-up examination included clinical evaluation of implant stability, function, signs of inflammation, and radiographic assessment of marginal bone loss using panoramic radiographs. Data were recorded regarding the success and survival rates of the implants. Implant failure was defined according to the criteria of Albrektsson et al: implant mobility on clinical examination, persistent pain, signs of infection, presence of peri-implant radiolucency, progressive bone loss, or the implant could not be used for prosthetic rehabilitation any more.

Overall, 17 of the 561 sand-blasted surfaced implants failed (96.97% survival rate) in 12 (5 men, and 7 women) patients during the follow-up period (ranged from 3 to 38 months) after implant placement. Eight of the failed implants were placed in the maxilla, and nine in the mandible, with percentages of 52.9% and 47.1% anterior (between canines) and posterior implants, respectively. Implant failures were concentrated during the healing phase (8 implants) and after loading phase (9 implants). Eight of 9 loaded implants were restored with overdentures, whereas the remaining 1 was restored with fixed partial denture. One implant failed due to the abutment-implant disharmony. Smoking was reported by 8 patients and non-insulin-dependent diabetes mellitus by 2 patients of having failed implants. Eight, 3, and 6 out of 17 failed implants were placed in Type 1, Type 3, and Type 4 bone, respectively, according to the bone type classification described by Lekholm and Zarb. No radiographic marginal bone loss or any other clinical signs of failure occurred in the 544 surviving implants. These were defined as successful according to the above criteria.

Bone quality is significant when considering an implant placement site, and secondly there appears to be other factors in the success rates of implants, including smoking habits, periodontal and systemic (particularly diabetes mellitus) health of patients, appropriate prosthodontic planning, as well as the length of osseointegration of implants with the surrounding bone before loading.

Keywords: dental implants, failure, survival, success

PP-025**A 3-Year Evaluation of the Peri-Implant Parameters of Immediate Implants Placed into Fresh Extraction Sockets**Seda Ünal¹, Sinan Yasin Ertem²¹Department of Periodontology, Private Uzmandent Dental Hospital, Kayseri, Turkey²Department of Oral and Maxillofacial Surgery, Kırıkkale University, Kırıkkale, Turkey

The aim of the present study is to consider the correlation between the keratinized mucosa and the long-term maintenance of endosseous dental implants placed immediately after tooth extractions.

Forty-two patients (19 men, 23 women) requiring extraction of one or more teeth and implant placement immediately after extraction were enrolled in this study. Under local anesthesia, teeth were atraumatically removed and the extraction sockets were debrided. A total of 65 dental implants (24 in the anterior mandible, 12 in the posterior mandible, 14 in the anterior maxilla, and 15 in the posterior maxilla) were placed using a one-stage approach. Based on the amounts of keratinized mucosa (KM), implants were categorized as follows: $KM \geq 2$ mm (group I) and $KM < 2$ mm (group II). Clinical parameters (probing depth and gingival index) and marginal bone levels were followed at 3 years after implant placement. Comparisons between group I and II values were performed by the student two-tailed t test. Bone type, implant length and width, type of prosthodontic restorations, as well as site of implants placed were also recorded.

The average interval between implant insertion and abutment connection was 4.07 ± 1.35 months. At 3-year follow-up, a survival rate of 100% was reported for all implants. The mean values of group II were significantly higher ($P < 0.05$) than group I for the peri-implant gingival index parameters (group I: 0.29 ± 0.06 ; group II: 0.33 ± 0.11). No statistically significant difference was recorded according to the mean probing depth values between groups ($P > 0.05$). Similarly, for mean bone loss values, statistically non-significant differences were reported between groups.

At 3-year follow-up, the results suggested that the presence of mid-buccal KM is not a critical factor either in the maintenance of radiographic bone level or probing depth parameters around immediately placed implants into fresh extraction sockets. Conversely, less width of keratinized mucosa is significantly associated with more gingival inflammation.

Keywords: immediate, dental implant, keratinized mucosa, peri-implant parameters

PP-026

Flapless Implant Surgery Reduces Post-Surgical Complaints in the Elderly: Report of a Case

Nilüfer Bölükbaşı, Volkan Arısan

Department of Oral Implantology, Istanbul University, Istanbul, Turkey.

OBJECTIVE

With global awareness and demand for dental implants for the treatment of different types of edentulism, an important portion of the elderly population has become candidate for dental implant treatment. Unfortunately, there are a number of medical conditions that typically need elective oral surgery, and therefore preclude the placement of dental implants. Elderly patients with these conditions such as heart disease, uncontrolled diabetes, hypertension or compromised wound healing need special care. Operation time and surgical trauma should be reduced with careful preoperative planning. In the past, the placement of implants was solely performed following the exposure of a mucoperiosteal flap extending beyond the margins of the edentulous crest. With the help of recent advances in the radiographic imaging and computer-assisted stereolithographic (SLA) techniques, flapless insertion of multiple implants has become possible with an advantage of reduced surgical duration and postoperative morbidity.

In this case presentation, the steps of treatment planning, surgery and prosthetic rehabilitation of an edentulous elder patient will be presented.

METHODS

A 72-year-old female patient applied to the Faculty of Dentistry at Istanbul University. She had a type II diabetes mellitus and hypertension. She had complaints of chewing difficulty and retention of her prosthesis. The eligibility of the patient for SLA surgical template-guided flapless implant surgery was decided according to the availability of sufficient bone thickness and attached mucosa. A barium sulfate scan prosthesis representing the final prosthetic outline was produced and checked in situ to confirm the correctness of the tooth setup, esthetic appearance, and phonetics. Then, the patient was forwarded for cone beam-computed tomographic imaging. The final data were saved and sent to the SLA guide production facility.

All surgical procedures were carried out under local anesthesia. The SLA guide was positioned in the mouth. Mucotome was used to remove the mucosae over the planned implant recipient. Then, the osteotomy was completed using the special drill kit. 6 implants were inserted through the SLA guide. The osteosynthesis screws were detached and the SLA guide was removed from the mouth. All implants were left to transmucosal healing.

RESULTS

All implants were osseointegrated. Three months after the surgery, fixed metal fused to ceramic restorations were fabricated. The patient was satisfied with the esthetic and functional result.

CONCLUSION

Flapless implant surgery may be beneficial to elderly patients at risk of certain diseases by decreasing the duration and the invasiveness of the surgery.

Keywords: dental implant, flapless surgery, computer-assisted stereolithography

PP-027

Maxillary Reconstruction Using Iliac Bone Graft for Bilaterally Sinus Augmentation Combined with Lateral and Vertical Onlay Bone Grafting: A Case Report

Hakan H. Tüz, Serkan Kiriş, Onur Koç, Göknur Topaloğlu, Eren Meral
Department of Oral and Maxillofacial Surgery, Hacettepe University, Ankara, Turkey

Progressive loss of the alveolus with aging leads to defects in horizontal and vertical dimensions. In long term; edentulous regions of posterior maxilla becomes severely atrophied because of sinus pneumatization and horizontal and vertical resorptions. And a severely atrophied maxilla causes serious limitations for implant surgery. To reconstruct the anatomy, bilaterally sinus floor augmentation should be combined with lateral and vertical alveolar ridge augmentation in an osteoplastic procedure. To harvest enough autogenous bone material for both bilaterally sinus lifting areas and vertical and horizontal augmentation, iliac crest allows precise functional and aesthetic restoration of the alveolar region and a well-done sinus floor augmentation with cancellous bone rich content.

In this case; a 64-year male patient referred to our clinic for the implant treatment of maxillary premolar and molar region. Because of severe atrophy of the alveolar region, cortico-cancellous iliac bone graft was needed for reconstruction of defected areas. Bilateral sinus augmentation was performed using particulate cancellous iliac bone graft. And bilateral defected premolar regions were grafted with onlay cortico-cancellous block grafts -fixed with two monocortical mini screws- laterally and vertically. After three months of augmentation, the implants were placed successfully.

Keywords: maxillary sinus, iliac graft, augmentation, implant

PP-028

Case Report: Recurrence of Central Giant Cell Granuloma after Surgery

Ali Hanttash Abu Hanttash¹, Ümit Kamal Aktaş¹, Hakan Eren², Timor Songür¹, Serkan Dadakoğlu¹

¹Department of oral surgery, Ankara university, Ankara, Turkey

²Department of oral radiology, Ankara university, Ankara, Turkey

Central giant cell granuloma (CGCG) is a benign lesion of the jaws with an unknown etiology. Clinically and radiologically, a differentiation between aggressive and non-aggressive lesions can be made. The incidence in the general population is very low and patients are generally younger than 30 years. Histologically identical lesions occur in patients with known genetic defects such as cherubism, Noonan syndrome, or neurofibromatosis type 1.

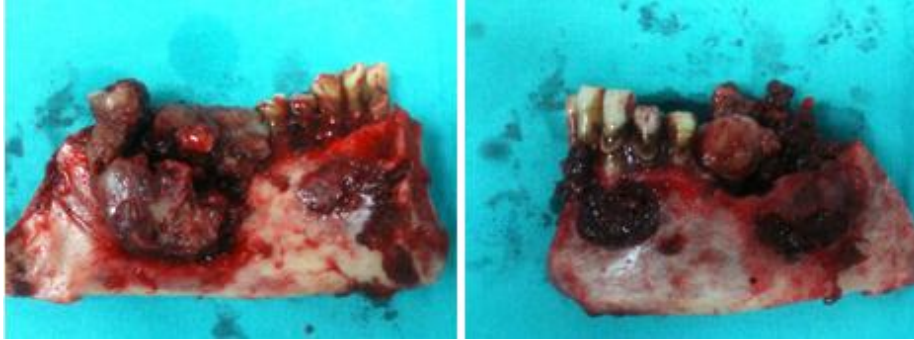
In most cases the lesion presents as a painless, slow-growing swelling of the jaw. Pain and sensory disturbances are rare. Intraorally a swelling with sometimes a bluish-brown aspect can be observed. Displacement of teeth occurs frequently and can lead to a malocclusion.

CGCG can be treated with several therapies, including surgical excision, simple curettage and en bloc resection as well as intralesional corticosteroid injections, calcitonin intradermal injection or nasal spray, and alpha-interferon -2a (IFN- α 2-a) injections. All these treatments have had varying success. In the literature, recurrence rates range from 11.0 to 49.0% or greater, depending on the behavior and/or treatment.

CASE-REPORT: A 53-year-old male was referred to the Service of Oral Surgery at Ankara university. Clinical examination revealed no facial asymmetry, intraoral examination showed a swelling in left side of the mandible. The patient did not experience pain, restrictions of mandibular movements, or occlusal disturbances. There was no contributory medical history, and no lymph node involvement was detected. The results of all hematological studies were within normal limits. Laboratory values for serum calcium, phosphorus, alkaline phosphatase, and parathyroid hormone (PTH) were within normal limits, ruling out the brown tumor of hyperparathyroidism. The panoramic radiograph revealed a well-circumscribed, multilocular, corticated radiolucency of the left mandibular body. No tooth displacement or resorption of the root apices was present. The CT scan revealed an expansile lesion perforating the cortical bone. Surgery was performed under general anesthesia. submandibular incisions were made. the lesion was removed en bloc with a bony security margin of 1cm using a reciprocating saw. After 5 month the patient had anew intra oral swelling at the right side of mandible radiological examination refereed new recurrence of CGCG in the symphysis and right side of mandible, there was another surgical operation the lesion was removed en bloc with a bony security margin of 1cm using a reciprocating saw.

Keywords: Central giant cell granuloma, resection, mandibular body

CG CG was removed en bloc with a bony security margin of 1 cm



PP-029

Facial Cutaneous Leishmaniasis Braziliensis

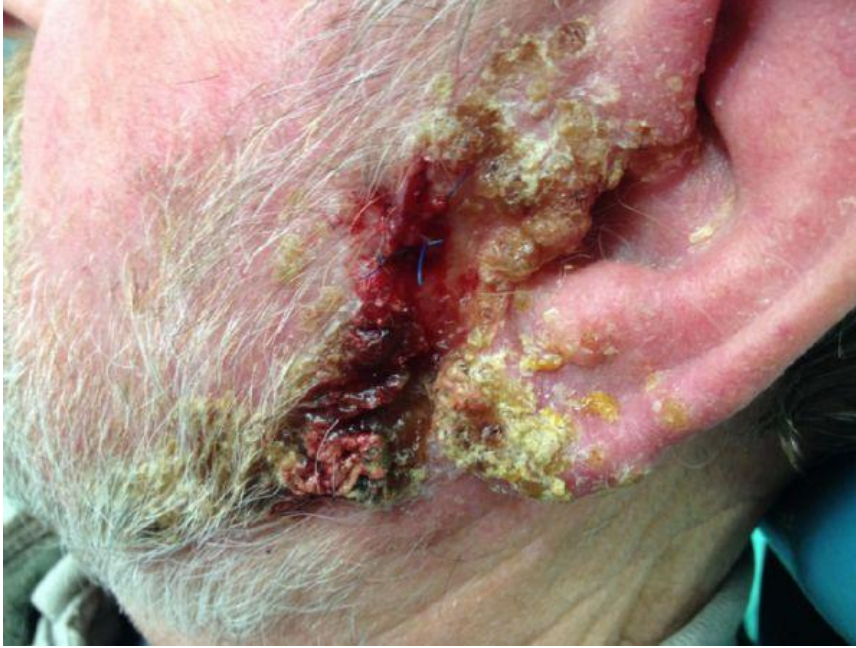John Collin, Mark Singh

Department of Oral and Maxillofacial Surgery, Gloucestershire Royal Hospital, Gloucester, UK

We describe a rare case of cutaneous Leishmaniasis Braziliensis affecting the face. This rarely seen disease can present a diagnostic dilemma, requiring careful history taking and close liaison with microbiology and infective disease colleagues.

Keywords: Leishmaniasis, orofacial pathology

Lesion at presentation



Cutaneous Leishmaniasis affecting the face

PP-030

Intralesional Injections for the Treatment of Central Giant Cell Granuloma (CGCG): A Case Report

Metin Şençimen¹, Tamer Zerener¹, Dilber Çelik¹, Gürkan Raşit Bayar¹, Hasan Ayberk Altuğ¹, Berkay Tolga Suer²

¹Gulhane Military Medical Academy, Department of Oral and Maxillofacial Surgery, Ankara, TÜRKİYE

²Haydarpasha Military Medical Academy, Department of Oral and Maxillofacial Surgery, Ankara, TÜRKİYE

INTRODUCTION

Central giant cell granuloma (CGCG) of jaws is a benign and proliferative intraosseous lesion. It generally effects children and young adults. There are many modifications of CGCG treatment. Traditional treatment of the CGCG is surgical curettage and resection. Most frequently therapy in surgical curettage has a big recurrence rate in large lesion, alternative non-surgical approach is intralesional injections of medicals.

CASE

Here we report a case of conservative treatment of CGCG in posterior-mandible. 67-year -old female patient who have pain, swelling and asymmetry in left mandible ramus. At end of the clinical examination and radiographic inspection, we diagnosed radiolucent lesion and number of 37 teeth's apex had resorption. Afterwards, intraosseous lesion involving the apex of the tooth belonging to the incisional biopsy's report show that CGCG. Hematological tests are analysed for hyperparatriotism

and Brown tumour to exclude the possibility of clinically. Blood test showed that parathyroid hormone and serum calcium concentrations were normal. For the treatment intralesional kenacort-A and jetokain injections were used into the bone cavity. Injections were performed for 9 sessions.

CONCLUSION

Two months later from this therapy we observed newly formed bone in the lesion. Selected treatment to the patient is thought to be promising.

Keywords: Giant cell tumour, granuloma, intralesional injection

PP-031

Surgical Management of a Monostatic Fibrous Dysplasia: A Case Report

Metin Şençimen¹, Tamer Zerener¹, Gamze Arıcı¹, Sencer Seçer¹, Gürkan Raşit Bayar¹, Berkay Tolga Suer²

¹Gulhane Military Medical Academy, Department of Oral and Maxillofacial Surgery, Ankara /TÜRKİYE

²Haydarpasha Military Medical Academy, Department of Oral and Maxillofacial Surgery, İstanbul/TÜRKİYE

INTRODUCTION

Fibrous dysplasia is a non-neoplastic developmental hamartomatous disease of the bone. It is characterized by an abnormal mixture of fibrous and osseous elements in the interior of affected bones that can cause bone deformities with pain and pathological fractures in one or several bones. With an incidence of 1:4000-1:10,000 it seems to be a rare disease. Here we represent the surgical approach to a young fibrous dysplasia patient.

CASE

A 20-year-old male patient referred to our clinic from Ear, Nose and Throat (ENT) Department with a complaint of a swelling at the right region of the upper jaw. ENT Department wanted to us to investigate if the swelling was deriving from any dental infection. After intraoral and radiologic examination we identified two teeth that cause dental infection but we observed by ortopantomography that the lesion was radiopaque and its borders was extending to the zygomatic region. We thought that it was not an inflammatory lesion an our preliminary diagnosis was fibrous dysplasia. Surgery was performed in order to correct the contour disorder. The biopsy specimen was sent for histopathological examination so it was confirmed that the lesion was fibrous dysplasia

CONCLUSION

Our patient was satisfied with the aesthetic results of the surgery and we still keep the patient under control by periodic checks.

Keywords: Fibrous Dysplasia, Craniofacial Bone Lesions

PP-032

Unusual Complication after Keratocystic Odontogenic Tumor Surgery

İbrahim Macit¹, Umut Tekin¹, Fethi Atıl¹, İsmail Doruk Koçyiğit¹, Berkay Tolga Süer²

¹Kırıkkale University Dentistry Faculty Department of Oral and Maxillofacial Surgery Kırıkkale - TÜRKİYE

²GATA Haydarpaşa Department of Oral and Maxillofacial Surgery İstanbul - TÜRKİYE

Keratocystic odontogenic tumors (KCOTs) of the jaws have been the most controversial pathologic cystic lesions in the maxillofacial region. Considerable debate still exists regarding the recurrence and morbidity associated with the various treatment modalities of these tumors. The surgical treatment options range from conservative; marsupialization and enucleation, with and without the use of adjunctive treatments. Although more aggressive treatment modalities like resection and aggressive curettage can be performed due to the histopathologic type of the lesion. After surgical treatment many complications may occur like infections, nerve injuries, recurrences and fractures.. In this case report fracture of a mandible from the pathologic lesion line after enucleation and aggressive curettage of the lesion. Prevention and the treatment of this kind of complication will be discussed in the light of the literature.

Keywords: Keratocystic odontogenic tumors pathological fracture

PP-033

Giant Peripheral Osteoma Related with Mandibular Angle: Case Report

Ahmet Hüseyin Acar, Nihat Demirtaş, Suzan Bayer, Nergiz Yılmaz, Hakkı Oğuz Kazancıoğlu
Department of Oral and Maxillofacial Surgery, Bezmialem University, İstanbul, Turkey

INTRODUCTION

Osteomas are benign, slow-growing and osteogenic tumors that sometimes arises from the craniomaxillofacial region. 2005 WHO classification defined osteoma as a benign lesion of mature bone with compact or cancellous bone proliferation. Radiographically they are radiodense, sharply defined, well-circumscribed lesions. These lesions can be central or peripheral in their location. Moreover they are often asymptomatic and incidentally discovered. Craniofacial areas such as sinus, temporal or jaw bones are rarely affected. In the jaws, mandible is more commonly affected than the maxilla. Moreover the angle of the mandible is more frequently involved than the coronoid process or condyle. These lesions may be single or multiple. Multiple jaw osteomas are a frequent component of the Gardner syndrome.

Case Report: A 43 year-old male patient appealed to our clinic with complaint of slowly growing mass in his mandible. On physical examination, an oval, approximately 2x3 cm mass is fixed to the mandible, was palpated in the right cheek. Radiographically it was 2x2 cm, well-defined and

5-8 November 2014 - Harbiye Military Museum & Cultural Center - İstanbul / Turkey

radiopaque on the right angle of the mandible. Under general anesthesia, the lesion is completely removed with a chisel and rotary instruments.

CONCLUSION

The peripheral type of osteoma is common in the mandible. We believe that, giant lesions can affect patients' life quality and regular follow-up is necessary.

Keywords: osteoma, odontogenic tumor, diagnosis

PP-034

A Case Report of Central Giant Cell Granuloma (CGCG): Surgical treatment and Restoration with implant-supported prostheses

Dilber Celik, Metin Sencimen, Tamer Zerener, Gurkan Rasit Bayar, Hasan Ayberk Altug
Gulhane Military Medical Academy, Department of Oral and Maxillofacial Surgery, Ankara, TÜRKİYE

INTRODUCTION

Central giant cell granuloma (CGCG) of jaws is a benign and non-neoplastic proliferative lesion of unknown etiology. It usually affects children and young adults. It occurs commonly in the mandible. The most common treatment is surgical curettage.

CASE

Here we reported the case of a 14-year old male patient who has unilateral pain, swelling, difficulty in eating and paresthesia on right lower lip. There was no history of trauma and dental problem. During the clinical examination, we saw that the lesion was firm and mandibular first molar was over erupted. MRI showed radiolucent lesion was expanding in the right mandible from mandibular first premolar to second molar, local bone destruction nearly 48mmx31mmx20mm at size and lower limit of mandible was expanded. As a result of fine-needle biopsy of the lesion it was compatible with CGCG belonging to the cytologic findings were observed. The patient underwent surgical curettage of the lesion through an intraoral approach under general anesthesia and patient's mandibular first molar was pulled, first premolar and second molar tooth were done endodontic treatment and two years after the surgery we observed idiopathic bone cavity at the lesion site. So we reoperated the patient in order to the curettage and we enucleated the mandibular first and second premolars and second and third molars. Two years after the 2nd operation, lesion side was restored with implant-supported prostheses.

CONCLUSION

The patient was satisfied with the functional and aesthetic results of the treatment and his periodic follow up is still remaining.

Keywords: Giant cell granuloma, jaw bone, swelling of corpus mandible

5-8 November 2014 - Harbiye Military Museum & Cultural Center - İstanbul / Turkey

PP-035

Langerhans Cell Histiocytosis of The Mandible in a Patient with Thrombocytopenia-Absent Radius Syndrome

Ibraz Siddique, Dilip Srinivasan, Sagar Shah

Department of Oral and Maxillofacial Surgery, Queen's Medical Center, Nottingham, United Kingdom

INTRODUCTION

Langerhans' cell histiocytosis (LCH) is a rare condition affecting 1-2 per million adults and rarely presents to Oral and Maxillofacial surgeons. It is a disease of the reticuloendothelial system characterised by abnormal proliferation of histiocytes and ranges from isolated lytic lesions of the bone to a fatal disseminated multisystem disease. The pathogenesis of LCH remains unclear. In the oral and maxillofacial region, the commonest presenting features include localised bone pain, cervical lymphadenopathy, ulceration and loose teeth.

We present a rare case of LCH affecting the mandible in an adult with another known rare disorder known as Thrombocytopenia with absent radius (TAR) syndrome. The radiological and characteristic histopathological images are discussed and the diagnosis and management of this unusual condition is outlined.

Case Report: A 31 year old female attended her General Dental Practitioner (GDP) complaining of pain in her right mandible associated with a loose tooth. She was subsequently referred to the Oral and Maxillofacial surgery department after her GDP noted bilateral large mandibular radiolucencies on her orthopantomogram. The patient suffered from Thrombocytopenia-with absent radius (TAR) syndrome. Further systems review revealed the presence of a dry cough and worsening left hip pain requiring analgesia.

Extra-oral examination revealed no facial asymmetry, trismus, lymphadenopathy or organomegally. Intra-oral examination revealed a healthy appearance of soft tissues with a mobile lower right second premolar.

Histology from the right mandibular lesion was consistent with LCH. Computer tomography (CT) scan of the mandible confirmed marked bone destruction affecting her right and left hemimandible. Positron emission tomography (PET) scanning revealed high metabolic activity in her right and left hemimandible, lungs and left acetabulum.

The patient was managed under a multidisciplinary team and commenced on chemotherapy for 12 months.

DISCUSSION

Although LCH is rare, lesions can present to the Oral and Maxillofacial surgeon. Due to the possibility

5-8 November 2014 - Harbiye Military Museum & Cultural Center - İstanbul / Turkey

of occult multisystem disease, prompt biopsy and diagnosis allows the instigation of timely and effective management. All patients warrant multidisciplinary management.

Although the aetiology of LCH remains uncertain, a case of refractory LCH of the mandible in a 9 year old child with TAR syndrome has been previously reported. Although a genetic link between these two rare disorders has not yet been established, descriptions of additional cases of LCH in patients with TAR syndrome was deemed necessary before a cause and effect relationship could be supported. We report the second known case of LCH in a patient with TAR syndrome.

Keywords: Langerhans; histiocytosis; thrombocytopenia absent radius

PP-036

An Unusual Case of Bisphosphonate Induced Osteonecrosis of the Maxilla

Maryam Azizi, Avan Mohammed, Tun Wildan, Mo Shorafa

Regional Maxillofacial Centre, North West London Hospitals Trust, Watford Road, Harrow, UK HA1 3UJ

INTRODUCTION

The risk of developing bisphosphonate induced osteonecrosis of the jaw (BRONJ) following invasive dental treatment is well documented within literature. However, spontaneous development of BRONJ is more uncommon. We present a case of spontaneous osteonecrosis of maxilla with sequestered dentoalveolar segment into the maxillary antrum.

PRESENTING COMPLAINT

An 81 year old female was referred by her general dentist regarding a firm, inflamed swelling over her left cheek suspicious of malignancy. Intra-orally, there was a 1 cm oral antral communication with discharging pus. Medical history showed that the patient was on long term oral bisphosphonates for osteoporosis.

MANAGEMENT

CT scans of the facial bones revealed a chronic alveolar bone destruction of the left maxilla and an upper left molar floating within the maxillary antrum. The left cheek swelling was incised and drained and the left maxillary antrum was opened up via a Caldwell-Luc approach to retrieve the floating upper left molar tooth. Biopsy of the antral tissues revealed chronically inflamed granulation tissue with spicules of dead bone suggestive of BRONJ. The patient responded well to surgery and post-operative antibiotics.

DISCUSSION

Bisphosphonate induced osteonecrosis of the jaw can be a serious complication following long-term bisphosphonate therapy. This was an atypical presentation of BRONJ with detachment of

dentoalveolar fragment into the maxillary antrum. The presentation of an inflamed maxillary swelling mimic that of a malignancy and this diagnosis needed to be excluded by histology.

Keywords: bisphosphonate-associated osteonecrosis, maxillary antrum, dentoalveolar sequestrum

PP-037

Dentigerous Cyst Associated with an Ectopic Third Molar in the Condylar Region: A Case Report

Mehmet Melih Ömezli¹, Ferhat Ayrancı¹, Hale Yurtyapan¹, Nurcan Salman Duman²

¹Department of Oral and Maxillofacial Surgery, Ordu University, Ordu, Turkey

²Department of pathology, Ministry of Health, Ordu, Turkey

The dentigerous cyst is the second most common type of odontogenic cyst after radicular cyst and the most common developmental cyst of the jaws. Most frequently associated with impacted mandibular third molar teeth. The dentigerous cyst progresses slowly and may exist for several years without being noticed unless it becomes secondarily infected or makes cortical expansion. It is usually diagnosed on routine dental radiographs or taken for pathology. A late diagnosed dentigerous cyst may enlarge enough to make cortical expansion, pathologic fracture or displacement teeth. Usually this displacement occurs through maxillary sinus in maxilla and through condylar region, ramus or processus coronoideus in mandible. But it is not known whether these teeth achieve this location with the compression of the cyst or due to an ectopic germ formation. The standard treatment for a dentigerous cyst is enucleation and extraction of the cyst-associated impacted, unerupted or ectopic tooth.

In this case report, a case of a large dentigerous cyst with a ectopic third molar in the subcondylar region was presented.

Keywords: Dentigerous Cyst, Condyle, Mandible, Ectopic Tooth

PP-038

Intraoral Spindle Cell Lipoma: A case report

Nihat Laçın, Mustafa Yalçın, Serahim Serhat Atılğan

Department of Oral and Maxillofacial Surgery, Faculty of Dentistry, Dicle University, Diyarbakır, Turkey

OBJECTIVES

Lipoma, seldomly, occurs in the oral cavity. About 20% of lipomas occur in the head and neck region among which oral lipomas comprise only 1-4% of all lipomas. Intraoral lipomas are benign mesenchymal neoplasms that originate in mature adipose cells with differential diagnosis of other soft tissue lesions such as mucocoeles, dermoid cysts and traumatic fibroma. In the oral cavity, the buccal mucosa, tongue, and floor of the mouth are among the common locations, They present as a

slow growing, painless, asymptomatic yellowish submucosal mass and may cause mastication and speech difficulties. A 49-year-old female patient reported with swelling on the floor of the mouth for the last 6 months.

METHODS

Surgical excision was performed under local anaesthesia, and the mass was examined histopathologically. The mass was diagnosed as a spindle cell lipoma.

RESULTS

The patient was followed up and there was no recurrence.

CONCLUSIONS

Lipomas of the mouth are benign tumors and do not infiltrate other tissues. The usual lesions consist of a well circumscribed, lobulated mass of mature fat cells. Surgical excision is the only treatment recommended and the prognosis is good.

Keywords: lipoma, oral cavity, surgery

PP-039

Squamous Cell Carcinoma in the Maxilla with Aggressive Resorption

Mürüde Yazan, Fethi Atıl, İsmail Doruk Koçyiğit, Umut Tekin
department of oral and maxillofacial surgery, kirikkale university, kirikkale, turkey

Intraoral maxillary squamous cell carcinomas occur at relatively low rates compared with squamous cell carcinomas in other oral sites. Squamous cell carcinoma can affect the maxilla from both oral and sinus sites. Advanced cancer of the maxilla and sinonasal region has relapse potential; thus local recurrence must be followed as one of the sign of disease's relapse.

A 51-year-old man was referred to Kirikkale University, Department of Oral and Maxillofacial Surgery with a complaint of pain around the left posterior maxillary region. We identified bone resorption at this region after clinical and radiographical examination. Computed tomography revealed a destructive tumor with no cystic lesion. The patient was consulted to department of otorhinolaryngology. After the excisional biopsy operation, the patient referred to our clinic thus relapse of disease. The tumor was extracted with a second surgical operation radically.

Keywords: Squamous cell carcinoma, tumor, malign, maxilla

PP-040

Monostotic Fibrous Dysplasia of the Mandible

Emel Bulut¹, Esengül Bekar¹, Aydan Açıkgoz², Ömer Günhan³

¹Department of Oral and Maxillofacial Surgery, Samsun, Turkey

²Department of Oral and Maxillofacial Radiology, Samsun, Turkey

³Department of Pathology, Gülhane Military Medical Academy Ankara, Turkey

Fibrous dysplasia(FD) is one group of the fibroosseous lesions. FD affects jaws rarely and it has 3 subgroups: monostotic, polyostotic and craniofacial.

In this case report a 23 years old female patient referred to our clinic with a complaint of painless swelling in the right mandible. First, the cause of swelling was evaluated as a impacted third molar tooth. But the tooth was not extracted. In intraoral examination buccal swelling was seen in the right of the mandible. In the radiographic examination ground glass view extended from right molar region to ramus was seen. The patient has no extraoral aesthetic complaint and she didn't want an operation related with swelling. For the certain diagnosis, biopsy was performed. After the histopathological examination, it was diagnosed as FD. According to the bone survey analysis, there was no lesion on the other bones. So the case is considered as a monostotic form of the FD. Treatment options of the fibrous dysplasia are biopsy, recontouring of bone lesions and reconstruction of the bone defects using graft materials. The patient has been followed for 5 years and she has no aesthetic complaint. If an extraoral swelling enlarges and patient complains about it, recontouring of the lesion will be performed as a treatment.

As a conclusion, FD within fibro osseous lesions needs long termed follow up.

Keywords: fibroosseous lesion, fibrous dysplasia, mandible, oral pathology

PP-041

Diagnosis and Treatment of a Dentigerous Cyst Associated with Impacted Permanent Teeth Follicles in Mandible Anterior Region of a Child Patient

Eser Tutus¹, Bahadır Kan¹, Pinar Topcu¹, Sinem Yildirim², Ulku Sermet Elbay², Mehmet Fatih Coskunes¹

¹Kocaeli University Faculty of Dentistry Department of Oral and Maxillofacial Surgery

²Kocaeli University Faculty of Dentistry Department of Pediatric Dentistry

OBJECTIVES

The dentigerous cyst is defined as a cyst that originates by the separation of the follicle from around the crown of an unerupted tooth and it is the second most common odontogenic cysts in mandible after radicular cysts. Although dentigerous cyst generally associated with impacted third molar, it

5-8 November 2014 - Harbiye Military Museum & Cultural Center - İstanbul / Turkey

may occur around impacted canines and premolar. Dentigerous cysts are usually completely asymptomatic and are discovered only on a routine radiographic examination or when films are taken to determine the reason for the failure of a tooth to eruption.

MATERIAL-METHODS

A 10 years old girl patient referred to our clinic with complain of eruption failure of mandibular right permanent incisors while symmetric of the teeth were in the oral cavity. In radiological examination unilocular and radiolucent lesion in 5x3x3 cm size were observed around the crown of permanent left and right incisors and the apex of deciduous incisors in right mandible. An amorphous incisor was also located in the area.

The patient operated under general anesthesia and the lesion enucleated after the extraction of deciduous incisors and amorphous incisors. After the operation, the root treatment of the permanent erupted incisors associated with cyst cavity was performed and the teeth were splinted to the other due to the mobility.

RESULTS

The healing was uneventful. In her first year follow-up, it was observed that the mobility of the incisor teeth was normal and the cyst cavity was fully filled with bone. The patient is still under control.

CONCLUSION

Enucleation of dentigerous cyst without detriment the permanent tooth is a successful treatment modality in children. It is crucial that multidisciplinary treatment is necessary for the treatment of child patient with dentigerous cyst for the control of patient growing.

Keywords: Mandible, dentigerous cyst, incisors, permanent tooth, enucleation

PP-042

Long Term Follow up Dentigerous Cyst Treated with Marsupialization

Esma Coşkun¹, Cenk A. Akcan², Alper Aktaş¹

¹Department of Oral Surgery, Hacettepe University, Ankara, Turkey

²Department of Orthodontics, Hacettepe University, Ankara, Turkey

Dentigerous cysts are the most common of all developmental odontogenic cysts, making up about 20 % of epithelium-lined cysts of the jaws. Mostly applied treatment for a dentigerous cyst is careful enucleation of the cyst together with removal of the unerupted tooth. Marsupialization is advisable treatment to prevent the anatomic structures and to erupt a cyst-associated impacted tooth if enough space for eruption exists that will be more economic and have less surgical complication. In this poster, 17 years-old male patient applied to our clinic with complaint of pain in the right mandibular region is presented. For the treatment of dentigerous cyst marsupialization was chosen as a treatment method. This method, enabled prevention of the impacted tooth, which was later

erupted orthodontically. Marsupialization choice causes extended clinical visits besides this healing without osseous defect and tooth loss that is superior to a traditional enucleation method.

Keywords: Dentigerous cyst, marsupialization, eruption orthodontically

PP-043

Marsupialization of Odontogenic Cysts: Three Cases Report

Fatih Mehmet Coskunes, Pinar Celik Topcu, Ulkem Cilasun, Busra Cetinkaya

Department of Oral and Maxillofacial Surgery, Kocaeli University Faculty of Dentistry, Kocaeli, Turkey

OBJECTIVE

Odontogenic cysts constitute an important aspect of oral and maxillofacial pathology and are encountered relatively commonly in dental practice. Mostly odontogenic cysts are treated with enucleation and/or curettage. Odontogenic cysts, which develop asymptotically and demonstrate expansions, cause significant bone resorptions and invade to adjacent anatomical regions. Large odontogenic cysts may be treated with marsupialization in cases where enucleation or curettage might result in neurosensory dysfunction or predispose the patient to an increased chance of pathologic fracture. The purpose of this report is to present three cases with large odontogenic cysts treated by marsupialization.

METHODS

Three patients were referred to our clinic with a chief complaint of intraoral swelling and there were no pain or paraesthesia. Radiographic examinations showed well-defined, unilocular radiolucent lesions. Fine needle aspiration biopsies were performed for all three cases and the biopsy results revealed odontogenic cyst for all. In all cases, a bone window was created on the wall of the cyst, partial debridement were performed with an excision of the top portion of the cysts, and the edges of the cyst wall were sutured to the surrounding mucosa. A partial prosthesis with a drainage tube was used as a marsupialization plate for all cases.

RESULTS

All three cases were treated with marsupialization and three to six months later enucleation was performed. Patients are still under follow-up with no complications. These cases were asymptomatic and their growing volume caused massive bone destructions and mildly affected the neighbouring anatomic structures.

CONCLUSION

Although marsupialization is a conservative approach to treat large odontogenic cysts, there are some notable disadvantages of the technique such as; a) it is a two stage surgical procedure, b) pathological tissue is left behind and a more sinister pathological process, and c) in a large cystic cavity it takes a long period of time for the bone to regenerate. Early diagnosis and management of

the odontogenic cysts is very important as they may develop asymptotically and manifest invasions to adjacent anatomical regions.

Keywords: Odontogenic Cysts, Marsupialization

PP-044

A Case Report of Osteomyelitis with Long-Term Use of Corticosteroids

Fatih Mehmet Coskunes, Pinar Celik Topcu, Ulkem Cilasun, Bahadir Kan

Department of Oral and Maxillofacial Surgery, Kocaeli University Faculty of Dentistry, Kocaeli, Turkey

OBJECTIVE

Osteomyelitis is defined as an inflammatory condition of the bone that begins as an infection of the medullary cavity, rapidly spreads to the Haversian systems and eventually involves the periosteum of the infected areas. This case report describes a case of chronic osteomyelitis in the right parasymphiseal area of the mandible which is successfully treated with a combination of antibiotic therapy and surgical debridement in an 80-year-old female patient.

METHODS

An 80-year-old woman was referred to our clinic with pain and edema in the right side of her mandible. The patient's medical history revealed that she has rheumatoid arthritis and was on steroids. She was suffering from alveolar osteitis after extraction of right second premolar tooth, which was treated, with irrigation of the involved socket, a gentle mechanical debridement and antibiotics. One month later she applied to our clinic complaining a submental space abscess. After antibiotic regimen, drainage was performed. On the two months follow-up there was still pain. Cone beam computerized tomography (CBCT) scans of the region revealed a mixed pattern with partial loss of normal bone structure along with sclerosis and subperiosteal bone formation suggestive of chronic osteomyelitis.

RESULTS

The patient is successfully treated with a combination of antibiotic therapy and surgical debridement. She was prescribed antibiotics and attended regular follow-up visits. She was asymptomatic 4 months after surgery.

CONCLUSION

Osteomyelitis has been associated with multiple systemic diseases including diabetes, autoimmune states, malignancies etc. The medications linked to osteomyelitis are steroids, chemotherapeutic agents and bisphosphonates.

Keywords: Osteomyelitis, Corticosteroids

PP-045

Odontogenic Fibromyxoma of the Maxilla: A Case Report

Seda Yılmaz¹, Mehmet Ali Elçin², Gizem Çolakoğlu², Bora Özden³, Tuğçe Biçer Ayтуğar¹, Fatma Canan Alatlı⁴

¹Department of Oral and Maxillofacial Surgery, İstanbul Aydın University, İstanbul, Turkey

²Department of Oral and Maxillofacial Radiology, İstanbul Aydın University, İstanbul, Turkey

³Department of Oral and Maxillofacial Surgery, Ondokuz Mayıs University, Samsun, Turkey

⁴Department Of Tumour Pathology, Oncology Institute, İstanbul University, İstanbul, Turkey

Odontogenic fibromyxoma is a rare benign, slow-growing, locally aggressive and non-metastasizing neoplasms of the jaw bone. It is derived from dental embryonic mesenchymal elements. While fibromyxomas predominantly affects the posterior region of the mandible, it is seen rarely in the maxilla. Radiological examination with conventional radiography and dental volumetric tomography (DVT) contributes to the differential diagnosis from other benign tumors. Its management is surgical and comprises enucleation and curettage or en bloc resection.

The aim of this study is to present a case of odontogenic fibromyxoma occurring in the maxilla posterior region of a 52 years old male patient.

Keywords: Odontogenic fibromyxoma, maxilla, surgical treatment

PP-046

Marsupialization as a Definitive Treatment for the Keratocystic Odontogenic Tumor in a Pediatric Patient: Report of a Case with 3-year Follow-up

Berkay Tolga Süer¹, İsmail Doruk Koçyiğit²

¹Department of Oral and Maxillofacial Surgery, Gulhane Military Medical Academy, Haydarpasa Teaching Hospital, İstanbul, TURKEY

²Department of Oral and Maxillofacial Surgery, School of Dentistry, Kırıkkale University, Kırıkkale, TURKEY

World Health Organization (WHO) is reclassified the odontogenic keratocyst, was introduced by Philipsen in 1956, as a benign odontogenic tumor under the new term 'keratocystic odontogenic tumor' (KCOT). With the well-known tendency for the KCOT to recur, its treatment has been one of the most controversial pathological entities among the authors. A 7-year-old boy was referred in June 2011 to the Department of Oral and Maxillofacial Surgery of GATA Haydarpasa Teaching Hospital, İstanbul. The patient's dentist had noticed a radiolucent lesion on the orthopantomograph (OPG) interprets it as a big cyst and referred to us. The medical history of patient was noncontributory. An OPG revealed a well-delineated, unilocular radiolucency of the left body of the mandible containing the #34 and 35 teeth's crown in it. The root of the teeth #34 and 35 was not

developed at the initial examination. Due to patient's young age and mixed dentition situation, the decompression and marsupialization of the cyst was planned. During the first surgery, the mucoperiosteal flap was raised, the teeth # 73, 74 and 75 was extracted and small piece of the cyst was incised to do biopsy. The small acrylic drainage tube was sutured to the cyst cavity in order to kept open the cyst cavity to oral cavity. The histologic material was confirmed as KCOT by the pathology department. After a period of 10 months marsupialization, the KCOT completely resolved. During this long treatment, the patient had another cyst in his left maxilla. This cyst was enucleated and proved to be second KCOT. Because the patient had more than one KCOT, he was referred to the dermatology. The patient was confirmed to be unsyndromic. During the long course of treatment and follow-up, the fully eruption of the teeth # 34 and 35 was noted. The treatment option for pediatric KCOT based on decompression seems to offer effective and conservative option with low morbidity. We think that the marsupialization of the pediatric KCOT useful way to treat large cysts without need for aggressive surgery in the pediatric patients.

Keywords: Keratocystic Odontogenic Tumor; marsupialization; jaw cyst; decompression

PP-047

Non-syndromic Keratocystic Odontogenic Tumor: A Rare Case Report

Ahmet Hüseyin Acar, Nihat Demirtaş, Suzan Bayer

Department of Oral and Maxillofacial Surgery, Bezmialem University, Istanbul, Turkey

INTRODUCTION

A keratocystic odontogenic tumor (KOT) is a benign neoplasm of the jaws with odontogenic origin. KOTs were first described by Phillipsen, who classified them "odontogenic keratocysts". However, because of the aggressive clinical behavior and high recurrence rate of KOTs suggest a true neoplastic potential, the World Health Organization change the classification to benign tumors for them. The treatment of KOTs includes decompression, marginal resection, marsupialization. Several studies report that after marsupialization, the fibrous capsule becomes thicker and less friable so the surgical procedure of enucleation becomes easier and the recurrence rate reduces.

Case report: This report aims to present a conservative treatment of a male patient with large KOT involving his left mandibular ramus. The radiological examination demonstrated cortical thinning related with bone resorption resulting in displacement of the inferior alveolar nerve. The lesion treated with marsupialization and curettage.

CONCLUSION

Early detection and conservative treatment of KOTs is extremely important because they may affect maxillofacial complex. In addition, it is important since the malignant transformation can occur in these patients.

Keywords: keratocystic odontogenic tumor, diagnosis, marsupialization

5-8 November 2014 - Harbiye Military Museum & Cultural Center - İstanbul / Turkey

PP-048

Minimally Invasive Treatment of Cysts In Pediatric Patients

Nagehan Burcu Bayrak, Nurdan Kafalı Ünsal, Foad Saleh Najafi, Şeyma Mermutlu, Hasan Küçükolbaşı
Selcuk University Faculty of Dentistry Department of Oral and Maxillofacial Surgery

OBJECTIVE

The aim of this study is observe the most common type of cysts of the jaw and evaluate treatment respond in 8-15 years old children.

METHODS

8-15 years old 5 patients came with the complaint of swelling and pain between 2013- 2014. Panoramic radiographs were taken for diagnosis. There is loss of lamina dura along the associated tooth and a round well-circumscribed radiolucency at the tooth apex in radicular cyst. Radiographically, a dentigerous cyst is a well-defined, unilocular or occasionally multilocular radiolucency associated with the crown of an unerupted tooth. Both radicular and dentigerous cysts were treated with enucleation and curettage.

RESULTS

In one year period time any recurrence was occur. Panoramic radiographs were taken each 6 months in a year and normally permanent tooth eruption was observed.. In this study, the treatment of cysts in children with minimally invasive treatment approaches for aesthetic and functional disorders that may occur in the future can be avoided showed.

CONCLUSION

Radicular and dentigerous cysts are the most common type of odontogenic cysts of the jaws. Radicular cyst is associated with a carious lesion or is the result of a previous injury to the tooth and pulpal tissue. On the other hand dentigerous cyst is develops from proliferation of the enamel organ remnant and grows in size as a result of increased osmotic pressure within the cyst lumen, which causes expansion and bone resorption. Treatment consists of removal of the associated tooth and enucleation of the cysts. If the cyst is effect a large portion of the jaw decompression and irrigation minimize the lesion and the teeth to erupt.

Keywords: radicular cyst, primary dentition, minimal invasive treatment

PP-049**Is Laser Surgery Effective in the Treatment of Ligneous Periodontitis**

Burcu Baş¹, İlker Keskiner², Peruze Çelenk³, Ömer Günhan⁴

¹Department of Oral and Maxillofacial Surgery, Ondokuz Mayıs University, Samsun, Turkey

²Department of Periodontology, Ondokuz Mayıs University, Samsun, Turkey

³Department of Oral and Maxillofacial Radiology, Ondokuz Mayıs University, Samsun, Turkey

⁴Department of Oral Pathology, Gulhane Military Hospital, Ankara, Turkey

OBJECTIVE

Ligneous mucosal disease is a rare inherited chronic disease that frequently affects conjunctival and gingival mucosa. Typical clinical appearance of the disease is firm, sessile, pseudomembranous mucosal masses which occur due to plasminogen deficiency and resultant fibrin deposition. In this report we present clinicopathologic findings and treatment approaches of a patient with ligneous periodontitis and conjunctivitis.

CASE

A 29 years old male patient referred to our clinic with a complaint of hyperplastic white lesions involving both jaws. The patient mentioned that the lesions have been present since he was 12 years old. The patient has lost his teeth in 12 years and only 36th tooth was present in the dental arch.

RESULT

Incisional biopsy was performed which resulted as ligneous periodontitis. The patient was referred to the medical faculty for evaluating of the eye involvement. Ligneous conjunctivitis was also detected. Hematologic assessment revealed no abnormalities except plasminogen levels. Functional plasminogen assays were done and found to be deficient. As the standard surgery was not found efficient in the literature we decided to perform laser surgery for eliminating lesions. However the lesions were occurred again as at the first week.

CONCLUSION

Like standard surgery, laser surgery was also found ineffective in the treatment of the ligneous lesions. Four months post operative follow up reveals no sign of regression.

Keywords: Ligneous periodontitis, Laser surgery

PP-050

Ameloblastoma in the Right Maxillary Posterior Region: A Case Report

Nuray Er, Onur Koç, Çiğdem Karaca

Hacettepe University Oral and Maxillofacial Surgery Ankara/TURKEY

Ameloblastoma is a locally aggressive, epithelial odontogenic benign neoplasm that has close histologic resemblance to the enamel organ seen in developing teeth. It is usually present within the bone, however, it can also be found in the soft tissues (peripheral ameloblastoma). It is classified into solid and cystic or multicystic variants. In the solid variant, there are a variety of histopathologic patterns seen such as follicular, plexiform, desmoplastic, basal cell, acanthomatous, and granular cell. Ameloblastoma comprises of 1% of all oral tumors and about 11–18% of odontogenic tumors.

Clinically, it often presents as a painless, slow growing mass, and if untreated it can become large, loosen or displace teeth, and expand the cortices. Due to its destructive nature, some authors advocate designation of ameloblastoma as a low-grade malignancy, although this lesion is considered benign according to the World Health Organization classification of odontogenic neoplasms.

For solid or multicystic ameloblastomas, recurrence rates of 50 to 90% have been reported after curettage. Marginal resection is the most widely used treatment, but recurrence rates of up to 15% have been reported after marginal or block resection. In the case of unicystic ameloblastoma, 30% of these lesions recur after enucleation.

In this case presentation, it will be reported that a 39 year- old female patient had a unilocular, radioluscent but not significant sclerotic bordered, with a 6cm*5cm in a diameter in the right maxillary posterior region. The lesion was enucleated with peripheral osteotomy. The biopsy was reported as an ameloblastoma. After 2 years follow up there is no recurrence at the operation site. Regular follow-up visits has been planned for at least 5 years.

Keywords: ameloblastoma, 2 year follow up, odontogenic tumor, maxilla

PP-051

A Complex Odontoma in the Posterior Mandible with Paresthesia of Inferior Alveolar Nerve: A Case Report

Gül Merve Yalçın, Aysheh Hamoeipour, Fatih Cabbar

Department of Oral and Maxillofacial Surgery, Yeditepe University Faculty of Dentistry, Istanbul, Turkey

Odontomas are odontogenic benign tumors composed of dental tissues. They are actually hamartomas or developmental anomalies composed of enamel, dentin, cementum and pulp tissue.

These lesions are classified into two types: complex and compound odontoma. Although most of these lesions are asymptomatic and are often detected on routine radiographs, sometimes they can cause over-retention, impaction and delayed eruption of both primary and permanent teeth. In this poster presentation, we will present a case of 32-year-old female with complex odontoma superior to inferior alveolar canal in the left posterior mandible with inferior alveolar nerve paresthesia and the resolution of paresthesia after surgical removal of the lesion.

Keywords: Complex Odontoma, Paresthesia, IAN, Odontogenic Tumors

PP-052

Peripheral Giant Cell Granuloma: A Case Report

Mustafa Yalçın, Nihat Laçın, Serahim Serhat Atılğan, Haluk Yener Ünsal
Department of Oral and Maxillofacial Surgery, Faculty of Dentistry, Dicle University, Diyarbakır, Turkey

OBJECTIVE

Peripheral giant cell granuloma(PGCG) is a rare exophytic lesion of the oral cavity which originates from the periosteum or periodontal membrane following local irritation or chronic trauma. The peripheral giant cell granuloma is more common in the mandibular arch than in the maxillary arch. The radiographs exhibit evidence of superficial destruction of the alveolar margin or crest of the interdental bone. This report presents the surgical treatment of a PGCG in a 32-year-old male patient.

PATIENT AND METHODS

Intraoral examination revealed a swelling that was pale pink, firm and pedicellate. The lesion was large and interfered with occlusion. Surgical excision was performed under local anaesthesia, and the mass was examined histopathologically. The mass was diagnosed as a peripheral giant cell granuloma.

RESULTS

The mass was surgically excised, teeth were extracted and curettage was done. The patient was followed up and there was no recurrence.

CONCLUSION

Peripheral giant cell granuloma is a benign hyperplastic reactive lesion of the oral cavity. The lesion should be completely removed to prevent recurrence. The best treatment of choice is surgical excision.

Keywords: peripheral granuloma, mandible, surgical

PP-053**An Unexpected Gingival Growth**

Şeyma Mermutlu, Hasan Küçükkolbaşı

Department of oral and maxillofacial surgery, Selçuk university, Konya, Turkey

OBJECTIVE

In this case report we observe a 14 years old female patient who has the rare type of oral malignancy fibrosarcoma.

METHODS

A 14-year-old female patient came with the complaint of slow-growing swelling over the left side of the mandible. She gave a history of pain in the posterior mandibular region since 1 months. The patient didn't give any history of systemic illness or trauma to the head and neck region. There was no significant contributing family history. The swelling was irregular in shape. Skin over the swelling was normal in colour. The left submandibular lymph nodes were normal. After the excisional biopsy and specimen was evaluated histopathologically, one month later lesion relapsed.

RESULTS

Patient referred to ENT clinic for further surgical treatment. Any recurrence observed after the excision of lesion and neck dissection In one year period.

CONCLUSION

Fibrosarcoma has been defined as a malignant tumor of the fibroblasts that shows no other evidence of cellular differentiation and is capable of recurrence and metastasis. Fibrosarcomas are rare but may occur anywhere in the body, most commonly in the retroperitoneum, thigh, knee and distal extremities. Fibrosarcoma is uncommon in the head and neck region and constitutes about 1% of all the malignancies affecting the human race. Of all the fibrosarcomas occurring in humans, only 0.05% occurs in the head and neck region. Of this, almost 23% is seen in the oral cavity. Fibrosarcomas generally have a poor prognosis and the overall survival rate is 20-35% over a period of 5 years.

Keywords: gingiva, biopsy, hyperpylasia, fibrosarcoma

PP-054

Unusual Oral Pathology Mimicking Giant Cell Granuloma of a Pediatric Patient: A Case Report

Yasemin Kartal Kocyigit¹, Betül Memiş Özgül², Ozkan Özgül³, Doruk Kocyigit⁴, Umut Tekin⁴

¹Department of Orthodontics, Baskent University, Ankara, Turkey

²Department of Pediatric Dentistry, Baskent University, Ankara, Turkey

³Department of Oral Maxillofacial Surgery, Ufuk University, Ankara, Turkey

⁴Department of Oral Maxillofacial Surgery, Kırıkkale University, Kırıkkale, Turkey

Infantile myofibromatosis is an uncommon benign fibrous tumour the jaw. This pathology first described by Stout in 1954. Oral soft tissue, skeleton and internal organs are affected organs. Infantile myofibromatosis can occur as solitary or can be multi-centric form. The prognosis is excellent in the solitary type, which is limited in the skin, muscle, and subcutaneous lesions. But the multicentric form of infantile myofibromatosis can be more dangerous, which has visceral involvement, can be life-threatening. The solitary type is usually benign and the recurrence rate is low at 10%. Here, we report a rare case of a solitary myofibroma arising from right maxillary bone including teeth number 11-16 in a 9-year-old girl. Surgical removal of the lesion was completed with uneventful two years follow period. Differential diagnosis of the pathology and the treatment modalities were also discussed in the report.

Keywords: infantil; soft; swelling; fibrous.

PP-055

Peripheral Odontogenic Fibroma, Clinically Misdiagnosed Mimicing Gingival Hyperplasia

Çiğdem Karaca¹, Alper Aktaş¹, Kadriye Ayça Dere¹, Kemal Kösemehmetoğlu²

¹Department of Oral and Maxillofacial Surgery, Hacettepe University, Ankara, Turkey

²Department of Pathology, Hacettepe University, Ankara, Turkey

Peripheral odontogenic fibroma is a variant of santral odontogenic fibroma appears in the oral soft tissues. It is an uncommon dental lesion regarded by the World Health Organization as a benign odontogenic neoplasm derived from fibroblasts. Peripheral odontogenic fibroma appears as a firm, slow growing and usually sessile gingival mass covered by normal appearing mucosa. Rarely multifocal or diffuse lesions have been described. The lesion is most often encountered on the facial gingiva of mandible. It has been recorded in patients over a wide age range with most identified from the second to the seventh decade of life.

In this poster, 26 years old, asymptomatic female patient with multifocal and diffuse peripheral odontogenic fibroma is presented. On her routine clinical examination, it was noticed that the left and right mandibular third molars were partially impacted, infraocclusion and there was diffuse gingival growing around the lingual surface of the teeth which seems to mimic gingival hyperplasia.

Also she had an totally impacted third molar in the left maxilla and similar gingival enlargement on the maxillary tuberosity was also observed. The growing gingiva was firm and healthy like the adjacent gingiva. Incisional biopsies from the all growing gingival areas from three parts of the jaws was done. Histopathologic examination reported specimens as peripheral odontogenic fibroma.

This poster presentation pointed out the importance of histopathologic examination even there is no suspicious about the clinical presentation of the lesion.

Keywords: odontogenic tumor,gingival hyperplasia,odontogenic fibroma

PP-056

Treatment of Keratocystic Odontogenic Tumor in Geriatric

Esma Coşkun, Aylin Ekmekcioğlu, Duygu Uçar, Emre Tosun
Department of Oral and Maksillofasial Surgery,Hacettepe University,Ankara,Turkey

The keratocystic odontogenic tumors are locally aggressive benign tumor which occurs in the bones of both jaws with a high recurrence rate. KCOT obtained its name in 2005 when the World Health Organization decided to choose KCOT over the traditionally used term of odontogenic keratocystic tumor. Odontogenic keratocyst may be found in patients who range in age from infancy old age but about 60% of all cases are diagnosed in people between 10 and 40 years of age. There is a slight male predilection. The mandible is involved in 60% to 80% of cases, with a marked tendency to involve the posterior body and ascending ramus. KCOT; decompression, marsupialization, peripheral osteotomy with application of Carnoy's solution or liquid nitrogen cryotherapy with most options supplementing the enucleation technique.

In this report the treatment of a large keratocystic odontogenic tumors in a 74 year old woman was presented

Keywords: Treatment, Oral pathology, Geriatric, Keratocystic Odontogenic Tumor

PP-057

Giant Cell Granulomas in Edentulous Regions of Jaws: Report of Two Cases

Cennet Neslihan Eroğlu, Levent Cığgırm
Department of Oral and Maxillofacial Surgery, Faculty of Dentistry, Yuzuncuyl University, Van, Turkey

OBJECTIVE

This report presents clinical properties and treatment of giant cell granulomas related with edentulous regions of maxilla and mandible.

5-8 November 2014 - Harbiye Military Museum & Cultural Center - İstanbul / Turkey

METHODS

Case 1: A 65-year-old man was referred to our clinic with complaining about swelling and pain in his right mandibular lingual canine premolar region. Intraoral examination revealed a swelling that was red, firm, and sessile, with a smooth surface texture. There was no sign of bone resorption in radiographic evaluation.

Case 2: A 34-year-old woman complaining about painless swelling on her left maxilla. She had history of pregnancy and her maxilla was totally edentulous. Intraoral examination revealed a painless, solid mass and there was no sign of bone lesion in radiographic evaluation. However intraoperatively bone invasion was seen. An excisional biopsy was performed under local anaesthesia for both cases and the tissues were examined histopathologically.

RESULTS

The first case's histopathological diagnosis was Peripheral Giant Cell Granuloma and the second case's diagnosis was Central Giant Cell Granuloma. Patients had no complaint and they were satisfied three months after the operation.

CONCLUSION

The total enucleation of giant cell granulomas was a enough treatment option for such as these cases. The irritation of removable prosthesis and hormonal changes in pregnancy may be consider as reasons for giant cell granuloma pathway.

Keywords: peripheral giant cell granuloma, central giant cell granuloma, maxilla, mandible

PP-058

Closure of Oroantral Communication Using an Autologous Bone Graft: Case Report

Cennet Neslihan Eroğlu, Levent Cığırım

Department of Oral and Maxillofacial Surgery, Faculty of Dentistry, Yuzuncuyil University, Van, Turkey

OBJECTIVE

This report presents closure of oroantral communication with surgical approach using autologous block bone graft.

METHODS

A 35-year-old man was referred to our clinic with complaining about liquids entering from his mouth to nose. Radiographic evaluation revealed oroantral communication in edentulous left maxilla. The left maxillary sinus floor wall was perforated and contact crestal soft tissue. It was closed with autologous block bone graft that was harvested from mentum. Closure of the bone defect in the related region was evaluated with panoramic radiograph and computed tomograph three months after the operation.

5-8 November 2014 - Harbiye Military Museum & Cultural Center - İstanbul / Turkey

RESULTS

Clinically edentulous soft tissue was asymptomatic and there was no sign of communication and radiographic evaluation revealed closure of bony defect was completed three months after the operation. Patient had no complaint and he was satisfied.

CONCLUSIONS

Closure of oroantral communication using autologous bone graft is one of the appropriate treatment options in such cases

Keywords: oroantral communication, maxilla, bone graft

PP-059

The Effects of Periradicular Inflammation and Infection on Primary Teeth and Permanent Successors: A Case Report

Eda Arat Maden¹, Tamer Zerener², Ceyhan Altun¹

¹Pediatric Dentistry, Gulhane Medical Academy, Ankara, Turkey

²Oral and Maxillofacial Surgery, Gulhane Medical Academy, Ankara, Turkey

AIM

Pulpal inflammation/infection of a primary tooth and the spread of this condition over the periradicular tissues can lead to alterations in the dental germ of the permanent successor and to the surrounding structures if no therapy is done, i.e. endodontics or extraction. This work will present cases of permanent teeth that showed alteration in eruption and / or in development, as a consequence of inflammation / infection of the preceding primary teeth.

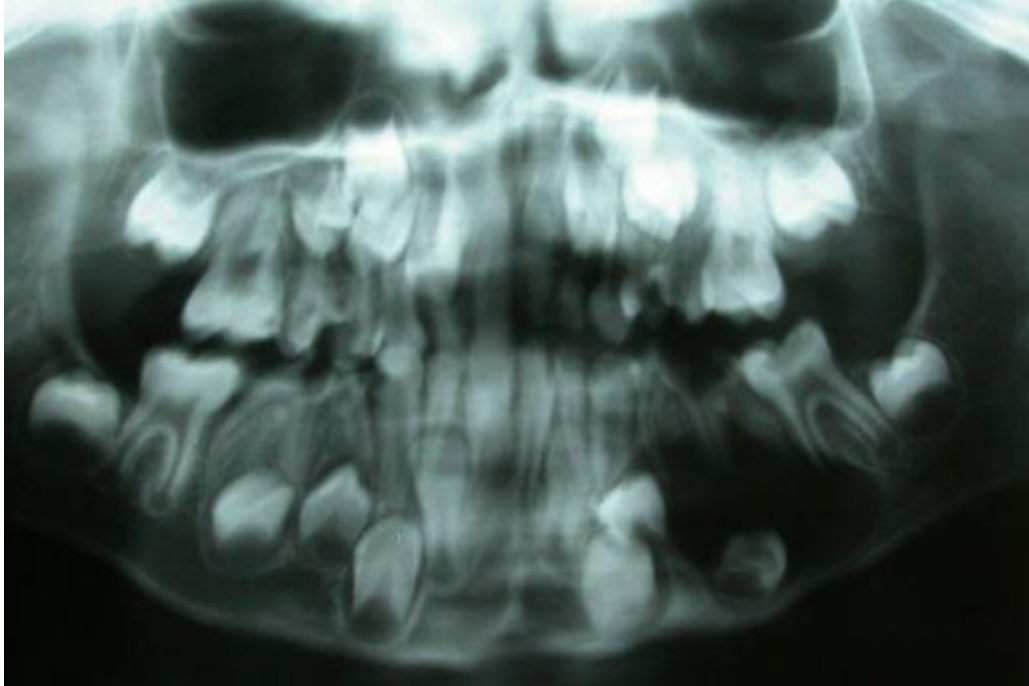
Case Report: A 6-year-old boy reported to the Department of Paediatric Dentistry at our institute with the chief complaint of a painless swelling in the left lower jaw. A clinical intraoral examination revealed extensive decay in the mandibular left deciduous first and second molars and diffuse swelling in the mandibular left deciduous molar area. Based on clinical and radiological findings, a provisional diagnosis of dentoalveolar abscess was made (Figure 1). The patient referred to Oral and Maxillofacial Surgery Department. The mandibular left deciduous first and second molars and the impacted mandibular left permanent first and second premolars were extracted. The patient is on clinical and radiological follow up.

CONCLUSION

Permanent teeth can show alteration in eruption and / or in development, as a consequence of inflammation / infection of the preceding primary teeth, such as: hypoplasia, morphological alteration on the dental crown or total arrest of. radicular formation. The earlier these lesions are diagnosed, the less were the destructive effects and the consequences on the primary tooth/permanent germ unit.

Keywords: dentoalveolar abscess, eruption, permanent successors

Panoromic radiograph revealed dentoalveolar abscess.



PP-060

Extensive Located Odontogenic Keratocyst Of Maxilla: Case Report

Ali Rıza Kolbaş, Tuğçe Göktürk, Anıl Öztürk, Selen Adiloğlu, Murat Akkocaoğlu
Department of Oral Surgery, Hacettepe University, Ankara, Turkey

The Keratocystic Odontogenic Tumor is a benign developmental tumor with many distinguishing clinical and histologic features. These characteristics are reviewed in the setting of a typical presentation. The newly acknowledged neoplastic potential and its implications for treatment strategies are also discussed.

Keratocystic Odontogenic Tumor may be found in patients who range in age from infancy to old age but about 60% of cases are diagnosed in people between 10 and 40 years of age. There is a slight male predilection. The mandible is involved in 60% to 80% of cases, with a marked tendency to involve the posterior body and ascending ramus.

In this case we report a 36 year old male patient with keratocystic odontogenic tumor caused slightly bone expansion at right posterior maxilla with no pain, swelling or drainage. Lesion had been discovered during the course of a radiographical examination. A well-defined large multilocular radiolucent area from lateral side of aperture piriformis to posterior margin of maxilla and lower side of orbita that includes maxillary sinus was observed. Enucleation of the lesion was performed under

general anesthesia. After histopathologic evaluation our final diagnosis was keratocystic odontogenic tumor.

Keywords: Keratocystic Odontogenic Tumor, Impacted Teeth, Maxillary Sinus

PP-061

Central Giant Cell Granuloma of Mandible in Early Childhood: A Conservative Surgical Management

Fatih Mehmet Coskunes, Busra Cetinkaya, Pinar Celik

Department of Oral and Maxillofacial Surgery, Kocaeli University Faculty of Dentistry, Kocaeli, Turkey

INTRODUCTION

The central giant cell granuloma (CGCG) is a relatively uncommon pathological condition accounting for less than 7% of all benign intraosseous lesions of the jaws. It may occur at any age but is predominantly found in children and young adults. The etiology of CGCG is unknown and clinical behavior is variable. The color of the overlying mucosa can be purple or lesion may be coated with normal mucosa. Non-aggressive form has a slow rate of growth. The aggressive form has rapid growth and thus is much more likely to resorb roots and perforate the cortical plate.

CASE PRESENTATION: A 10 years old boy was referred to our clinic for swelling in the right side of mandible anterior region and lesion was covered by normal mucosa. Permanent canine, first premolar and incisors were migrated because of the expansion of lesion. Radiologic appearance was lucent with irregular sclerotic border. In the first operation incisional biopsy was done under local anesthesia. Then, under general anesthesia, lesion removed by local invasive curettage and the histopathological diagnosis was confirmed. Anterior teeth are splinted to each other's.

RESULTS

One year after surgery, spontaneous repositioning of migrated teeth was seen on radiograph without orthodontic treatment. The patient is under routine control now.

CONCLUSIONS

Central Giant Cell Granuloma is a benign lesion of the jaws. It may affect both maxilla and mandible. The clinical appearance of CGCG is variable; like red-purple nodule or normal mucosal colored as in this case. Migration of the teeth may occur. The treatment of CGCG involves resection, total excision and curettage. Curettage would be preferred to resection in young patients.

Keywords: Central Giant Cell Granuloma, Childhood, Conservative

PP-062

Enormous Odontoma In Mandibular Third Molar Area with Impacted Second Molar Tooth Near the Mandibular Border

Hatice Duran, Mehmet Kemal Tümer, Nihat Akbulut

Department of Oral and Maxillofacial Surgery, Gaziosmanpaşa University, Tokat, Turkey

INTRODUCTION

Odontomas are a heterogeneous group of jaw bone lesions, classified as odontogenic tumors which usually include well-diversified dental tissues.

CASE

A 15-year-old female patient was referred to our surgical clinic with a pain in the right side of mandible. We determined the lesion in third molar region of the mandible with an impacted second molar tooth in the marginal mandible by radiological examination. She had no systemic illness for planning any surgical approach. An intraoral excision of the lesion was performed under general anesthesia and mandibular continuity and function was also preserved. Histopathological examination revealed as odontoma. The huge bony defect was been left to heal completely without a bone graft or further intervention. The nerve damage was not observed and we had an uneventfully healing process.

CONCLUSION

This case report emphasizes the importance of the early diagnosis of these lesions and a conservative surgical approach as well as the extraordinary healing potential in young patients. Practitioners also should be awareness about taking panoramic radiography in the first session of the meeting with the patient to detect these lesions.

Keywords: Odontoma, impacted molar tooth, jaw bone lesions

PP-063

Subconjunctival Emphysema Following Bleach Injury from Root Canal Treatment

Tun Wildan, Avan Mohammed, Vinay Shah, Bhavin Visavadia

Regional Maxillofacial Centre, North West London Hospitals Trust, Watford Road, London HA1 3UJ

INTRODUCTION

We would like to report a case of subconjunctival emphysema following sodium hypochlorite injury from a root canal treatment which had not been previously described in the literature. We will also discuss the management strategies involved with hypochlorite injuries of the facial soft tissues.

Clinical presentation: A 52 year old lady presented to the emergency department with burning pain,

5-8 November 2014 - Harbiye Military Museum & Cultural Center - İstanbul / Turkey

redness and swelling of her left face extending from the buccal sulcus to the lower eyelid. She had a root canal treatment to her upper left second premolar a few hours earlier by her dentist when the canal was irrigated with a 1% solution of sodium hypochlorite.

Medical history revealed that the patient was hypertensive and suffers from hay fever. She had no known allergy to any medications. The patient was afebrile with normal vital signs. Blood results were unremarkable.

No visual disturbances were evident although she had a subconjunctival emphysema associated with the periorbital emphysema in the left lower eyelid with clear, round air bubbles in the inferior bulbar conjunctiva. No sensorymotor dysfunction was noted. Ophthalmology review did not show any other ocular abnormality and attempts were made to clear the air from the subconjunctival space albeit unsuccessfully.

MANAGEMENT

She was admitted for intravenous antibiotics and dexamethasone as well as analgesics and chloramphenicol eye ointment. She was discharged after 3 days following a full recovery.

DISCUSSION

Sodium hypochlorite can cause a chemical burn and consequent tissue necrosis due to the severe inflammation and tissue necrosis. Extrusion of sodium hypochlorite beyond the tooth apex during root canal treatment can have a detrimental effect on the surrounding tissue.

This patient developed an acute inflammatory reaction with subsequent swelling of her face and the presence of subconjunctival emphysema. The subconjunctival emphysema is probably due to communication between the subcutaneous and subconjunctival planes from the effect of the chemical burn from sodium hypochlorite. This could be exacerbated by using compressed air to clear contaminants intra-orally.

Most cases of subconjunctival emphysema are treated conservatively and follow an uneventful course. Steroids can reduce the effect of inflammation whilst antibiotics prevent secondary eye infection. The vision can be obstructed by the presence of bubbles in the conjunctiva but this usually subsides with time. Rarely, this can progress to a serious vision-threatening complications from orbital compression.

Keywords: sodium hypochlorite injury, subconjunctival emphysema, root canal treatment

PP-064

Evaluation of Demographic Features and Oral Hygiene Habits in the Patients Referred to Oral and Maxillofacial Surgery Clinic

Nihat Demirtas¹, Suzan Bayer¹, Nazmiye Donmez²

¹Bezmialem Vakif University, Department of Oral and Maxillofacial Surgery

²Bezmialem Vakif University, Department of Conservative Dentistry

OBJECTIVE

This study aims to analyze the demographic features and oral hygiene habits in the patients referred to Oral and Maxillofacial Surgery Clinic.

METHODS

A total of 247 patients who had reported multiple oral health problems entered this study. Subjects were randomized from the patients applied to our faculty between September and December 2013. The questionnaire included information about patients' education level, oral hygiene habits, frequency of alcohol and cigarette consumption and frequency of dental visit.

RESULTS

The participants were 58.3% female (n=144) and 41.7% (n=103) male whom aged 17-73 years. Of these, 70% (n=173) reported brushing their teeth at least twice daily. Frequency of toothbrushing and regular dental visits were related to high level of education. However, of the patients 74.9% (n=185) delaying a dental visit until they had toothache.

CONCLUSIONS

In this study, a considerable part of the patients who referred to Oral and Maxillofacial Surgery Clinic was reported regular toothbrushing. Nevertheless, our results showed that majority of patients with multiple oral health problems did not prefer to have regular dental check-ups. This condition should be taken into account when evaluating the patients before and after oral surgery.

Keywords: oral hygiene, dental visiting, oral surgery,

PP-065

A Case of Transmigrated Mandibular Canine with Compound Odontoma

Nergiz Yılmaz, Ahmet Mihmanlı, Ahmet Huseyin Acar, Suzan Bayer, Nihat Demirtas
Department of Oral and Maxillofacial Surgery, Faculty of Dentistry, Bezmialem Vakif University,
Istanbul, Turkey

INTRODUCTION

The term "transmigration" is used to describe unerupted teeth which crosses the jaw midline. the

5-8 November 2014 - Harbiye Military Museum & Cultural Center - İstanbul / Turkey

etiology is still unclear. Although, it is a very rare entity, mandibular canines are one of the most frequent transmigrated teeth. They can cause resorption and malposition of teeth and infections. In addition transmigrated teeth should be related with several jaw pathologies such as odontogenic cysts and tumors.

CLINICAL REPORT

In this paper, we present a case of transmigrated mandibular canine with compound odontoma in a child. The lesion was detected during routine panoramic examination and 3-D views showed excessive bone resorption at the mandibular symphysis. The lesion was excised and impacted tooth was extracted under general anesthesia. Moreover, a large dentigerous cyst was occurred around the transmigrated tooth. Postoperative period of the patient was uneventful.

CONCLUSIONS

We conclude that, transmigrated teeth should occur in a child and may be related with compound odontoma and dentigerous cysts. Hence, early detection and conservative treatment is extremely important in these patients.

Keywords: transmigration, impacted teeth, compound odontoma, conservative treatment

PP-066

Damage to the Inferior Alveolar Nerve After Pulp Extirpation: Case Report with 2-Years Follow-Up

Suzan Bayer, Nihat Demirtaş, Ahmet Hüseyin Acar

Department of Oral and Maxillofacial Surgery, Bezmialem University, İstanbul, Turkey

INTRODUCTION

Endodontic related injury of inferior alveolar nerve (IAN) is a rare condition. However, paresthesia is a potential complication of endodontic treatment despite the development of root treatment techniques. In this paper, a case of paresthesia related to over-extension of endodontic files during the endodontic treatment was reported.

CASE

A 33 year-old female patient applied to our faculty with a chief complaint of toothache. After clinical and radiological examination, it was determined that her left lower second molar tooth requiring endodontic treatment. After pulp extirpation, paresthesia in the left posterior mandible and numbness on the left side of the lower lip was occurred. At this stage, root canal treatment was stopped and medical treatment was given for a long time. Nevertheless, she still has numbness and prickling on her lip instantly during 2 years follow-up period.

CONCLUSION

Paresthesia is one of the most serious complication in dentistry and it is so difficult to treat. In conclusion, clinicians pay special attention to endodontic treatment of teeth, especially which may be associated with mandibular canal.

Keywords: paraesthesia, root canal treatment, inferior alveolar nerve

PP-067

Implant Supported Restoration of Patient with Reconstructed Post-auricular Skin Graft

Ömer Orkun Cevizcioğlu, Metin Şençimen, Hasan Ayberk Altuğ, Tamer Zerener, Sencer Seğer, Gamze Arıcı

Gulhane Military Medical Academy, Department of Oral and Maxillofacial Surgery, Ankara, Türkiye

INTRODUCTION

Dental implants can successfully be used to rehabilitate maxillofacial defects due to trauma cause hard and soft tissue loss. Here we represent the restoration of an edentulous region without enough attached gingiva due to a traffic accident.

CASE

A 22-year-old male patient referred to our clinic with the complaint of the partial edentulism at the anterior mandible. He lost his mandibular incisors a few years ago because of the traffic accident. We decided to restore anterior partial edentulism with dental implants but he has not enough attached gingiva at the anterior mandible. Therefore, it was aimed to useage of half thickness mucosal flap from post-auricular skin. A thinned skin graft without fat tissue was harvested from the left post-auricular site. Than the graft was replaced to the recipient edentulous site and sutured. The grafted region was covered with the surgical stent and soft lining material. After three months period the anterior mandible was ready for implant surgery. We placed three implants to restore edentulous region. The patient was recalled after three months of the implant placement and implant supported restoration was finished.

CONCLUSION

Attached gingiva is a crucial aspect of healthy peri-implant tissue. Post auricular skin allows harvesting grafts at sufficient size to increase width of attached gingiva. Post auricular skin graft may become a feasible and effective solution to rebuild keratinized soft tissue before dental implant restoration.

Keywords: Attached gingiva, skin graft, implant site development

PP-068

A Surgical Treatment of Oroantral Fistula with Autogenous Bone Graft - Case Report

Murat Akkocaoğlu, Taha Özer

Department of Oral Surgery, Hacettepe University, Ankara, Turkey

An oroantral fistula (OAF) may develop as a complication of dental extractions, as a result of infection, or as sequelae of radiation therapy, trauma, implant surgery, orthognathic surgery and

removal of maxillary cysts or tumours. The commonest aetiology of OAF is as a complication following extraction of maxillary posterior teeth.

If this maxillary sinus and oral cavity communication is present beyond 3 weeks or is larger than 5 mm, it will unlikely heal spontaneously. As a result, most of these patients will develop chronic maxillary sinusitis. The patient may complain of fluids entering the nasal cavity while eating or drinking, nasal congestion or sanguineous discharge. The patient may also report poorly localized discomfort around the extraction site that radiates to the orbital area and is often perceived as an adjacent toothache. After clinical examination, Computed Tomography is the mainstay aiding in the diagnosis of OAFs.

Treatment modalities to repair OAFs following any cause include local and distant soft tissue flaps, autogenous bone grafts, allogeneous materials, xenografts, synthetic metals and other techniques. Regardless of the technique, two principles must be observed. First, the sinus must be rendered free of infection with adequate drainage and the use of appropriate sinus antibiotics in addition to topical or systemic decongestants. Second, tension free closure of a broad base, well vascularized soft tissue flap.

In this paper, we described a patient who had an OAF about 3 years and her surgical treatment with autogenous bone graft.

Keywords: autogenous bone graft, oroantral fistula, surgical treatment

PP-069

Unicystic Ameloblastoma of the Mandible with Two Cases

Özge DOĞANAY¹, Belir Atalay¹, Yusuf Emes¹, Buket Aybar¹, Ülkem Cural¹, Şebnem Bilici¹, Merva Soluk², Serhat Yalçın¹

¹Department of Oral Surgery, İstanbul University Dentistry Faculty, İstanbul, Turkey

²Department of Tumor Pathology, İstanbul University Institute of Oncology, İstanbul, Turkey

Ameloblastoma, a benign odontogenic neoplasm that may exhibit aggressive biological behavior, is classified into solid/multicystic, extraosseous/peripheral, desmoplastic and unicystic types based on the clinical appearance. Unicystic ameloblastoma is the 2nd frequent type seen in intraosseous ameloblastoma. It manifests as unilocular radiolucency in the mandible on X-ray scans. We would like to report of 2 cases of cystic ameloblastoma in the mandible, in 18-year-old girls. They were enucleated and histopathologically confirmed as a unicystic ameloblastoma. All in all, more cases of unicystic ameloblastoma need to be reported to give a better aspect and cases are well documented clinically, radiographically and histologically. Besides, cases with long follow-up periods are in need.

Keywords: Unicystic ameloblastoma, Intra-osseous, Enucleation, Female

PP-070

Decompression and Marsupialization as a Treatment Option for the Odontogenic Keratocyst: A Case Report

Ulviyya Mammadova, Nima Moharamnejad

Department of Oral and Maxillofacial Surgery Gazi University, Faculty of Dentistry Ankara Turkey

The keratocystic odontogenic tumor (KCOT) is a relatively common oral and maxillofacial lesion with specific characteristics such as rapid growth, extension into the ambient tissues and high rates of recurrence. Due to the very thin and friable lining characteristic of the tumor, enucleation can be difficult undertaken and for this reason it is associated with the highest recurrence rates.

Many of the surgeons prefer a more aggressive treatment, like enucleation. This report describes the conservative treatment of an 69-year-old male affected by keratocystic odontogenic tumor (KCOT) and have had excellent result. We would like to suggest that decompression and marsupialization can be treatment option for large OKC's.

Keywords: Keratocystic Odontogenic Tumour, OKC, marsupialization

PP-071

Lipoma of the Buccal Fat Pad: A Case Report

Ayfer Kaynar¹, Canan Alatli²

¹Department of Oral Surgery, School of Dentistry, Istanbul University

²Department of Tumor Pathology, Institution of Oncology, Istanbul University

OBJECTIVE

Buccal Fat Pad (BFP) differs anatomically and physiologically from the subcutaneous fat. Pathological changes of this structure is quite uncommon. Between 1842- 2009 only 29 cases of BFP lipoma has been reported. The aim of the presentation is to introduce surgical treatment of this rare case via transoral approach.

CASE

A 35 year old woman with no relevant medical history presented with a painless mass of the right cheek that was first noticed 3 years previously. She denied having history of trauma and complaints other than esthetic deformity. On physical examination there was a soft palpable and mobile mass on the left cheek. Overlying mucosa and skin looked normal. There was also no sign of facial paralysis, trismus and lymphadenopathy. MRI revealed a well defined adipose tissue, consistent with lipoma. The growth pattern of the tumor was mimicking anatomical structure of the BFP which was divided into three individually encapsulated lobes.

5-8 November 2014 - Harbiye Military Museum & Cultural Center - İstanbul / Turkey

An incision was made on the buccal mucosa below and behind the orifice. The mass was reached by dissecting buccinator muscle. Buccinator artery was passing through the tumour mass. The tumour was extirpated by resection of the fatty tissue, which was consisted of two masses, 4 cm and 5 cm in diameters respectively. Both masses were partly encapsulated, but lobulated and appeared as normal fatty tissue. The tissue was fragile in consistency and was easily fragmentizing. The specimen was sent for histopathological examination. The surgical wound was closed primarily by single stiches.

RESULTS

Microscopically sections revealed a tumour consisting of adipose tissue, some connective tissue in the periphery and blood vessels. In some areas adipose tissue was seen in close proximity to the neighbouring striated muscle bundles. The tumour was indistinguishable from normal adipose tissue. Histopatological diagnosis was " Simple Lipoma of BFP".

Postoperative follow-up of the patient in the first month was uneventful.

CONCLUSION

The BFP is intimately associated with the parotid duct and the facial nerve. Additionally ligaments that anchor the BFP, serve as entry points of vessels. The buccinator branch of the facial artery in the mass should be considered during the surgery of this specific tumour. Although MRI scan revealed that the mass was encapsulated, it could not be easily detached from the surrounding healthy tissue. This was in consistent with the histopathological findings. Therefore the tumor must be followed closely.

Keywords: Buccal Fat Pad, Lipoma, Surgery

PP-072

The Efficacy of Informed Consent in Lower Third Molar Surgery

Ibraz Siddique, Alan Robert Patterson

Department of Oral and Maxillofacial Surgery, Rotherham General Hospital, Rotherham, United Kingdom

INTRODUCTION

Third molar surgery under local anaesthetic occupies a significant proportion of outpatient workload in Oral and Maxillofacial Surgery. Clinicians must not assume that patients are aware of apparently obvious risks. It is a legal responsibility to obtain valid consent and there are seven recognised complications including pain, infection, bleeding, local swelling, damage to the inferior alveolar nerve, damage to the lingual nerve and trismus. Studies in the fields of general and orthopaedic surgery have found poor patient recall of important risk factors documented in consent forms. Studies have also shown that patient recall of risks is likely to be reduced if not supported by various methods including written information and reinforcement.

METHOD

A national study of Oral and Maxillofacial surgery departments using an anonymous semi-structured patient questionnaire was used for data collection. This was used to assess post-operative patient recall of risks associated with lower third molar surgery carried out under local anaesthetic and to identify the risks that were identified poorly.

RESULTS

146 completed questionnaires were data analysed. Respondents comprised 70 males (48%) and 76 females (52%) with a mean age of 26 years and 4 months. The risk of a numb lip (49%) was the most common risk factor recalled followed by a numb tongue (38%), bleeding (15%), swelling (14%), infection (10%) and pain (7%). Only 2% of patients recalled trismus as a possible complication.

CONCLUSION

Patient recall of risks associated with lower third molar extractions is poor. 24% of patients could not remember being informed of risks on the day of the procedure despite signing a consent form. The risk of lip numbness (49%) was the most likely to be recalled by patients. Trismus (2%) was the least likely risk to be recalled by patients despite studies stating this complication to have the most likely detrimental impact on the patients' quality of life over the short post-operative period. We advise a written consent form to be completed on the patient's first clinic visit to allow a cooling off period and confirmation of consent on the day of the procedure. Written information leaflets reinforcing the consent process should be encouraged due to existing evidence supporting their efficacy.

Keywords: Informed; consent; risks; third; molar

PP-073

Obesity and Conscious Sedation: The Biopsychosocial Approach for the Surgical Patient

Tanu Bhat

Department of Sedation and Special Care Dentistry, Kings College London, London, UK

BACKGROUND

As the prevalence of obesity increases, the barriers to oral surgery care within this patient group need to be recognised. Obese individuals may have resulting impairments which predispose them to social and biomedical barriers when seeking health care. Measures to minimise these barriers are being implemented within the field of medicine and should also be considered within Oral and Maxillofacial Surgery.

OBJECTIVE

To review the literature and recent guidance pertaining to the social, biomedical and sedation aspects of obese patient care and identify practical risk assessment tools.

Design: Literature-based review.

Limitations: English language literature and UK adopted guidance only.

RESULTS

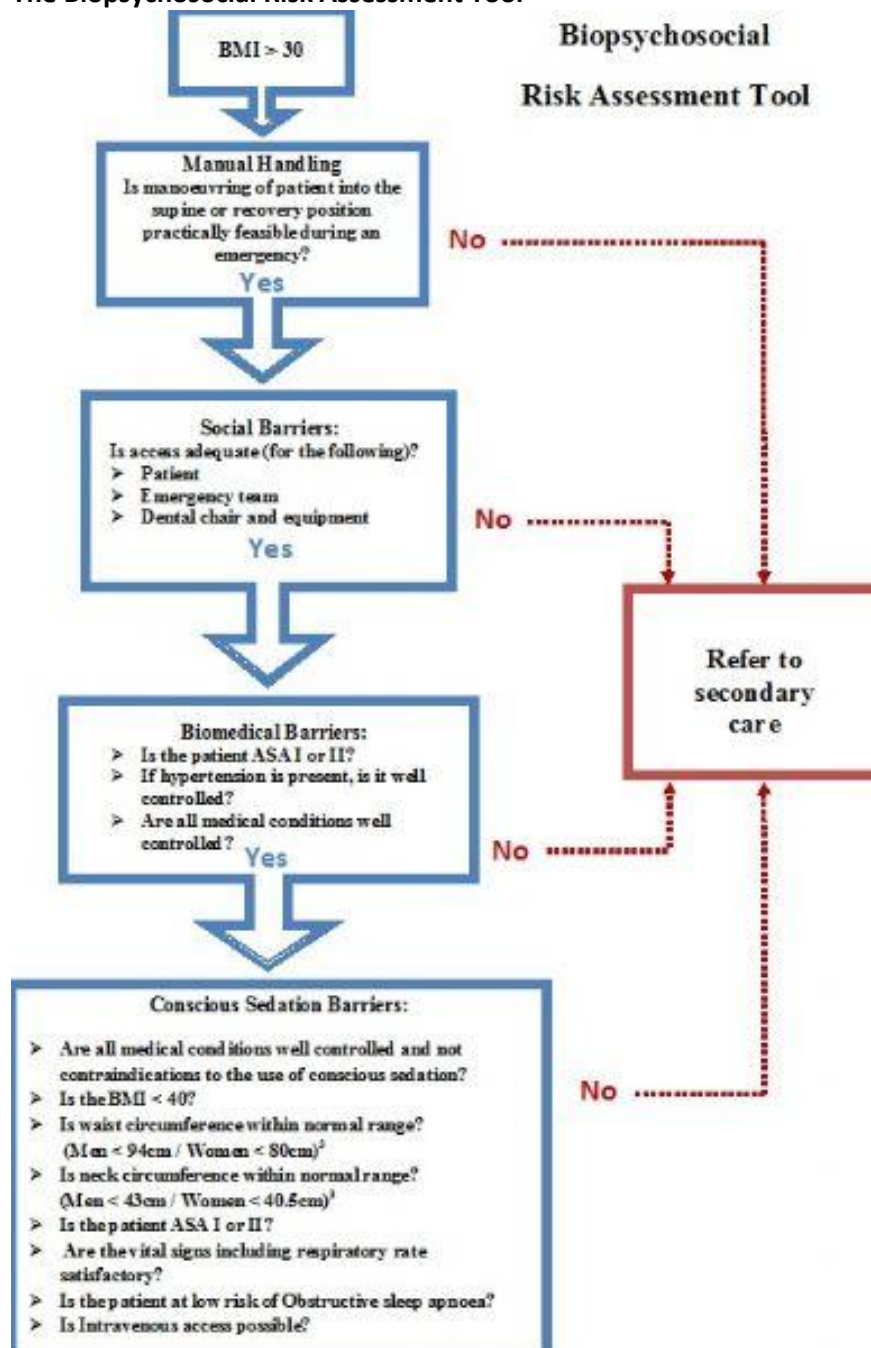
Body mass index alone is insufficient as a risk assessment tool for conscious sedation. Further research is required to identify more reliable risk assessment tools or alternative measures such as waist and neck circumference to allow consideration of the various biomedical barriers to patient care. Current UK adopted guidance recognises that impairments brought on by obesity may lead to disability and associated social barriers to patient care must also be addressed.

CONCLUSION

There are numerous complicating social and biomedical factors requiring further consideration to achieve safe and effective patient management for overweight/obese patients. Specific to conscious sedation in oral surgery, this patient group presents an array of respiratory risks which have not yet been explored thoroughly in oral and maxillofacial research.

Keywords: obesity, overweight, conscious sedation

The Biopsychosocial Risk Assessment Tool



Risk assessment tool developed from the literature review.

PP-074

Surgical Emphysema and Pneumomediastinum Following Third Molar Surgery

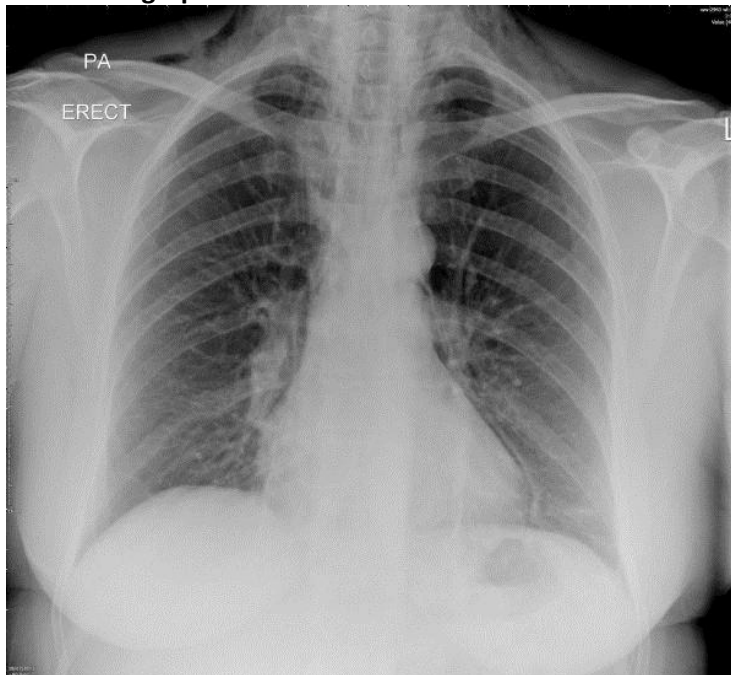
John Collin, Constance Wong, Steven Thomas, Cari Hughes

Department of Oral and Maxillofacial Surgery, Bristol Royal Infirmary, Bristol, UK

We describe the presentation and management of a case of cervico-facial emphysema and pneumomediastinum following coronectomy of. A previously well 48 year-old woman was referred by a community oral surgeon to the OMFS team on-call with bilateral cervico-facial swelling immediately after coronectomy of the lower right third molar. Bilateral, periorbital, maxillary and cervical surgical emphysema was evident clinically; a plain chest radiograph demonstrated pneumomediastinum in addition. The potential sequelae and management options for this condition are discussed. We also summarise a literature search that identified 2 review articles spanning 1960-2008 and 10 case reports of surgical emphysema following dental extractions from 1946 to 2013. Thirty-seven of the cases involved the extraction of a lower third molar and 7 cases were associated with extraction of maxillary teeth. Most cases were associated with subcutaneous emphysema and 3 cases involved pneumothorax. There were no previous reports following coronectomy. Despite multiple reports in the literature, some practitioners still do not appreciate the risks of using air turbines during oral surgery.

Keywords: oral surgery, complications, coronectomy

chest radiograph



plain chest radiograph demonstrating emphysema and pneumomediastinum

PP-075**Comparative Evaluation of Surgical Outcomes of Platelet-Rich Fibrin and Piezosurgery After Removal of Impacted Mandibular Third Molars**

Kani Bilginaylar, Lokman Onur Uyanık

Oral and Maxillofacial Surgery, Near East University, School of Dentistry, Nicosia, TRNC

OBJECTIVE

The aim of this study was the comparison of postoperative outcomes (pain, the number of analgesics taken, swelling and trismus) in impacted third molars treated by platelet-rich fibrin or by combination treatment of PRF and piezoelectric surgery or by rotatory osteotomy technique.

METHODS

Twenty patients with bilateral impacted mandibular third molars were included in the study. The Patients were divided into two main group. In first group (10 patients), traditional surgery was used on 1 side with burs (Group 1), and traditional surgery was used and platelet rich fibrin was administered into the extraction socket on the other side (group 2). In second group (10 patients), ultrasound surgery was used and platelet rich fibrin was administered on 1 side (group 3), and traditional surgery was used on the other side with burs (group 4). There were at least 21 days between two operations of each patient. The parameters examined in each patient included: Pain, number of analgesics taken, trismus, and cheek swelling were evaluated at baseline (before surgery) and at the first, second, third and seventh-day visits postoperatively at approximately the same time of the day.

RESULTS

The study included twenty patients and 40 mandibular third molar extractions were performed. Statistical analysis showed a significant reduction ($p<0,05$) of postoperative pain in group 2 (PRF group). In addition combination action of PRF and piezoelectric surgery on pain, the number of analgesics taken and trismus (24 hours after surgery) was statistically significant ($p<0,05$) when compared with conventional handpiece. Swelling on the first, second, third and seventh postoperative days, there was no statistically significant difference between the groups ($p>0,05$). Also There was no significant difference in duration of surgery between the groups ($p>0,05$).

CONCLUSIONS

The effect of PRF and combination action of PRF and piezoelectric surgery can be considered a safe and fine technique for reducing the outcomes after impacted third molar surgery.

Keywords: PRF, Piezosurgery, impacted Third Molar

PP-076

Spontaneous Healing of a Submental Fistula Due to A Periapical Lession Treated with Platelet-Rich Fibrin

Lokman Onur Uyanık, Kani Bilginaylar

Oral and Maxillofacial Surgery, Near East University, School of Dentistry, Nicosia, TRNC

OBJECTIVE

In this presentation spontaneous healing of a submental fistula related with a periapical lesion treated by apical resection and platelet-rich fibrin (PRF) application is presented.

METHODS

21 years-old male patient who had a submental fistula referred to our clinic with a history of 3 months of infection and pus drainage. Clinical and radiographical examination showed that there was a periapical lesion at tooth number 41. Apical resection with excision of the fistula was advised to the patient but he didn't accept an extra oral intervention so only an apical resection was performed and PRF was administered into the cavity and a PRF membrane was used to close the site as well.

RESULTS

The fistula and the lesion was healed uneventfully after 3 months both clinically and radiographically.

CONCLUSION

We observed an uneventful healing of a fistula after apical resection and application of PRF on the operation side.

Keywords: Apical Resection, PRF, Submental Fistula

PP-077

Management of Keratocystic Odontogenic Tumour with Marsupialisation: A Case Report

Çağrı Pirpiri¹, Ümmügülsüm Coşkun¹, Fatih Taşkesen², Cem Üngör¹

¹Department of Oral and Maxillofacial Surgery, Faculty of Dentistry, Karadeniz Technical University, Trabzon, Turkey

²Special Clinic, Trabzon, Turkey

AIM

This case report aims to present a keratocystic odontogenic tumor (KCOT) treated with marsupialization and enucleation.

CASE

A 23 years-old male patient representing a radiolucent lesion associated with third molar in his left mandible on OPTG was referred to our clinic. After intraoral examination we have decided to perform an incisional biopsy and marsupialisation simultaneously. After two-year marsupialization period the tumor was removed via enucleation with no inferior alveolar nerve damage.

RESULTS

The patient represented no paraesthesia in lower lip and the left mandible was seen in intact bony structure at one-year follow up period with no sign of recurrence.

CONCLUSION

This case shows that a large KCOT can be treated successfully via marsupialisation and enucleation in well-controlled cases.

Keywords: keratocystic odontogenic tumour, marsupialisation, enucleation.

PP-078

Recurrent Odontogenic Myxoma of Mandible and Its Surgical Treatment: A Case Report

Zeynep Gümrükçü¹, Yavuz Tolga Korkmaz¹, Onur Yılmaz¹, Sümeyra Has²

¹Department of Oral and Maxillofacial Surgery, Faculty of Dentistry, Karadeniz Technical University, Trabzon, Turkey

²Department of Pathology, Faculty of Medicine, Karadeniz Technical University, Trabzon, Turkey

Odontogenic myxoma is known as a rare benign mesenchymal odontogenic neoplasm in oral cavity. Tumor is seen most frequently in mandible. Radiologically, the lesion can be seen unilocular radiolucency or multicystic lesion with well-defined or diffused margins. The radiographic appearance can be defined as "honey combed, soap bubble or tennis racket". The treatment of myxoma is surgery. Curettage, enucleation and resection are the treatment choices that can be applied. Due to the aggressive and invasive behavior of the tumor the recurrence is possible. A 17 years old female patient referred to our clinic with pain on right third molar area. Clinical and radiographic examination revealed a lesion in mandibular premolar region, in a relation with right premolar roots. Orthopantomograph (OPG) showed a multilocular radiolucency with well developed locules, consisting of fine trabeculae. An excisional biopsy has been performed under sedation anesthesia and the tumor removed completely. Histopathological examination revealed odontogenic myxoma. After surgery, patient followed by periodic radiological examinations together with intraoral and clinical examination in six month intervals. At the twenty-fourth month follow-up, recurrence symptoms were observed in OPG and the patient operated under local anesthesia via marginal resection. At the forty-eighth month follow-up the second recurrence was observed in OPG. Myxoma is associated with a high rate of recurrence due to its uncapsulated nature. Recommended therapy varies from curettage to radical excision. Prolonged surveillance is required due to the risk of recurrence.

Keywords: odontogenic myxoma, surgical treatment, recurrence

PP-079

Unexpected Complication of Tooth Extraction: A Case Report

İbrahim Murat Afat, Faysal Uğurlu, Onur Gönül

Department of Oral and Maxillofacial Surgery, Faculty of Dentistry, Marmara University Istanbul, Turkey

Tooth extraction is one of the common surgical procedures of the dentistry. Although it is easy to perform, has some complications as well. These complications commonly are tooth fracture, trismus, fracture of cortical plates and dry socket. Wound infection, postoperative pain and hemorrhage encountered less frequently. Luxation of adjacent teeth, fracture of maxillary tuberosity, and displacement of tooth into adjacent tissue spaces were rare complications. Besides these complications; there are some extraordinary and unexpected complications can occurred as well. In this presentation one of these extraordinary complications is going to be focused on; a healthy 20 years old female dentistry student, who had orthodontic fixed appliance treatment which start 2009 and end in 2011 in a private clinic, came to our clinic for a check-up. During the radiological examination a metallic object seems like an orthodontic bracket between lower right canine and second premolar tooth was diagnosed. Management involved surgical removal of orthodontic bracket and curettage of the cavity are going to present in this case report.

Keywords: iatrogenic effects, tooth extraction, complication

PP-080

Comparison of Lornoxicam and Aspirin with and without Sedation on the Effect of Postoperative Pain and Swelling after 3rd Molar Surgery

Ozkan Ozgul¹, Selahattin Or²

¹Department of Oral Maxillofacial Surgery, Ufuk University, Ankara, Turkey

²Department of Oral Maxillofacial Surgery, Ankara University, Ankara, Turkey

Different surgical techniques and/or different drugs that have been used and still being used in order to limit and eliminate edema, trismus and pain after surgical removal of impacted teeth. The purpose of this study is to evaluate the effects of lornoxicam and also conscious sedation on pain and swelling after third molar surgery compared with aspirin.

The study was conducted as randomized double blinded, 60 systemically healthy patients that participated in the study all had full bone retention 3rd molar teeth that had the need of extraction. The patients consisted of young healthy adults whom signed the consent form with similarly difficult molar teeth. The patients were randomly divided in to two groups one group had conscious sedation

during the operation the other group undergone the standard local anesthesia procedures. Two main groups have been divided in to 3 subgroups according to postoperative drugs they were lornoxicam, aspirin and placebo. The measurements from the reference points have been measured before and 48 hours after the surgery. These measurements were used to calculate the swelling. Pain scores were evaluated by VAS at 6, 12 and 24th hours.

The patients whom used aspirin showed less pain scores than local anesthesia on 6 and 12th hour placebo. Comparing the conscious sedation and routine local anesthesia, sedation was statically better in pain reduction. The methods used for reducing the uncomfortable period after the third molar surgery that affects the patients social activities in our study presented meaningful results. There have been several methods such as NSAİ drugs, laser applications, steroid applications, ultrasound applications tried out over the years and there will be many more methods to be tried. The existing studies do not eliminate the need of new studies yet.

Keywords: lornoxicam; sedation; 3rd molar surgery; pain; swelling.

PP-081

Sialolithiasis of Wharton Duct with Tuberculous Cervical Node Calcification

Murat Ulu¹, Özgür Gözlüklü¹, Muhammed İsa Kara¹, Hüseyin Akçay¹, Fahrettin Kalabalık²

¹izmir katip çelebi university department of oral and maxillofacial surgery

²izmir katip çelebi university department of oral and maxillofacial radiology

OBJECTIVE

Salivary stones represent grit blocking salivary ducts, thus preventing saliva drainage and causing gland enlargement. Usually occurs in middle-aged adults, with a slight male preponderance. The cause is unknown, but stones commonly occur in patients with chronic sialoadenitis. These stones are predominantly made of calcium phosphate on an organic matrix. Gout predisposes to stones made of uric acid. Calcifications found in routine and normal radiographs of the major salivary glands are usually related to sialolithiasis or calculus formation in the corresponding salivary gland. However, the encountered radiological finding may only be located in the vicinity of the salivary gland. Thus, one must be aware of the variety of clinical signs and symptoms and the relevant treatment modalities. The most frequently encountered entities are calcified lymph node, tuberculosis or scrofula of lymph node, tuberculosis of the salivary gland itself, osteoma cutis or multiple miliary skin osteomas, calcified acne, phleboliths, haemangiomas and lymphangiomas, atherosclerotic plaques in major blood vessels such as in the carotid arteries, myositis ossificans and, finally, metastasis from distinct calcifying neoplasms.

A declining incidence in cases of tuberculosis had been occurring in our society. Extrapulmonary tuberculous involvement has been reported to account for 22% to 30% of all cases of tuberculosis. Head and neck lymphadenopathies represent the most common form of lymph node involvement and have been reported in up to 39% of extrapulmonary cases.

CASE REPORT

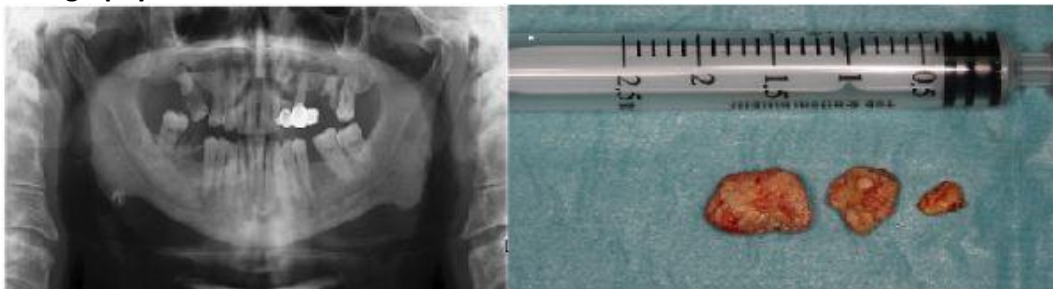
51-year-old male was referred to our department due to pain, intermittent swellings of her right cheek, hyposalivation and general discomfort in her right facial region. His past medical history revealed that he diagnosed with lung tuberculosis in 2005. For this reason he operated from lung due to the unidentifiable radioopaque lesion in his lung. The histopathological results were consistent with tuberculosis of lung. In clinical and radiological examination we diagnosed 3 parts of calcified object in wharton duct and an another radioopaque lesion inferior angulous of mandible.

CONCLUSION

We decided to operate patient under local anesthesia. Salivary duct stones removed and drain was placed in duct until epitelisation completed. In post operative 3 weeks control everything looks seamlessly and patient was without any complaint. A presumptive diagnosis of calcified lymph nodes secondary to healed tuberculous cervical lymphadenitis was made..

Keywords: sialolithiasis, tuberculosis, salivary gland, lenfadenitis

radiography and removed stones



PP-082

A Case Report: Reconstruction of Defect at Maxillar Right Central Incisor Region with Chin Graft

Onur Koç, Nuray Er, Duygu Uçar

Hacettepe University Oral and Maxillofacial Surgery Ankara/TURKEY

Defects of the mandible may result from treatment of benign and malignant tumours, cysts, congenital abnormalities, trauma, infections, and osteoradionecrosis. The ideal goal of reconstruction is to achieve sufficient anatomical bulk (height and width) of the maxilla that will accommodate implant insertion and adequate muscle attachments to allow for normal form and function.

Autogenous or allogenic grafts, biological ceramics, bioactive glass, nano-materials, hydroxyapatite, calcium phosphate, and calcium sulfate demineralized bone matrices, synthetic bone pastes, semisynthetic scaffolds, alloplastic materials, adipose derived stem cells and tissue engineering strategies using recombinant bone morphogenetic proteins are all used to repair bone defects at

maxilla. Autogenous bone is still considered the gold standard graft material for bone augmentation procedures in the maxillofacial region.

Restoration of the form (esthetics) and function (mastication, deglutition, and saliva control) have been achieved by the use of autogenous grafts harvested from intra oral donor sites like ramus, chin, tuber maxilla and extra oral donor sites like the iliac crest, rib, radius, fibula, tibia, scapula, and calvarium. The choice of a particular donor site for grafts depends on the type and extent of hard tissue defect, rehabilitation expectation of the patient, condition of the recipient bed. At this case presentation the patient who is 50 years old male had an operation 1 year ago from right central incisor region because of radicular cyst which is depend right central incisor. The dimension of defect was evaluated by CT and seen 4cm*3cm unhealed bone. At this case we used mandibular chin graft which has adequate depth and amount to reconstruct the defect at maxilla.

Keywords: maxillary defect, chin graft, otogenic block graft, cyst defect

PP-083

Surgical Management of a Large Complex Odontoma Via Extra-Oral Buccal Approach-Report of a Case

Bora Özden¹, Burcu Baş¹, Seda Yılmaz², Alper Alkan³

¹Department of Oral and Maxillofacial Surgery, Ondokuz Mayıs University, Samsun Turkey

²Department of Oral and Maxillofacial Surgery, Aydın University, İstanbul, Turkey

³Department of Oral and Maxillofacial Surgery, Erciyes University, Kayseri, Turkey

OBJECTIVE

Odontomas are a nonaggressive tumorlike developmental malformations that contains odontogenic epithelium with odontogenic ectomesenchyme. The complex odontomas are made up of amorphous and randomly arranged masses of dentin, enamel, and cementum lacking tooth structure. The etiology of odontomas is unclear. Most odontomas are asymptomatic although unerupted teeth, delayed eruption of permanent teeth, swelling, or an infection may indicate their presence. The treatment of choice is surgical excision. We present a case of large complex odontoma located at the mandibular angle treated by extraoral approach.

Case Reports: A 43-year-old male patient was referred to our clinic with a history of painful swelling at the right posterior mandibular area and trismus for the last two years. Clinically, there was gross facial asymmetry with diffuse smooth swelling in the right mandibular angle region. Mouth opening was not adequate. A Panoramic radiograph showed uniformly dense rounded radiopacity (about 3x2cm). Under general anesthesia, access to the mass achieved via an extraoral approach. The tumor was totally excised. Histopathologic examination of the excised mass confirmed the diagnosis of complex odontoma. Recovery and immediate post-operative period were uneventful. There was no altered sensation in the distribution of the inferior alveolar and lingual nerve.

5-8 November 2014 - Harbiye Military Museum & Cultural Center - İstanbul / Turkey

CONCLUSION

The surgical removal of an odontoma is often performed by intraoral approach. In this case an extraoral approach was preferred due to the reduced accessibility to the lesion intraorally.

Keywords: complex odontoma, extraoral, surgical excision

PP-084

Treatment of Unerupted Maxillary Second Molar Associated with Impacted Third Molar and Supernumerary Tooth: A Case Report

Berkay Tolga Süer¹, Ersin Yıldırım², Şeniz Karaçay²

¹GATA Haydarpaşa Eğitim Hastanesi, Diş Hekimliği, Ağız, Diş ve Çene Cerrahisi, İstanbul, Türkiye

²GATA Haydarpaşa Eğitim Hastanesi, Diş Hekimliği, Ortodonti, İstanbul, Türkiye

AIM

The aim of this poster is to present the multidisciplinary treatment of an adult patient who had an unerupted maxillary second molar due to an impacted third molar and supernumerary tooth.

CASE: A 22-year-old male patient was referred to our clinic with a complaint of toothache at the left tuber region. In the intraoral examination, it was observed that second and third maxillary molar teeth were absent at that side. Panoramic radiograph was taken and a supernumerary tooth positioned at the mesial side of the impacted third molar was diagnosed. Due to the impacted third molar and impacted supernumerary tooth, eruption of second molar was prevented. Impacted third molar and supernumerary tooth were surgically extracted and an orthodontic button with gold chain was placed on the unerupted second molar at the same session. One week later, brackets were bonded on the maxillary teeth and a transpalatal arch was attached on the first molar bands to reinforce the anchorage of the related teeth. Following the leveling phase, rectangular stainless steel arch wire was placed and an uprighting spring bended from a 0.16x0.22 wire was inserted to the left molar band. Eruption force was applied to the unerupted second molar through the uprighting spring and it was activated with 4 weeks intervals. After 8 months the second molar tooth erupted.

CONCLUSION

Eruption of impacted second molars may be provided with multidisciplinary treatment approach.

Keywords: Third Molar; impaction; supernumerary; unerupted

PP-085**The Unerupted Maxillary Second Molars Due to Overlying and Malformed Impacted Third Molars:
A Case Report**Berkay Tolga Süer¹, Ersin Yildirim², Mustafa Erkan²¹GATA Haydarpaşa Eğitim Hastanesi, Diş Hekimliği, Ağız, Diş ve Çene Cerrahisi, İstanbul, Türkiye²GATA Haydarpaşa Eğitim Hastanesi, Diş Hekimliği, Ortodonti, İstanbul, Türkiye**AIM**

This study presents the treatment and follow-up of left impacted upper second molar and unerupted right molar associated with an impacted and mesial tipped third molars.

CASE: A 19-year-old otherwise healthy male patient was referred to our clinic by general dentist with a main complaint of malocclusion and unerupted teeth. Intraoral examination of the patient was revealed Class III molar relationship and crowding depending on space deficiency of maxillary and mandibular dental arches. It was also noted that the maxillary second molar was not erupted at the both sites. Orthopantomograph (OPG) showed that overlying and malformed upper third molars were hindering the eruption of the second molars and close approximation of the roots of the second molars to the maxillary sinus. However, OPG did not give detailed information about the anatomy and malformation of the third molars, and degree of the involvement of the sinus. Due to necessity, Cone Beam Computed Tomography (CB-CT) was taken. The treatment plan for the patient was removing the third molars, forced eruption to the unerupted second molars and bimaxillary orthognathic surgery to treat Class III malocclusion. The third molars were removed surgically under local anesthesia setting. During the extraction surgery, it was noted that he positions and anatomy of the third molars were interesting. After the removal of the abnormal third molars, radiographic examination showed that second molars started to erupt.

CONCLUSION

The authors of this study think that the Class III malocclusion due to maxillary skeletal deficiency caused the anatomic form and position anomaly of the third molars.

Keywords: Unerupted tooth; surgery; impaction; third molar; malformation

PP-086

Prevention of Iatrogenic Mandibular Fracture Associated with Deeply Impacted Tooth Removal

Meltem Ozden, Banu Ozveri Koyuncu, Tayfun Gunbay
Department of Oral Surgery, Ege University School of Dentistry, İzmir, Turkey

OBJECTIVE

The presented case reports the importance of prophylactic plating to avoid mandibular fracture in patients who have deeply impacted teeth in lower arch that will be extracted.

METHODS

A 43 year old female was referred to the Department of Oral and Maxillofacial Surgery because of a recurrent "toothache" of the right lower molar area. At radiographic examination the presence of deeply impacted third molar that was surrounded by a well-circumscribed radiolucency was revealed. Impacted tooth was exposed and removed carefully. A straight titanium 2.0 mm miniplate with 6 holes was premodeled and adapted to the buccal cortical bone.

RESULTS

In the case presented here; the patient's preoperative panoramic radiography shows the insufficient distance between the apex of the tooth and inferior border of the mandible. This case is fully deep impacted which has higher incidence of mandibular fracture so implementation of preventive procedures should have been done during the operation.

CONCLUSION

In difficult surgical extractions; bone removal should be minimal, correct instrumentation should be used and the clinician should avoid excessive force to prevent intra-operative mandible fractures. Additionally, prophylactic use of miniplates during the surgery can be a good method to prevent this complication.

Keywords: Iatrogenic fracture; Tooth removal; Prevention

PP-087

Endodontic Paste Penetration Both in Maxillary Sinus and Mandibular Canal: Report of a Case Treated by Piezosurgery

Meltem Ozden, Gozde Cıplak, Banu Ozveri Koyuncu, Tayfun Gunbay
Department of Oral Surgery, Ege University School of Dentistry, İzmir, Turkey

OBJECTIVE

The presented case reports endodontic paste penetration both in maxillary sinus and mandibular canal in the same patient and treatment options.

METHODS

A 35 year old female patient was referred to the Oral and Maxillofacial Surgery Department because of prolonged anesthesia in her left mandibular region and orbital pain in her left maxillary molar region, which developed following an endodontic therapy. At radiographic examination the presence of well defined radioopaque material revealed in the inferior alveolar canal region and in the periapical area maxillary first molar tooth. It was decided to remove the material in inferior alveolar canal and maxillary sinus by using piezosurgery. Bone flap was removed and root canal filling material with the inflammatory tissue around it extricated carefully. Bone flap inserted in its place with using screws.

RESULTS

Because of close proximity and anatomy, during root canal treatment over instrumentation and filling causes the root canal filling materials pushing into the maxillary sinus and mandibular canal. Surgical removal of root sealer from these vital anatomical structures is an effective treatment and often complete resolution of anesthesia, paresthesia and pain.

CONCLUSION

Clinical success of the case presented here demonstrates the good results obtained with piezoelectric surgery for removal of root canal filling material without damage to any anatomical structures. However, to avoid this complication, dental practitioners should take some precautions such as careful instrumentation of root canals and use of necessary amount of root canal paste. When this complication occurs, the appropriate treatment method should be selected based on the patient's medical history and his/her complaints.

Keywords: Inferior alveolar nerve injuries; Foreign body; Extrusion of endodontic paste materials

PP-088

A Case Report of Compound Odontoma Associated with an Unerupted Maxillary Lateral Incisor

Eda Arat Maden¹, Tamer Zerener², Ceyhan Altun¹, Pinar Kutlu³

¹Department of Pediatric Dentistry, Gulhane Medical Academy, Ankara, Turkey

²Department of Oral and Maxillofacial Surgery, Gulhane Medical Academy, Ankara, Turkey

³Department of Orthodontics, Gulhane Medical Academy, Ankara, Turkey

AIM

Odontomas generally appear as small, solitary or multiple radio-opaque lesions found on routine radiographic examinations. Traditionally, odontomas are the most common type of odontogenic tumor and they are generally asymptomatic. Occasionally, odontomas may cause disturbances in the

eruption of teeth, such as impaction, delay eruption or retention of primary teeth. In general, odontomas occur more often in the permanent dentition. This is a case report of a compound composite odontoma in an 12-year-old boy, which has resulted in failure of eruption of the permanent upper right lateral incisor while the contra-lateral tooth had erupted.

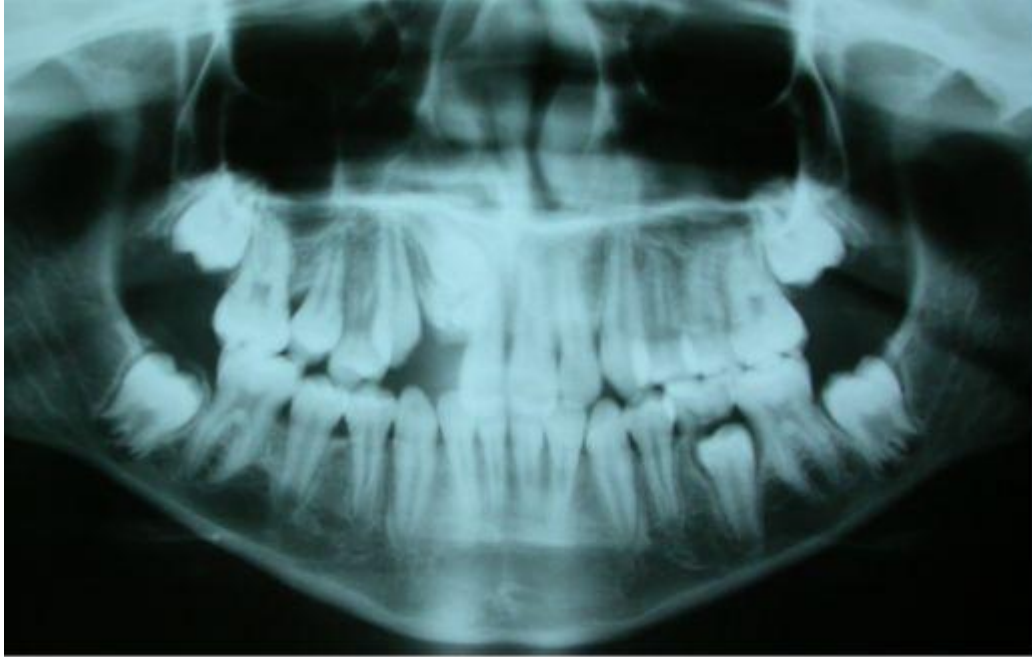Case Report: An 12-year-old male patient referred to the Pediatric Dentistry Department with a complaint of delayed eruption of the maxillary right permanent lateral incisor. Periapical radiographic evaluation of the upper anterior segment revealed a single lesion of an odontoma covering the crown of an unerupted permanent maxillary right lateral incisor. The initial radiographic diagnosis was a compound odontoma associated with an unerupted permanent maxillary right lateral incisor and it was also confirmed histopathologically. After that the patient was referred to the Oral and Maxillofacial Surgery Department. The compound odontoma was completely removed under local anesthesia. Surgical exposition of the crown and bonding of an orthodontic appliance for traction was done to facilitate eruption. The patient is on clinical and radiological follow up for eruption of the permanent maxillary right lateral incisor.

CONCLUSION

The compound odontomas are frequently associated with impaction or delayed eruption of incisors in the anterior maxillary segment and should be suspected in cases of delayed impaction and non-eruption of teeth. The treatment was considered a success, since both health and aesthetics of the smile were recovered. The importance of the clinical and radiographic diagnosis of the retention of a permanent tooth associated with a pathological entity should be emphasized. The participation of a multidisciplinary team to accomplish the appropriate treatment of such patients is extremely relevant because of the esthetic and functional ramifications of a missing anterior tooth as well as the psychological well-being of the individual.

Keywords: lateral incisor, odontoma, orthodontic appliance

Panoramic radiograph revealed odontoma obstructing path of permanent tooth.



PP-089

Noninvasive Treatment Choice for a Large Radicular Periapical Cyst at Mentum and Its 8 Years Follow Up

İbrahim Murat Afat, Onur Gönül, Faysal Uğurlu, Emine Tuna Akdoğan, Mehmet Kamil Göker
Department of Oral and Maxillofacial Surgery, Faculty of Dentistry, Marmara University Istanbul, Turkey

The aim of this case report is to illustrate the marsupialization as an effective treatment for a patient with hypertension, presenting a radicular periapical cyst. And its 8 years follow up.

Radicular cysts are the most common cystic lesions which affect the jaw. They are most common among all the jaw cysts and comprise about 52% to 68% of the entire cysts which affect the human jaw. The treatment of radicular cysts includes conventional nonsurgical root canal therapy when lesion is localized or surgical treatment like enucleation, marsupialization or decompression when lesion is large.

The 61 year-old patient represented herein received a minimally invasive marsupialization under local anesthesia. Iodoform gauze dressing was inserted within lesion cavity in order to keep wound opening and decompression. Through the following period, Medication gauze was changed every 4 days and irrigation of the cystic cavity with saline solution was carried out to prevent a secondary

infection within the cystic cavity. 22 months after the first visit, the lesion had completely withdrawn. A follow-up of 8 years showed no signs of recurrence.

Marsupialization poses as a minimally invasive choice for the patient, even when presenting advanced ages; treatment success was stated by the easy clinical conduct, uneventful postoperative situation and the lack of recurrence along 8 years of follow-up. Marsupialization of radicular periapical cyst is effective and safe, even for systemically compromised patients of advanced age. Marsupialization is a reliable treatment for large cysts of jaw. Careful evaluation of the advantages and disadvantages is essential for the success of the treatment.

Keywords: jaw cysts; radicular periapical cyst; marsupialization

PP-090

Comparison of Graft Resorption in Maxillary Sinus Augmentation Using Porous Titanium Granules and DBM Putty Allogenic Graft: In Rabbit Study

Ferhat Ayranci¹, Metin Güngörmüş², Mehmet Melih Ömezli¹, İsmail Akkaş³

¹Department of Oral Maxillofacial Surgery, Faculty of Dentistry, Ordu University, Ordu, Turkey

²Department of Oral Maxillofacial Surgery, Faculty of Dentistry, Gaziantep University, Gaziantep, Turkey

³Department of Oral Maxillofacial Surgery, Faculty of Dentistry, Abant İzzet Baysal University, Bolu, Turkey

OBJECTIVE

Alveolar bone resorption due to loss of teeth and maxillary sinus pneumatization reduces the distance that is extending from the floor of maxillary sinus to the alveolar crest. In severely resorbed maxilla sinus lift procedures have been used to facilitate the placement of osteointegrated implants. These procedures require the use of graft materials to sustain the augmented space and to promote osteogenesis. Autograft, allograft, xenograft, and alloplast are obtainable various graft materials for sinus augmentation. Autogenous bone is regarded as the gold standard, however morbidity at the donor site, risk of infection, prolonged wound drainage, and large hematomas necessitate to investigate alternative graft materials. The aim of the present study was to compare the vertical dimensional changes with regard to graft height in rabbits treated with two different grafting materials used in maxillary sinus floor elevation procedures, namely porous titanium granules and putty form allograft.

METHODS

Twelve New Zealand male rabbits, each weighing between 2,7 to 3,3 kg were used for this study. 24 maxillary sinus floor elevation surgeries in all twelve animals were made and randomly repaired, with the following two groups: porous titanium granules and putty form mineralized human bone allograft. The left sinus filled with porous titanium granules (Natix, TigranTechnologies AB, Malmö, Sweden) and the other was filled with putty form demineralized human bone allograft (Berkeley

5-8 November 2014 - Harbiye Military Museum & Cultural Center - İstanbul / Turkey

Advanced Biomaterials Inc. Berkeley, USA). After the surgery cone beam tomography (NewTom FP, Quantitative Radiology, Verona, Italy) was used to determine grafted maxillary sinus height. The groups received same surgical procedures and evaluation were sacrificed at postoperatively 6 weeks. Four randomly selected sections from the serial sections collected from each sample were analyzed manually. The measurements were performed with decalcified specimens using a personal computer-based image analysis system (Stereo-Investigator 7.0, Microbrightfield, Colchester, VT). The augmented sinuses with porous titanium granules were stored at room temperature for drying, then mounted on metallic stubs, sputter-coated with gold, and examined with the SEM (EVO LS10, Zeiss, Oberkochen, Germany).

RESULTS

Immediately after the surgery augmented height was not significantly different in both porous titanium and allogenic graft materials used in maxillary sinus augmentation in cone-beam CT assays. However after postoperatively 6 weeks, residual graft height was statistically higher at the porous titanium granules.

CONCLUSION

Porous titanium granules can be candidate for sinus lift bone augmentation prior to dental implants due to their osteoconductive properties and resistance to the resorption. However, clinical trials are needed.

Keywords: graft resorption, porous titanium granules, sinus augmentation

PP-091

Traumatic Bone Cyst of The Mandible. A Case Report

Saim Yanık¹, Ferhat Ayrancı², Naci Kazaz¹, Mutan Hamdi Aras¹

¹Department of Oral Maxillofacial Surgery, Faculty of Dentistry, Gaziantep University, Gaziantep, Turkey

²Department of Oral Maxillofacial Surgery, Faculty of Dentistry, Ordu University, Ordu, Turkey

OBJECTIVE

Traumatic bone cyst is an uncommon non-epithelium lined cavity and is seen frequently second decade of life. It may be incidentally diagnosed in during routine radiological examinations. Clinical features may comprehend asymptomatic lesion, with no bone expansion, most commonly located on the posterior mandible area. This case report aimed to describe the clinical and radiological characteristics, and surgical findings of traumatic bone cyst.

METHODS

13 year-old male patient referred to the oral and maxillofacial surgery department by general practitioner because of radiolucent lesion in the right lower jaw. Radiographic examination showed radiolucent lesion located in the mandibular ramus and angulus region. The patient did not report any pain and swelling. Extra oral and intraoral clinical examination showed all the structures were

5-8 November 2014 - Harbiye Military Museum & Cultural Center - İstanbul / Turkey

normal. Also related teeth were vital and right mandibular third molar was impacted. The patient underwent surgery under local anesthesia because of the biopsy procedure. The cavity of the lesion was empty and we did not encounter any cystic content during the operation. We stimulated bleeding in the cavity, and then the wound was sutured.

RESULTS AND CONCLUSION

The patient's postoperative 2 months follow-up exam was uneventful. The lesion showed progressive resolution and bone regeneration of the cystic cavity within a short period of time. If no tissue is found in the cavity for histopathological examination a decision on diagnosis of a traumatic bone cyst will depend on individual experience. Knowledge of the symptomatology, correct interpretation of the radiograph and correct recording of case history will be helpful when deciding on the diagnosis and relevant treatment.

Keywords: mandible, radiolucent lesion, traumatic bone cyst

PP-092

Accuracy of Maxillary Positioning During Le Fort 1 Osteotomies by Acrylic Wedge: A Technical Note

Secil Cubuk, Burak Bulmuş, Esra Beyler, Burak Bayram
Baskent University, Department of Oral and Maxillofacial Surgery

OBJECTIVE

Maxillary deficiency can be defined as deficiencies or hypoplasia of the maxilla in the transverse, anteroposterior and vertical dimensions. These deficiencies generally present in some combination with each other and/or other skeletal abnormalities. Inferior repositioning of maxilla is performed for correction of vertical deficiency and establishment of more esthetic tooth appearance. However achieving the planned position of the maxilla is dependent on vertical control of the maxilla during fixation procedure of the bone segments. Several techniques such as using intraoral or extraoral reference points, intraoral face-bow transfer and the three-split technique with positioning plates. We have presented a new technique of control the vertical position of inferior positioning maxilla during fixation and grafting.

METHODS

Two patients that had maxillary deficiency both in anteroposterior and vertical dimensions and mandibular excess anteroposteriorly had underwent bimaxillary surgery. Before surgeries the acrylic wedges of which thickness were the same amount of inferior movement were prepared. Le fort 1 osteotomies were performed in these patients. The acrylic wedges were placed to the space between bone segments following to down fracture. Stabilization and controlling of the vertical position of maxilla were obtained during grafting and fixation by these wedges. Following to fixation procedures the inferior movements of maxilla in two patients were same as the planned amount preoperatively.

CONCLUSIONS

5-8 November 2014 - Harbiye Military Museum & Cultural Center - İstanbul / Turkey

Using of acrylic wedge is a versatile, simple and noninvasive method for controlling the vertical position of maxilla in inferior repositioning surgeries of maxilla.

Keywords: Accuracy of Maxillary Positioning, Osteotomies, Acrylic Wedge

PP-093

How Well Does Kushida's Mathematical Model Predict Outcomes Following Maxillofacial Surgery for Obstructive Sleep Apnoea?

Shofiq Islam, Ian W Ormiston

Department of Maxillofacial Surgery, University Hospitals of Leicester NHS Trust, Leicester, UK

AIM

Several Mathematical formulas have been developed to clinically predict whether a patient is likely to suffer from obstructive sleep apnoea (OSA). Kushida's mathematical model incorporated body mass index, neck circumference, as well as oral cavity dimensions, and has been shown to have high sensitivity (97.6%), high specificity (100%). We explored how well the Kushida values of our OSA patients matched the morphometric models diagnostic thresholds. We also wished to ascertain the predictive potential of the preoperative Kushida index score and subsequent outcome following maxillofacial orthognathic surgery.

METHOD

We performed a retrospective analysis of patients who underwent MMA for OSA at our institution. Kushida morphometric scores were calculated using the described formula: $P + (Mx - Mn) + 3 \times OJ + 3 \times [Max (BMI - 25)] \times (NC \div BMI)$. [Where P = palatal height. Mx = maxillary intermolar distance between the mesial surfaces of the crowns of the maxillary second molars. Mn = mandibular intermolar distance between the mesial surfaces of the crowns of the mandibular second molars. OJ = overjet. BMI is the body mass index and NC is neck circumference]. Regression analysis was performed to explore the possible association between Kushida index score and outcome variables of postoperative apnoea/hypopnea indices (AHI) and Epworth Sleepiness Scores (ESS).

RESULTS

We identified 28 patients with complete data available for analysis. The mean age was 45 years (SD 6) with mean BMI of 28 (SD 3). All, but one patient underwent bi-maxillary procedure with or without genioplasty, with a mean advancement of 8.5 mm (SD 2). The mean Kushida index score in our sample was 79 (SD 14). 89% of patients had postoperative AHI <15 in keeping with surgical success. We found no statistically significant relationship with Kushida morphometric model variables and overall score with our outcome variables.

CONCLUSION

The mean Kushida index score in our patients was in the range consistent with the morphometric models diagnostic cut-off for OSA. Kushida's morphometric model does not appear to be a good predictor of postoperative success in individuals following MMA. The Kushida mathematical formula

5-8 November 2014 - Harbiye Military Museum & Cultural Center - İstanbul / Turkey

appears to be a simple screening test, with good sensitivity and specificity, and could be carried out by maxillofacial surgeon in outpatient clinics. This model represents a clinical adjunct in the preoperative work-up of patients referred for surgery, particularly in those subjects whose diagnostic sleep study is equivocal.

Keywords: Morphometric model; Kushida index; Maxillomandibular advancement surgery; Obstructive Sleep Apnoea; Diagnosis; Outcome

PP-094

The Soft Tissue Profile in Longitudinal Evaluation of Craniofacial Growth

Gokay Karapinar¹, Chad Bryan Carter², Onur Kadioglu², Frans Currier²

¹Istanbul University, Faculty of Dentistry, Oral and Maxillofacial Surgery Department, Istanbul, Turkey

²The University of Oklahoma, College of Dentistry, Oklahoma City, Oklahoma

The Denver Growth Study has a series of records from 1927 to 1967 for nearly 300 untreated individuals of Northern European decent which are equally distributed between males and females. The purpose of this study was to electronically transfer the standardized lateral facial photographs and identify the changes over time from childhood to adulthood.

The lateral photographs of 246 individuals (126 female / 120 male) were digitized using a 2-dimensional photographic scanner. There were 1133 female images from 6 months to 37 years and 1,190 male images from 1 year to 41 years 9 months. A sample of 17 females and 17 males were studied at multiple timepoints. T1 = <6 years, T2 = 6-8 years, T3= 8-10 years, T4= 10-12 years, T5 = 12-14 years, T6 = 14-16 years, T7 = 16-18 years, T8 (males only) = >18 years.

The various soft tissue measures were both angular (Facial Angle, Angle of Convexity, Mentolabial Angle, Nasolabial Angle, and Upper and Lower Z Angles), linear (Upper and Lower E-lines, Facial Lengths, Lower and Total Anterior Vertical Face Heights) and ratios (percentage of Lower Anterior Face Height). The digitized images were analyzed using soft tissue point placement in the OsiriX imaging software.

Analysis of the measurements showed distinct trends with time. Some trends identified were gender specific while others were consistent in both sexes. Facial angle was lower in boys as compared to girls, which was not true for Angle of Convexity. Girls demonstrated a greater decrease than boys in lower anterior vertical face height as a ratio over time. The Lower Z angle, which is the classic one used in most orthodontic diagnoses, was consistent over time. Male mentolabial angles increased over time while female mentolabial angles decreased. The Esthetic Lines (E-lines) were consistent with only a mild decrease over time for both sexes. While not a mirror of the hard tissue, these soft tissue values are key indicators of successful esthetic treatment outcomes.

Keywords: facial growth, soft tissue facial profile, growth study, craniofacial growth

5-8 November 2014 - Harbiye Military Museum & Cultural Center - İstanbul / Turkey

PP-095

Intravenous Lidocaine Infusion during Complex Orthognathic Surgery Decreases Opioid Requirement

Aziz Demirkilic, Panayota Kapessidou
C.H.U Saint Pierre, Brussel, Belgium

OBJECTIVE

IV lidocaine is increasingly used as an adjuvant during general anesthesia in various surgical settings. It has shown its effectiveness as a co-analgesic in major abdominal surgery, reducing perioperative opioids consumption. Specificities of orthognathic surgery include long duration, high morphine consumption during surgery associated with a lower level of post-operative pain. In this surgery, lidocaine is used routinely associated with adrenaline in local infiltration intraoperatively by surgeons. However, to our knowledge, its systemic administration has so far not been studied. Considering potential analgesic, anti-hyperalgesic and anti-inflammatory effects of IV lidocaine, it could be useful in polymodal analgesia for orthognathic surgery.

The aim of this pilot, prospective and double blind study was to evaluate the effect of IV lidocaine on pain during and after elective orthognathic complex surgery. We secondary studied the time course of biologic parameters reflecting inflammatory status.

METHODS

The study protocol was approved by the Ethics Committee of the institution. 20 patients were randomly allocated in 2 groups. In the first group, 10 patients received until the end of surgery an IV lidocaine solution: group "L" (bolus of 1.5 mg/kg followed by an infusion rate of 2mg/kg/h). The second group received the same quantities of a saline infusion: group "C". Depth of anesthesia was adjusted with propofol between 40 and 60 state of entropy. An increase of 15% of heart rate and/or of 20% of systolic blood pressure obtained after a premedication (considered as a sign of insufficient perioperative analgesia). The perfusion rate of remifentanyl was increased stepwise 0.05 µg / kg / min every 5 min. The amount of remifentanyl and propofol administered was recorded. In post-operative period, pain Visual Analog Scale (VAS) and opioid consumption were measured during 72 h. Plasma fibrinogen, CRP and leucocytes rates were performed until 24 h after surgery.

RESULTS

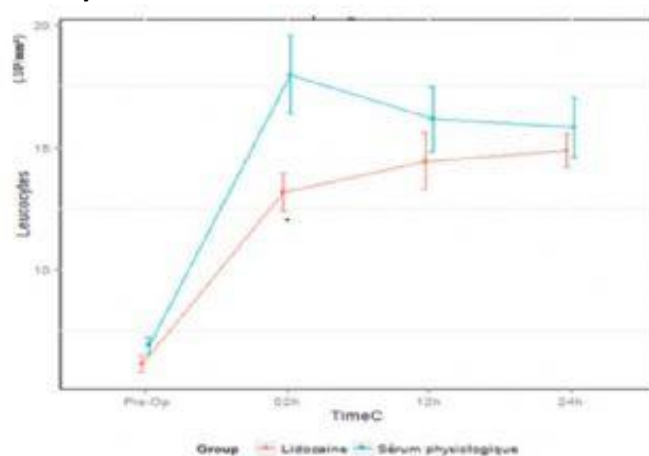
Demographics did not differ between both groups. Total opioid consumption during surgery was significantly lower in the study group (C=5788.90 ± 2703.86 vs. L=3549.40 ± 631.00, p=0.03). Leucocytes count was significantly lower in the study group in the immediate postoperative period (L=13.16 ± 2.44 vs C=17.97 ± 5.01, p=0.02). There was no significant difference in both groups for anesthesia and surgery time, for VAS scores and for CRP and fibrinogen rates.

CONCLUSION

The use of IV lidocaine decreases opioid requirements during orthognathic complex surgery. It could also play an anti-inflammatory role in the immediate postoperative period.

Keywords: complex orthognathic surgery, lidocaine, pain, anesthesia,

Leucocytes



Values are presented as mean (SE) * $p < 0,05$ test T of Student

Anaesthetic and surgery data

characteristic	Lidocaine 2%	NaCl 0.9%	P
Anaesthesia time (min)	273.4±143.45	324.1±111.76	0,39
Surgical time (min)	196.1 ±-121.45	266.1 ± 101.19	0,17
Osteotomy time (min)	100.2±74.9	126.4±54.07	0,38
Propofol dose (mg)	1723.10+-363.66	2064.81±837.28	0,25
Remifentanil dose (µg)	3549.40± 631.00 *	5788.90±2703.86	0,03

Values are presented as mean +- SD * = $p < 0,05$ test T of Student

PP-096

Success and Efficiency of Pre-banded Plates on Maxillary Advancement after Le Fort 1 Osteotomy: A Case Report

Bahadır Kan¹, Fatih Mehmet Coskunes¹, Hilal Kan²

¹Kocaeli University Faculty of Dentistry Department of Oral and Maxillofacial Surgery

²Private Practitioner

OBJECTIVE

The use of rigid fixation of bony segments in orthognathic survey has become the gold standard of postoperative success. Advancements in surgical techniques and fixation systems (design and material) have significantly improved the stable outcomes of orthognathic surgery. The pre-banded plates has been developed for gaining time with eliminating plate forming and decreasing the plate number. The purpose of this poster presentation is to present the stability and efficiency of pre-banded plates on maxillary advancement after LeFort 1 osteotomy.

METHODS

A 25 years old female patient with maxillary retrusion operated for skeletal correction. Under general anaesthesia, she received Le Fort 1 osteotomy to correct the dentofacial deformity. Maxilla was advanced 10 mm and fixed with two pre banded plates.

RESULT

After the operation, the patient healed without any complication. It was significant that the operation time reduced. In her first year follow up, relapse was not observed.

CONCLUSION

Excellent postoperative stability and aesthetics are the main target that oral and maxillofacial surgeons aims to achieve on orthognathic surgery. The result of this case has shown that pre-banded plates used in maxillary advancement with Le Fort 1 operation will provide stable results with saving the operation time and increasing comfort of the surgeons.

Keywords: Maxillary Advancement, Le Fort 1, Pre-banded plates, Fixation, Orthognathic Surgery, Maxilla

PP-097

Evaluation of Nasal Changes Following Surgically Assisted Rapid Palatal Expansion (SARPE)

Gökhan Gürler¹, Nevin Kaptan Akar², Çağrı Delilbaşı¹, Gühan Dergin³, İpek Necla Gültekin¹, Serdar Yılmaz¹

¹İstanbul Medipol University School of Dentistry Department of Oral and Maxillofacial Surgery

²İstanbul Medipol University School of Dentistry Department of Orthodontics

³Marmara University School of Dentistry Department of Oral and Maxillofacial Surgery

OBJECTIVE

The aim of this study was to evaluate the nasal changes following surgically assisted rapid palatal expansion (SARPE) in patients with maxillary transverse deficiency.

METHODS

14 patients (5 males and 9 females, age range 17 to 29 years) who were suffering from maxillary transverse deficiency were included in the study. SARPE was performed under general anesthesia via Le Fort 1 osteotomy without a down fracture. Preoperative and postoperative cone beam computed tomography (CBCT) scans were taken to measure nasal cavity width, maxillary width and nasal septum angle.

RESULTS

Nasal cavity width and maxillary width increased but there was a not a significant change in nasal septum angle.

CONCLUSION

Expansion in nasal dimensions following SARPE may decrease nasal resistance. Future data will be helpful to understand the nature of change in nasal dimensions and respiratory function.

Keywords: maxillary deficiency, SARPE, palatal expansion

PP-098

Posterior Segmental Osteotomy of the Maxilla

Esma Coşkun, Meriç Bilgiç, Selen Adiloğlu, Anıl Öztürk, Hakan H. Tüz

Department of Oral Surgery, Hacettepe University, Ankara, Turkey

Hemangioma is a benign and usually self involuting tumor (swelling or growth) of the endothelial cells that line blood vessels, and is characterised by increased number of normal or abnormal vessels filled with blood. Hemangioma is one of the most common soft tissue tumours of infancy, seen as a mucosal hemangioma mostly in the gingival, lip, tongue and buccal mucosa. They are more common in females than males (3:1).

Excessively inferior positioned posterior maxilla causes reduction of interarch space and prevents adequate restoration in the posterior quadrant. Posterior maxillary osteotomy is usually indicated as a preprosthetic procedure to correct hypereruption of a posterior maxillary dentoalveolar segment and narrow interarch space. Another treatment options are periodontal crown lengthening with endodontic treatment of the maxillary teeth and extraction of the supraerupted teeth and bone recontouring. Crown lengthening has some limitations like resulting short clinical crowns and compromise of the osseous support. The most radical treatment option is to extract the extruded teeth to gain posterior interarch space. For patients, teeth extraction is an unacceptable option. In this case, it is presented that 20 years old female patient who has hemangioma on the buccal side, was treated with posterior maxillary segmental osteotomy for excessively inferior positioned maxilla and her prosthetic treatments.

Keywords: Posterior maxillary segmental osteotomy, excessively inferior positioned maxilla, hemangioma

PP-099

Surgical Treatment of Severe Gummy Smile Case Report

Nasuh Kolsuz, Elif Merve Özcan, Altan Varol, Selçuk Basa

Department of Oral and Maxillofacial Surgery, Marmara University, Istanbul, Turkey

Excessive vertical maxillary growth causes excessive display of maxillary teeth and gingival tissue, despite of a sufficient upper lip length. Several treatment modalities were described for treatment of malocclusion with vertical maxillary excess and gummy smile. Early orthodontic treatment with vertical control may decrease the malocclusion and improve the appearance. Although, in most cases, orthognathic surgery is the optimal solution. However, in the case of extensive superior repositioning of the maxilla by a single LeFort I osteotomy is sometimes technically challenging for high impactions because of the anatomical restrictions around the descending palatine artery and anterior maxilla. Technical difficulties may be encountered especially in cases with little or no advancement.

The following case report describes a 27 year old otherwise healthy female patient displaying a severe gummy smile treated with an exceptional amount of maxillary impaction. A LeFort I osteotomy was performed for total 12 mm superior repositioning of the maxilla with no anterior advancement; then, bilateral sagittal split ramus osteotomy (BSSO) is rendered for mandibular correction. After the first post - operative year, both the occlusion and facial appearance were observed satisfactory without any incidence of relapse.

Keywords: Gummy smile, Orthognathic surgery, Le Fort 1 Osteotomy

PP-100

Surgical Treatment of a Mandibular Condyle Fracture - Case Report

Taha Özer, Mobin Nesiri, Özgür Başlarlı, Murat Akkocaoğlu, Aylin Ekmekcioğlu
Department of Oral Surgery, Hacettepe University, Ankara, Turkey

The condyle is one of the most common sites of mandibular fractures ranging up to 49% in the literature. The fractured condyle head is usually displaced forward and medially by the lateral pterygoid muscle, while the muscle of mastication tend to draw the ascending ramus up and back to produce an open bite with rotation of the symphysis towards the affected side. Condylar fractures can be extracapsular or intracapsular, undisplaced, deviated, displaced, or dislocated. Treatment depends on the age of the patient, the co-existence of other mandibular or maxillary fractures, whether the condylar fracture is unilateral or bilateral, the level and displacement of the fracture, the state of dentition and dental occlusion. Treatment of mandibular condyle fractures is still controversial. Historically, maxillomandibular fixation, external fixation, and surgical splints with internal fixation systems were the techniques commonly used in the treatment of the fractured mandible. But in these days, surgical treatment is slowly becoming the preferred option. An appropriate treatment is required to reconstruct the shape and function of uninjured status. To do this; accurate diagnosis, appropriate reduction and rigid fixation, complication prevention are required. As mandibular condyle fractures may cause long term complications such as mandibular growth and functional disorders, chronic temporomandibular joint (TMJ) complications, a more caution should be given.

In this presentation, a surgical treatment of an 11-years-old patient's condyle fracture is described.

Keywords: condyle fracture, surgical treatment, tmj

PP-101

The Evaluation of Relationship Between Post Traumatic Stress Syndrome and Temporomandibular Joint Disorders

Cennet Neslihan Eroglu¹, Serap Keskin Tunc¹, Sadi Elasan²

¹Department of Oral and Maxillofacial Surgery, Yuzuncu Yil University, Van, Turkey

²Department of Biostatistics, Yuzuncu Yil University, Van, Turkey

OBJECTIVE

Stress plays a major role as pathogenetic factors in temporomandibular joint disorders. Causes of stress are mostly psychologically traumatic event (major disasters, accidents, depression etc.). Natural disasters such as earthquakes affect people negatively. This affects the physical injuries, cognitive dysfunction, lose loved ones, property loss and damage, and may lead to emotional

5-8 November 2014 - Harbiye Military Museum & Cultural Center - İstanbul / Turkey

dysregulation. In this study, PTSS (Post Traumatic Stress Syndrome) and evaluated the association between joint complaints.

METHODS

Only the patients complaining for Temporomandibular Joint Disorder (TMD) being included to the survey. The project has been done within 3 divided forms. The first two forms are named as TMR Searching Diagnose Criteria (RDC/TMD Research Diagnostic Criteria for Temporomandibular Disorders) index. The main aim of RDC/TMD is providing standardized criteria for TMR under the current information. It is divided in two sections: 1st section (Examine Form) includes the criteria to diagnose the disorders in masticatory muscles and in TMJ. 2nd section (Anamnesis Form) includes criteria for level of pain, inability from pain, assessment of pain and psychosocial conditions/status such as depression and somatisation. The 3rd form composed of Post-Traumatic Stress Disorder (PTSD) test.

RESULTS

In this project we worked on 62 patients which 31 of the patients experienced the earthquake in Van in October 2011, 31 of them did not. Number of women patients were 33 men 29. The average of the age of the patients was 22.76. In the study: in terms of continuous parameters, while comparing the groups' averages one way ANOVA and Mann-Whitney U test applied. Defining the relation in between those groups separately the Pearson correlation coefficients are calculated and for assesment of the relationship between groups and Categorical parameters the Ki-Kare test is applied.

CONCLUSIONS

The patients experienced the earthquake and had complaints temporomandibular joint pain and patients did not experienced the earthquake and had the same complaints temporomandibular joint pain have been compared and evaluated. According to statistical analysis the relation between posttraumatic stress syndrome and TME disorders has been discussed.

Keywords: post traumatic stress syndrome, temporomandibular joint disorder

PP-102

Evaluation of The Effects of Different Treatment Modalities of Temporomandibular Disorders to Psychological Status and Chronic Pain Degrees

Hatice Duran¹, Burcu Baş², Esengül Bekar²

¹Department of Oral and Maxillofacial Surgery, Gazi Osman Paşa University, Tokat, Turkey

²Department of Oral and Maxillofacial Surgery, Ondokuz Mayıs University, Samsun, Turkey

OBJECTIVE

The purpose of this study is to evaluate the effects of four different treatments to psychological status and chronic pain degrees of patients assessed by the Research Diagnostic Criteria for Temporomandibular Disorders (RDC/TMDs) Axis II.

METHODS

40 patients with unilateral painful TMD which fall into Group II according to RDC/TMD underwent the treatment protocol and a follow-up assessment at 6 months. Patients were divided into 4 groups according to the treatment method. Group 1. Splint therapy, Group 2. Arthrocentesis therapy, Group 3. Medical therapy and Group 4. Low level laser therapy (LLLT). RDC/TMD's Axis I and II forms were used before treatment and after treatment at the 1st, 3rd and 6th months.

RESULTS

The psychological status of patients in all treatment groups were observed to be significantly changed better at 1 month after treatment. All follow-up evaluations of psychological status of patients treated with splint therapy and LLLT were better than other treatment methods. While the values of chronic pain degrees decreased at 3rd and 6th months after treatment compared to baseline in group 1 and 2, the values of chronic pain degrees showed statistically significant decrease all follow up time in group 3 and 4.

CONCLUSIONS

The psychological status of patients which is one of the etiologic factor in TMD is an important factor and it is thought to be occurred by multifactorial mechanism.

Keywords: RDC/TMD, Axis II, Arthrocentesis; low level laser therapy; medical therapy; splint therapy

PP-103

Using the Gap Arthroplasty to Treat Temporomandibular Joint Ankylosis with Costochondral Graft

Timuçin Baykul¹, M.asım Aydın², Yavuz Fındık¹

¹Oral and Maxillofacial Surgery Department, Faculty of Dentistry, Süleyman Demirel University, Isparta, Turkey

²Plastic and Reconstructive Surgery Department, Faculty of Medicine, Süleyman Demirel University, Isparta, Turkey

Temporomandibular joint (TMJ) ankylosis is a disorder that leads to a restriction of the mouth opening from partial reduction to complete immobility of the jaw. Several interpositional grafts have been used for the treatment of temporomandibular joint ankylosis such as indigenous pterygomasseteric sling, temporalis muscle/fascia, auricular cartilage, fat, costochondral graft and dermis-fat. A 35-year-old man with history of right temporomandibular joint trauma and no mouth opening after an accident was referred to our oral and maxillofacial department. Under general anesthesia a right preauricular approach was achieved and gap arthroplasty was performed by excision of the ankylosed mass beginning from the condylar neck, coronoid process and getting a final gap of 15 mm between ramus and skull base and costochondral graft was used as a graft material. The articular reconstruction with costochondral grafts with gap arthroplasty for the treatment of ankylosis is shown to be efficient in relation to the post-operative maximal incisal opening, recurrence and articular function.

Keywords: Tmj, gap arthroplasty, costochondral graft

PP-104

An Audit of Antibiotic Prescribing Policy for Mandible Fractures

Srikrishna Vempaty, Gurmandeep Sond, Tun Wildan, Mo Shorafa
Regional Maxillofacial Centre, North West London Hospitals Trust, Watford Road, Harrow, UK HA1 3UJ

OBJECTIVE

Antibiotics are prescribed prophylactically during open reduction and internal fixation (ORIF) of mandible fractures to reduce the incidence of surgical site infection. Antibiotic prescribing needs to be done in an appropriate manner to minimise the adverse effects of antibiotics and also to reduce the incidence of resistant organisms such as methicillin-resistant *Staphylococcus aureus* (MRSA). An audit was performed to determine adherence to the Scottish Intercollegiate Guidelines Network (SIGN) on antibiotic prophylaxis in surgery which provided evidence based recommendations that suggests not giving more than 24 hours of antibiotic prophylaxis in ORIF of mandible fractures.

METHODS

Data of cases of ORIF of mandible fractures were collected between January 2014 and August 2014 in a major UK district general hospital. The data recorded included number of cases of ORIF mandible fractures, patients' demographic, length of stay in hospital and also antibiotic prescribing pattern.

RESULTS

104 cases of ORIF mandible fractures were observed and 94 (90%) of these cases were males and 10 (10%) were females. The length of hospital stay ranged from 1 to 5 days with 2 days being the mode of the length of stay. 99 (95%) patients were given antibiotics on discharge from the hospital with only 8 having an indication for this e.g. immunocompromised patient, presence of active infection at surgical site.

CONCLUSIONS

There seems to be a tendency of over-prescribing of prophylactic antibiotics in our unit in the treatment of mandibular fractures. This is non-compliance with the SIGN guideline which suggests only 24 hours of prophylactic antibiotics for ORIF of mandible fractures. Prolonged administration of antibiotics not only increases health costs but also the prevalence of antibiotic-resistant bacteria and can also cause antibiotic-associated colitis from growth of *Clostridium difficile*.

Antibiotic prophylaxis should only be given when there is evidence of its benefits. The *raison d'être* of antibiotic prophylaxis is to reduce the prevalence of surgical site infection although this should not be a substitute for good surgical aseptic technique. We have therefore changed the practice of prophylactic antibiotic prescribing in our unit for ORIF of mandible fractures to a 24 hour

prophylactic regime and collecting evidence whether this has increased the incidence of surgical site infection from this protocol.

Keywords: antibiotic prophylaxis, mandible fractures

PP-105

Conservative Treatment of Mandibular Condylar Fractures in Children

Gökhan Gürlü, Tuba Develi, Barış Çağrı Delilbaşı, İlker Burgaz, Şükran Tüfekçioğlu
Department of Oral and Maxillofacial Surgery, Istanbul Medipol University, Istanbul, Turkey

Mandibular condylar fractures in children are one of the most common injuries of the maxillofacial skeleton. These injuries might effect patient's growth particularly, if open reduction is the treatment of choice. The aim of this case presentation is to report conservative treatment of mandibular condylar fractures in three children. Two patients had symphyseal fracture associated with bilateral condylar fractures. Intermaxillary fixation with four orthodontic mini screws was performed in one child, whereas no interventional treatment was performed in other two children for condylar fractures.

As very well known by clinicians, conservative procedures for condylar fractures have successful outcomes in growing individuals.

Keywords: Trauma, Mandibular condylar fracture, Conservative treatment

PP-106

Management of Pediatric Facial Trauma; Bilateral Condyle & Symphysis Fractures

Onur Koç, Salih Eren Meral, Serkan Kiriş, Murat Akkocaoğlu
Department of Oral and Maxillofacial Surgery, Hacettepe University, Ankara, Turkey

Management of trauma has always been one of the surgical subsets in which oral and maxillofacial surgeons have excelled over years. Due to its position and prominence, mandible is the second most commonly fractured part of the maxillofacial skeleton. About 11-16% of all facial fractures and 30-40% of all mandibular fractures are of condyle.

In children, about 16% of all facial fractures and 40% of all mandibular fractures are fractures of condyle. Because of this, mandibular condylar fractures are an important part of the pediatric facial traumatology. Mandibular fractures in children differ greatly from adults. Managing mandibular condylar fractures in children continues to be a subject of debate because of the possibility of growth alterations caused by trauma/fractures or surgery.

5-8 November 2014 - Harbiye Military Museum & Cultural Center - İstanbul / Turkey

Because of the greater elasticity of the bones, even mandibular fractures are rare in children under 5 years of age. A 2-year-old girl referred to Hacettepe University, Faculty of Dentistry, Department of Oral and Maxillofacial Surgery with a history of a traumatic fall (approximately 10 metres) three weeks prior to admittance. After the intraoral and radiologic evaluations bilateral condylar fractures and non-displaced symphysis fracture were observed.

Right condyle was minimally dislocated and no surgical intervention was applied. However, the left condyle was bodily dislocated towards the medial part of the intra articular fossa. The applied surgical procedure was; (1) to associate the condyle to the ramus of the mandible in order to maintain appropriate structural integrity, (2) to fix the condyle to the ramus with a microplate and three monocortical micro screws. After three days of hospitalization, the patient was discharged. Control appointments were scheduled for the following week of the patient's discharge and monthly in the coming year.

Keywords: Pediatric trauma, Condyle fracture, Open reduction, Internal fixation.

PP-107

Alternative Diagnosis for Radio-Opacity Observed on Two-Dimensional Imaging

Marzyeh Parvizi, Natasha Talai

Department of Oral and Maxillofacial surgery, University Hospitals Bristol, Bristol, UK

OBJECTIVES

We introduce a case of a 52-year-old male, who presents with an incidental radio-opacity on his routine periapical radiograph following a referral by his general dental practitioner. The periapical radiograph showed a well-circumscribed oval radio-opacity superimposing his upper left wisdom tooth, which resembled an occluso-cervical restoration. Intraoral examination revealed UL8 was unrestored and vital. All other teeth in the upper left quadrant also appeared vital. All intra oral soft tissues and muscles of mastication appeared normal. The objective of this study was to determine alternative diagnosis for the presentation of radio-opacity observed on 2D radiographic imaging.

METHODS

A thorough investigation included intraoral and extra oral examination, OPG and Cone Beam CT (CBCT) scan.

RESULTS

The OPG report revealed similar findings to the to periapical radiograph. The Cone Beam CT scan confirmed the presence of an airgun pellet lying at the anterior border of masseter muscle, about 15mm anterior to the mandibular ramus.

CONCLUSIONS

This case demonstrates the significance of seeking alternative diagnosis with three-dimensional

imaging in cases of discrepancy between clinical and radiographic findings. In particular, the three-dimensional information on the maxillofacial region gained from a Cone Beam CT scan confirmed the presence of an airgun pellet in the region. The patient did not recall an airgun injury incident, which is in line with the literature suggesting that patients can be unaware of being shot as the entry wound is often very small. Given that the pellet had been present for some time, asymptomatic, and not associated with any pathology, it was decided that no further intervention was required. Cone beam CT (CBCT) produces accurate three-dimensional information on the maxillofacial region. It has many advantages over conventional CT scanning, including reduced radiation dose, higher image accuracy, and a rapid scan time of approx 10-70 seconds.

Keywords: Cone Beam CT, Airgun Pellet, radio-opacity

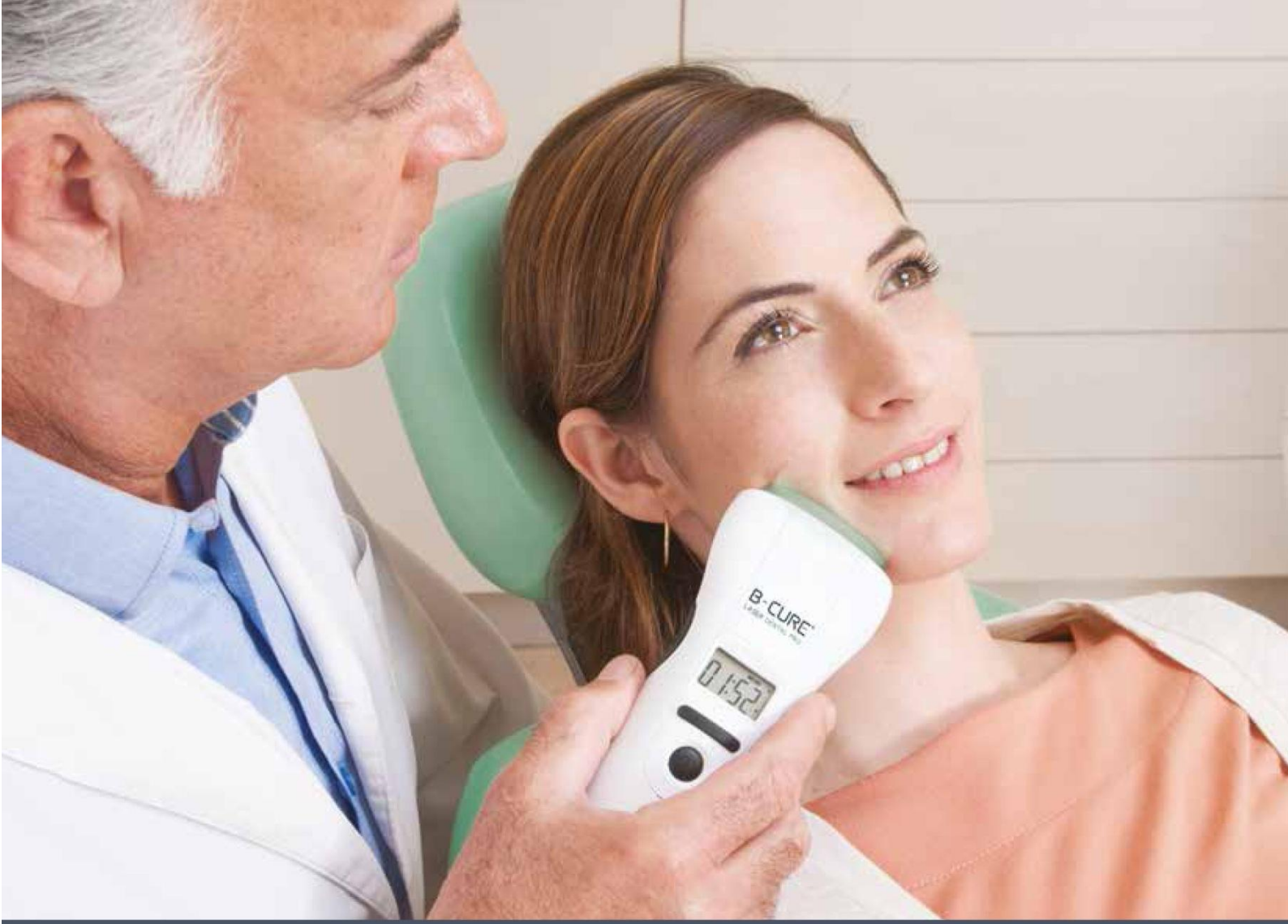Dental Tribune International

The World's Largest News and Educational Network in Dentistry

dti] Dental Tribune International

www.dental-tribune.com





B-CURE®
LASER DENTAL PRO

Diş Hekimlerine Özel

Güçlü ve Etkili Bir Rahatlama için Soft Lazer



Hızlı ağrı kesici etki
ve hızlı iyileşme



Terapi alanı



Artırılmış
lazer emilimi

max **250** mW
808 nM

**G
e**

GOOD
ENERGIES®

www.laserdentalpro.com

for good health



AÇBİD-BAOMS JOINT CONGRESS

in conjunction with



4th Conference of BAMFS
(Balkan Association of Maxillofacial Surgeons)

5-8 November 2014
Harbiye Military Museum & Cultural Center
İstanbul / Turkey

Oral and Maxillofacial Surgery Society, Turkey (AÇBİD)
British Association of Oral and Maxillofacial Surgeons (BAOMS)

www.acbid-baoms2014.org

Professional Congress Services

interium

Professional Congress Services • Destination & Event Management
Corporate Meetings & Incentives • PR & Communication Consultancy

+90 212 292 8808 • +90 212 292 8807
info@interium.com.tr • www.interium.com.tr



EACMFS Accredited



Scan this QR
Code with your
smart phone to
download the web site.